

# Disclaimer

- The copy in this file is protected by copyright of the author or authors. Consent was provided for the express purpose of educating attendees of the 2015 Registrars' Conference in Perth.
- You **MAY NOT COPY OR DISTRIBUTE** the contents or images in any form.
- You **MAY PRINT** the document for your own personal use as an educational resource

# ABDOMINOPLASTY

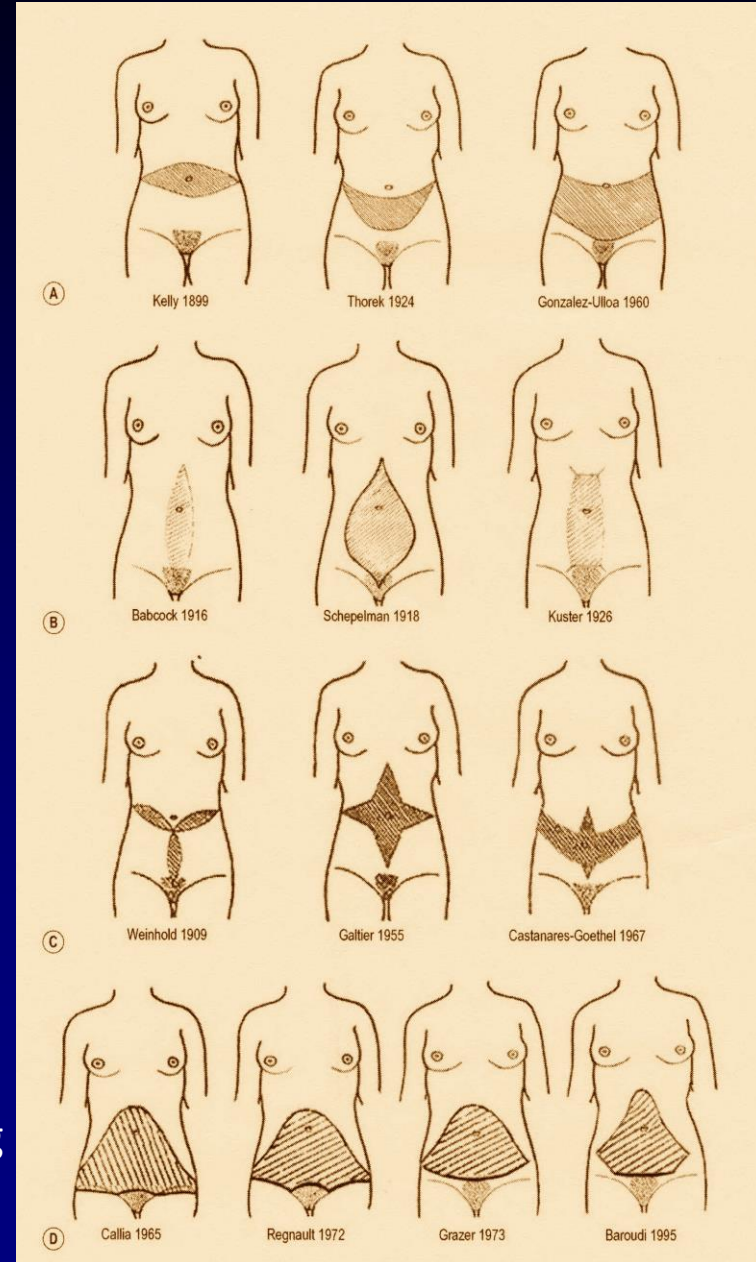
Chris Allen

March 2015

# ABDOMINOPLASTY

## HISTORY

- 1899 Kelly mid abd
- 1916 Babcock vertical abdominoplasty
- 1924 Thorak lower transverse a'plasty
- 1957 Vernon umbilical transposition & plication
- 1967 Pitanguy 300 a'plasties
- 1972 Regnault W technique
- 1973 Grazier bikini line incision
- 1980's French line bikini high cut lat & low centrally
- 1988 Matassaro + lipo to a'plasty
- 1990's Less undermining
- 1997 Lockwood high lat tension a'plasty
- 2000's v. low waistlines & tailor made a'plasties
- 2001 Salanha lipo& a'plasties without undermining



# ABDOMEN

## Anatomy

7 layers:

Skin

S/C Fat

Scarpa's fascia

Sub-Scarpa's fat

Ant Rectus Sheath

Rectus muscle

Post Rectus sheath



# UMBILICUS

- Aesthetically pleasing:

superior hooding

inferior retraction

round or ellipsoid shape

shallow

# UMBILICUS

## Blood supply

subdermal plexus

DIEA [ L & R ]

Lig Teres

Median umbilical lig

# ABDOMINOPLASTY

## HISTORY

Main concern of patient

Number of pregnancies & children [?further children]

Previous abdo op's [incl CS ]

Previous hernias

Weight loss or gain

Exercise regime

Smoking

Blood thinner [incl aspirin & fish oil]

# ABDOMINOPLASTY

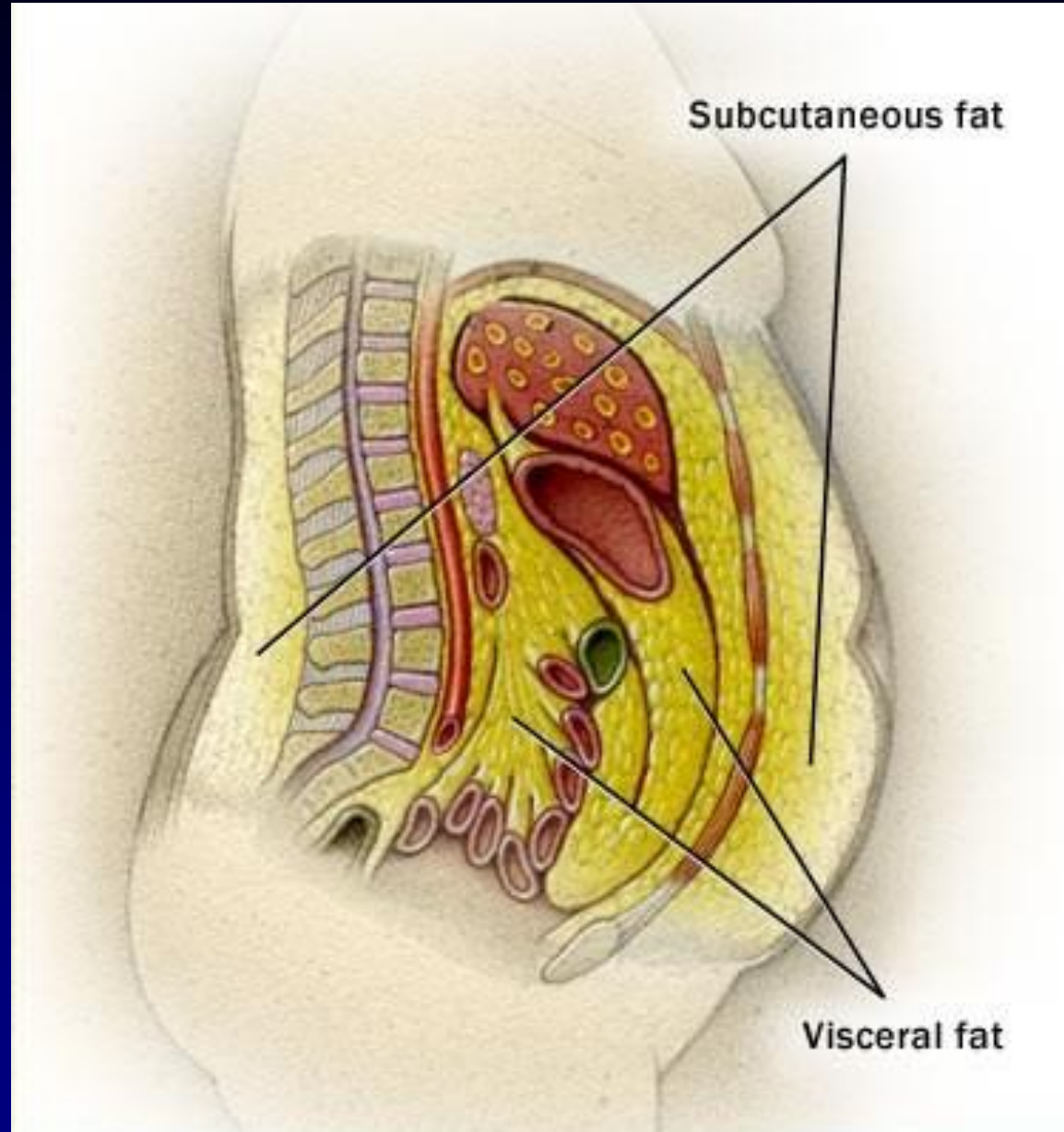
## EXAMINATION

Calculate BMI [ = weight / height squared ]

4 Positions:

lying ..... lift head  
sitting..... relax  
standing.....relax  
leaning forward.....dive position

# Visceral Fat



# ABDOMINOPLASTY

## EXAMINATION ]cont]

### Skin

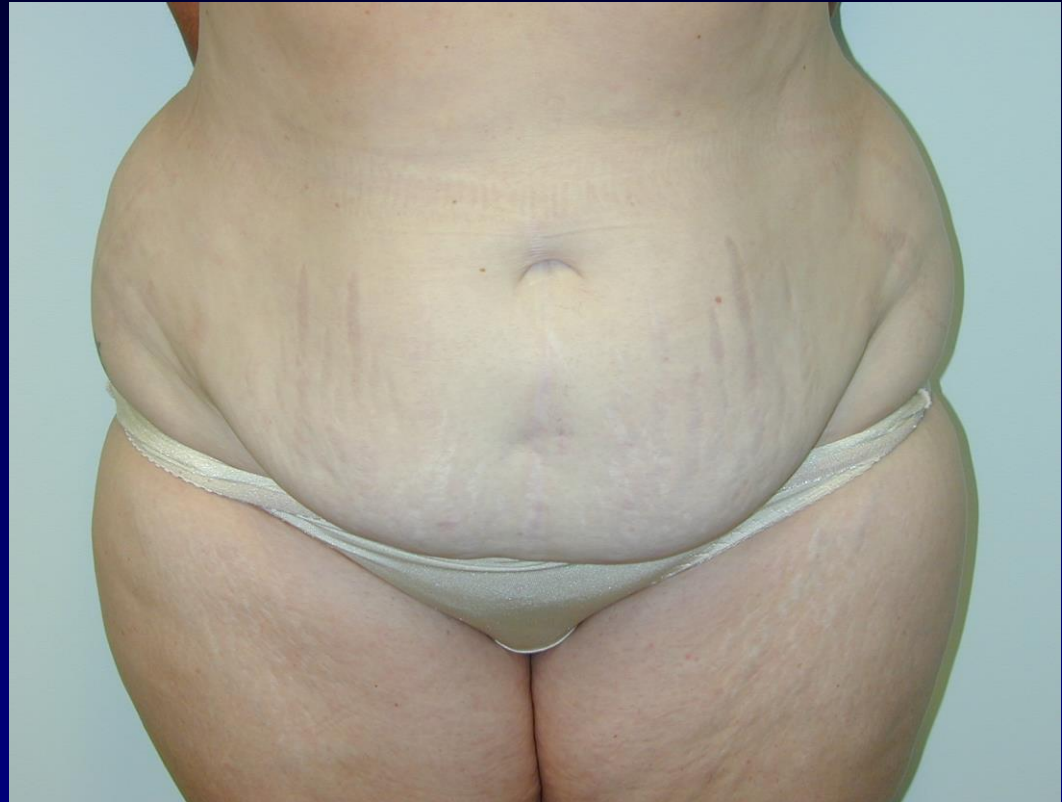striae,  
scars [esp subcostal],  
rashes/excoriations

### Fat

obesity [s/c & visceral],  
folds /rolls,  
adhesions/ tethering

### Musculo-fascial

midline diastasis,  
hernias [umb, incis, epig, inguinal]



# ABDOMINOPLASTY

## PROCEDURES

1. Liposuction only
2. " + diastasis repair
3. Subumbilical [mini] abdominoplasty
4. Standard [radical, traditional] abdominoplasty
5. Lipo Abdominoplasty
6. High lateral tension abdominoplasty [Lockwood]
7. Modified vertical abdominoplasty [fleur-de-lis]
8. Panniculectomy
9. Circumferential abdominoplasty [bodylift, belt lipectomy ]
10. Reverse [upper] abdominoplasty
11. Other [lipo to other areas, hernia repairs, scar revisions, abdo op's eg hysters, other op's eg thighs, breasts, face.]

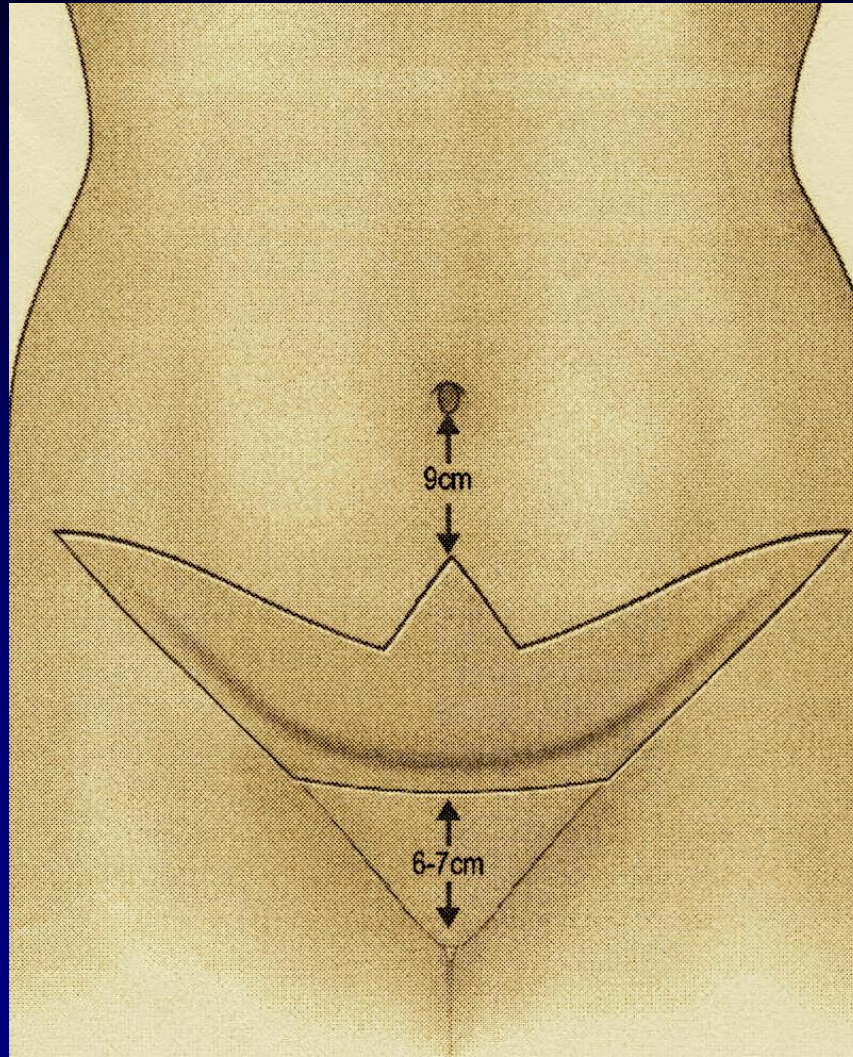
# ABDOMINOPLASTY

## PROCEDURES

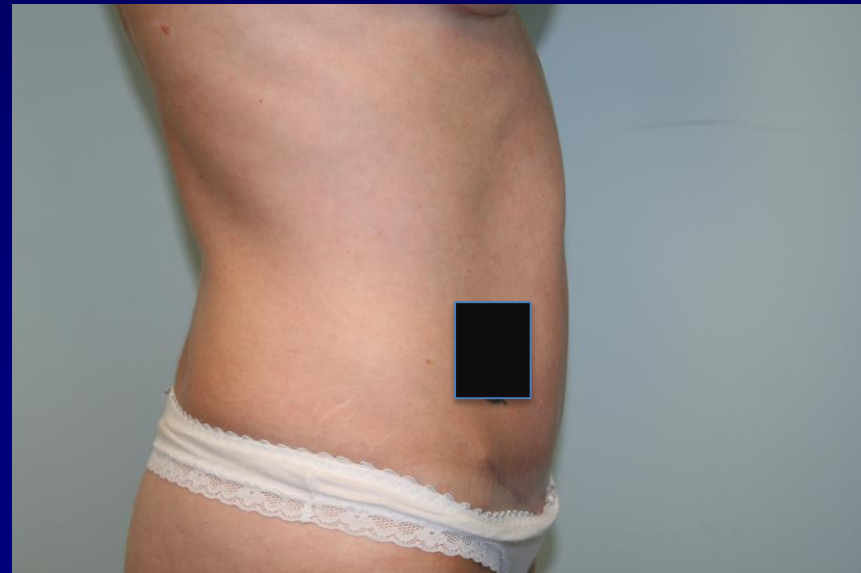
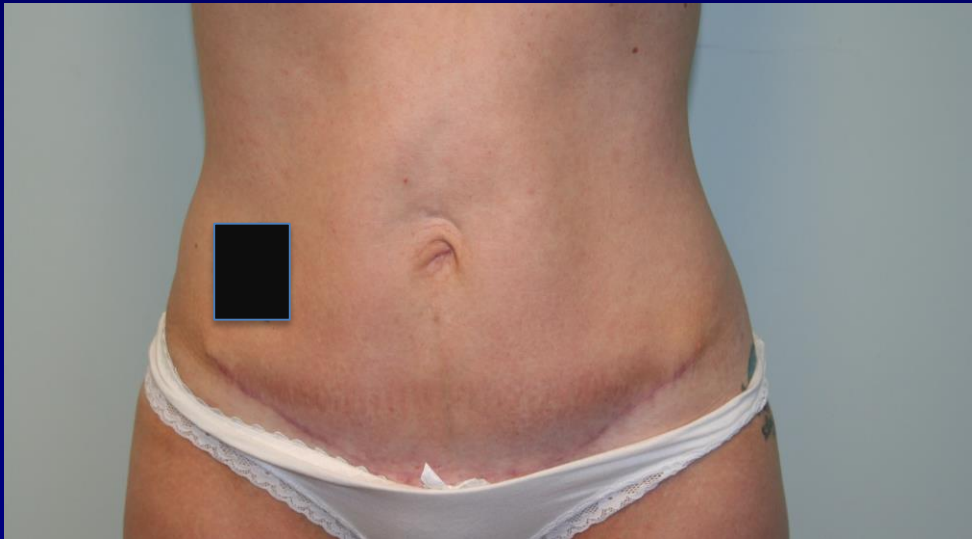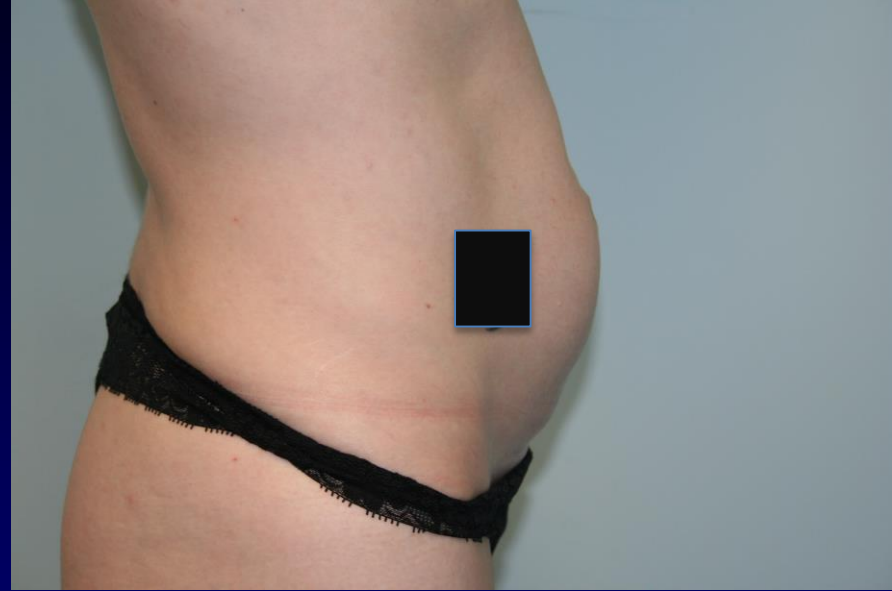
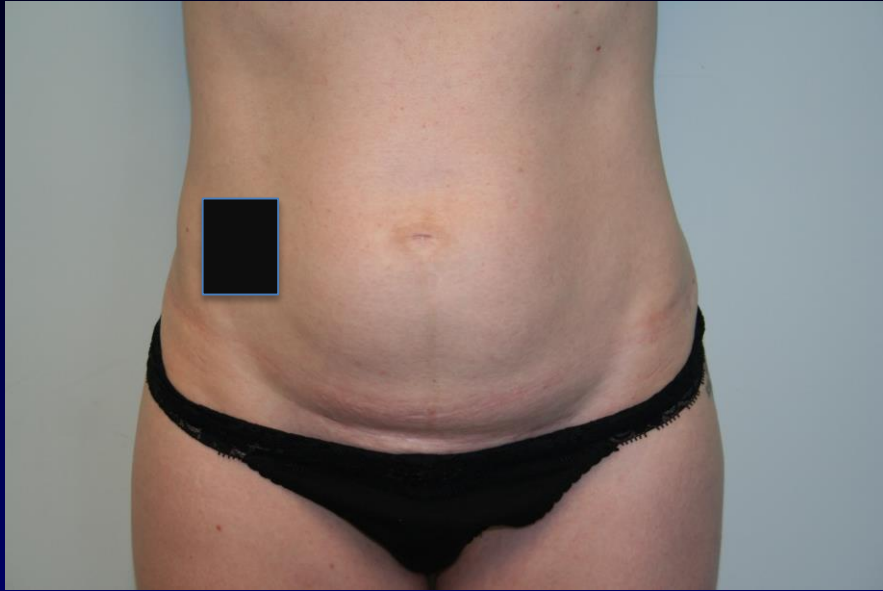
1. Liposuction only
2. " + diastasis repair
3. Subumbilical [mini] abdominoplasty
4. Standard [radical, traditional] abdominoplasty
5. Lipo Abdominoplasty
6. High lateral tension abdominoplasty [Lockwood]
7. Modified vertical abdominoplasty [fleur-de-lis]
8. Panniculectomy
9. Circumferential abdominoplasty [bodylift, belt lipectomy ]
10. Reverse [upper] abdominoplasty
11. Other [lipo to other areas, hernia repairs, scar revisions, abdo op's eg hysters, other op's eg thighs, breasts, face.]



# SUBUMBILICAL [ mini] ABDOMINOPLASTY

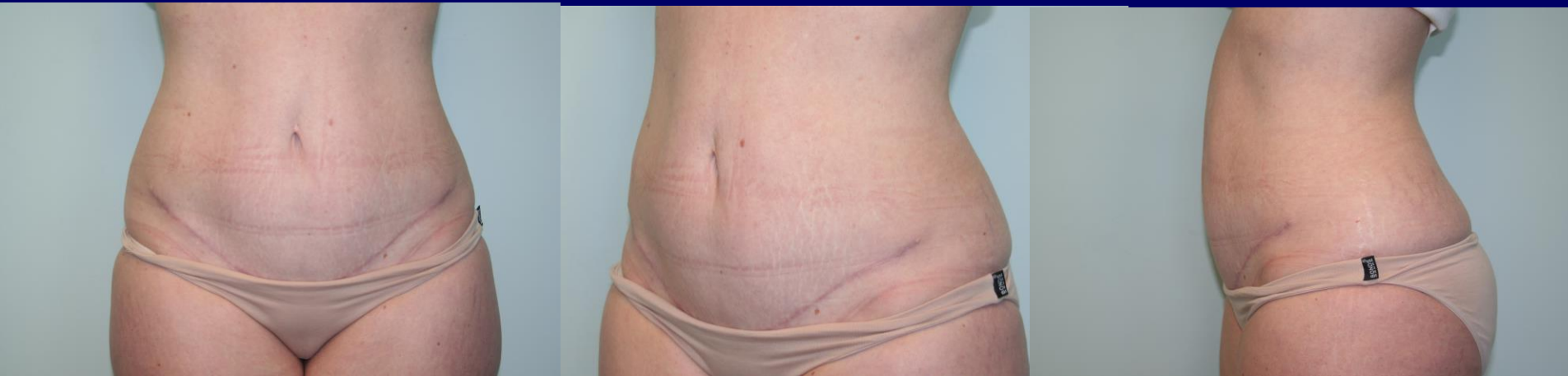
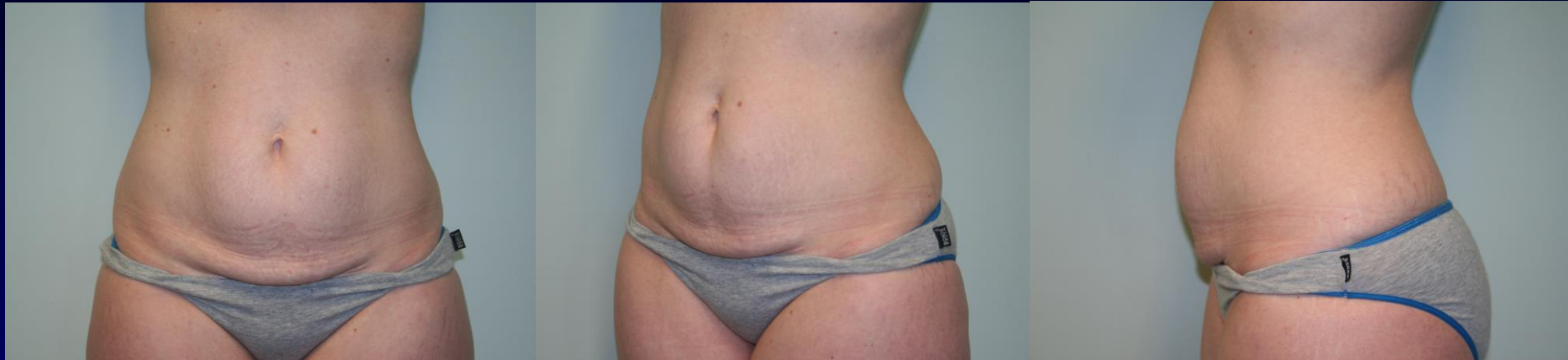
# SUBUMBILICAL ABDOMINOPLASTY & FULL DIASTASIS REPAIR





# SUBUMBILICAL ABDOMINOPLASTY



# ABDOMINOPLASTY

## PROCEDURES

1. Liposuction only
2. " + diastasis repair
3. Subumbilical [mini] abdominoplasty
4. Standard [radical, traditional] abdominoplasty
5. Lipo Abdominoplasty
6. High lateral tension abdominoplasty [Lockwood]
7. Modified vertical abdominoplasty [fleur-de-lis]
8. Panniculectomy
9. Circumferential abdominoplasty [bodylift, belt lipectomy ]
10. Reverse [upper] abdominoplasty
11. Other [lipo to other areas, hernia repairs, scar revisions, abdo op's eg hysters, other op's eg thighs, breasts, face.]

# STANDARD ABDOMINOPLASTY [Radical]

## Pre-op Markings

Standing

Mark pants/ bikini

Midline xiphi to vulva

[6.5-7.0 cm above vulval commissure]

Transverse suprapubic -- either:

low incision [? Below CS]

high “ [high pubic hair]

inverted -T [vert incision for umbi hole]

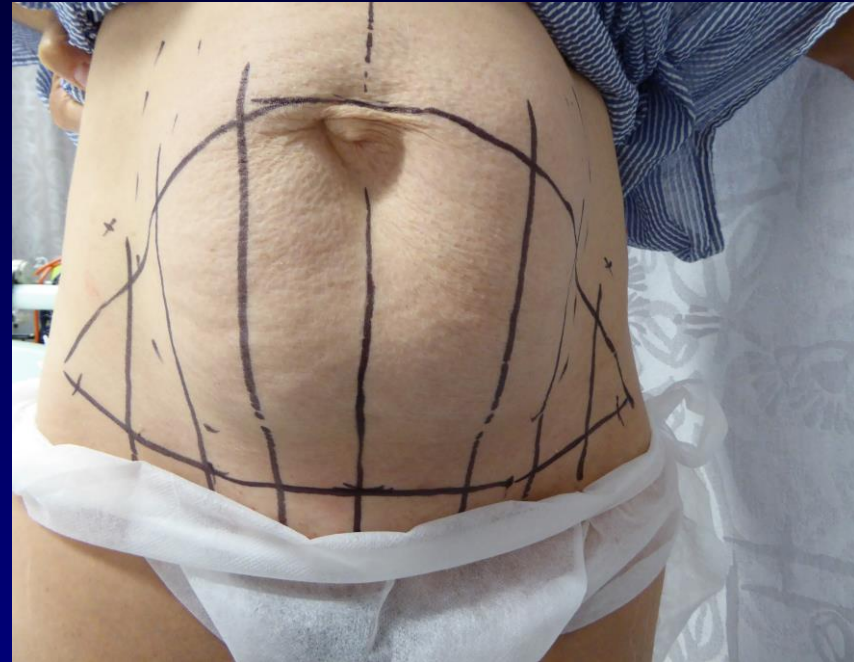Oblique towds ASIS in creases.

Pinch test flexing

Superior mark

just above umbi & down towds ASIS

Vertical orientation marks.



# ABDOMINOPLASTY

## Pre-Op in theatre

Test op table flexes & pillow under knees

Catheter

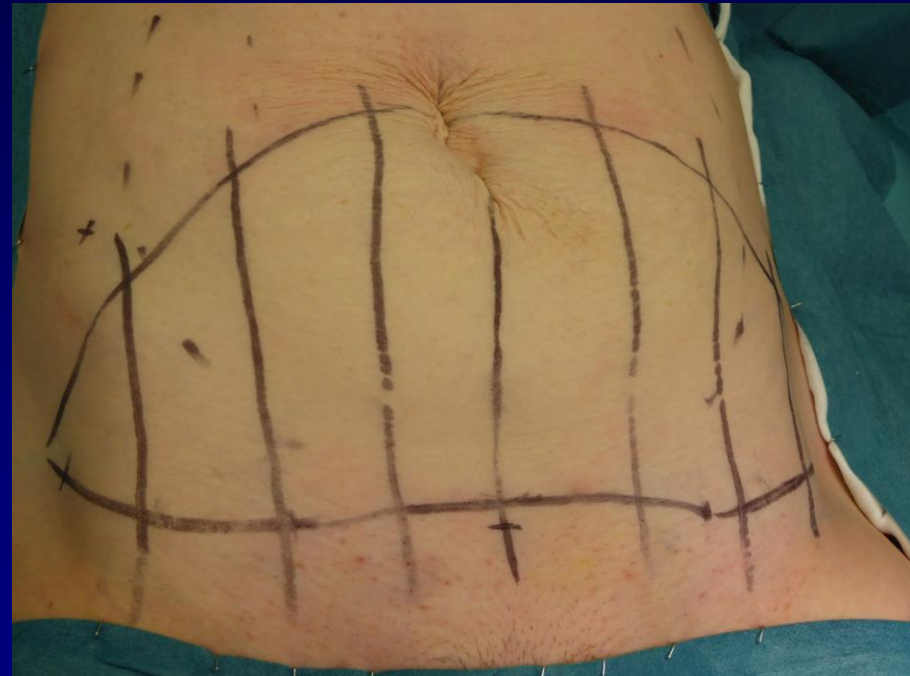Calf stimulators

Shave ½ pubic hair

IV Abs

Staple drapes

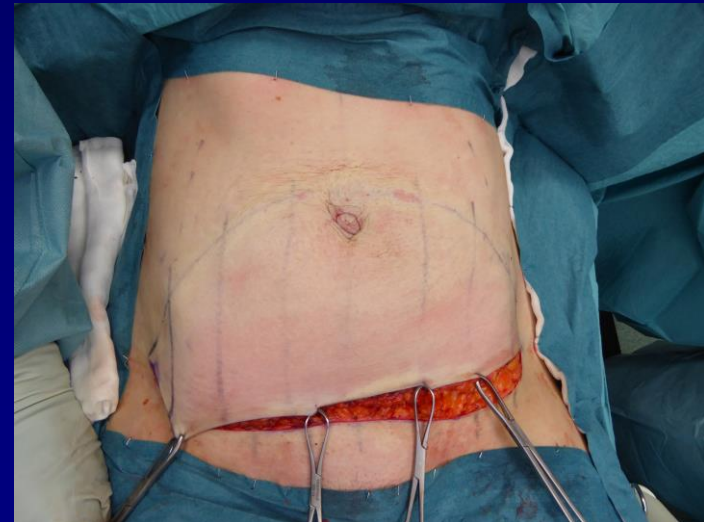
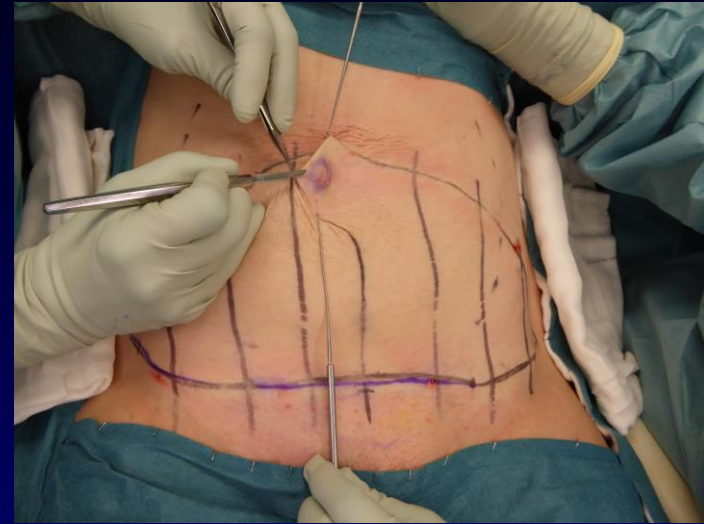
Prep umbilicus with cotton bud



# ABDOMINOPLASTY

## Technique

1. Lipo [ if indicated ]
2. Infiltrate incisions with marcaine/adren
3. Umbi incision, circle, short stalk, leave fat
4. Inferior incision
5. Scarpa's fascia.. Preserve to umbi
6. Haemostasis diathermy or ligaclips
7. ASIS preserve fascia to protect LCNT
8. Dissect umbi with cuff fat
9. Split abdo flap vertically to umbi

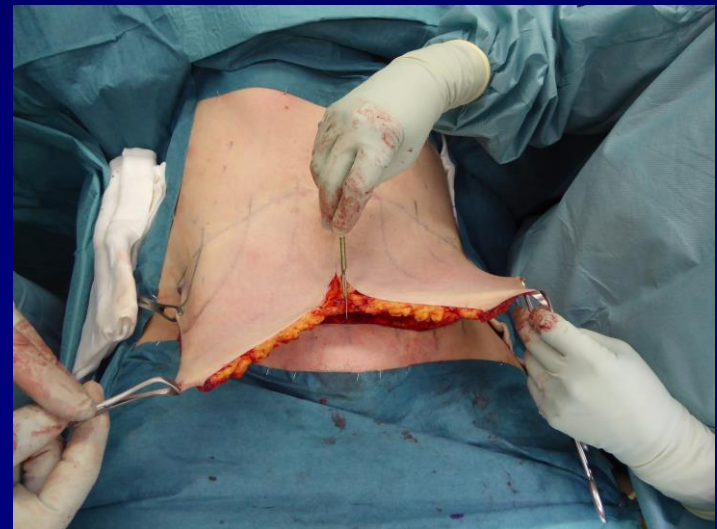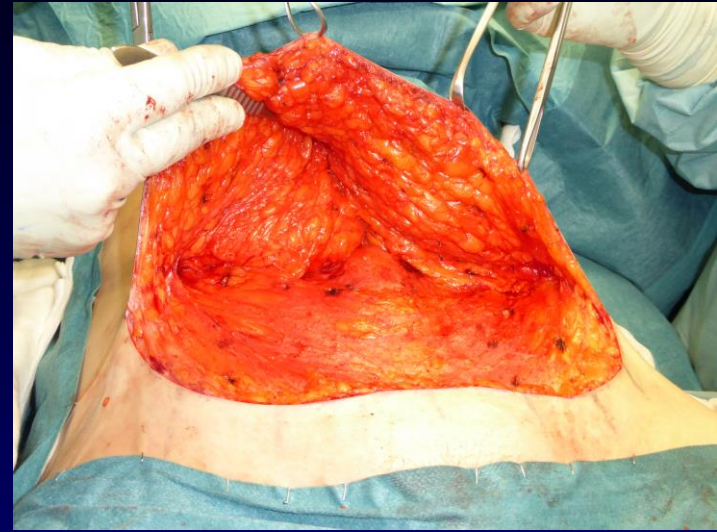




# ABDOMINOPLASTY

## Technique

1. Lipo [ if indicated ]
2. Infiltrate incisions with marcaine/adren
3. Umbi incision, circle, short stalk, leave fat
4. Inferior incision
5. Scarpa's fascia.. Preserve to umbi
6. Haemostasis diathermy or ligaclips
7. ASIS preserve fascia to protect LCNT
8. Dissect umbi with cuff fat
9. Split abdo flap vertically to umbi





# ABDOMINOPLASTY

## Technique [cont]

10. Selective undermining centrally

11. Plicate Rectus

paralyse, mark, suture[permanent]

12. +/- quilting suts

13. Irrigate wound

14. Flex op table

15. Mark & resect skin +/- thin fat

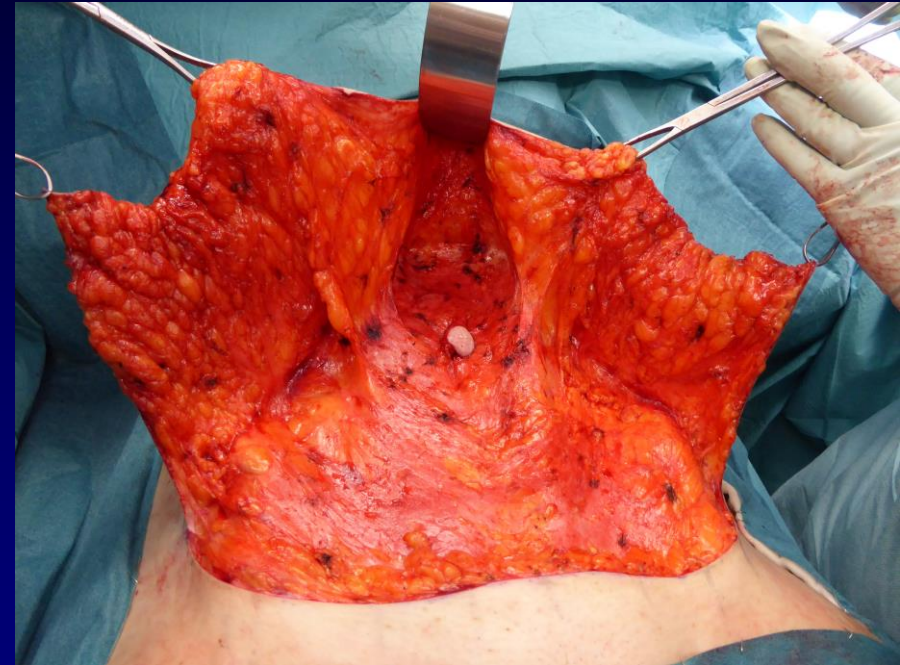
16. Drains

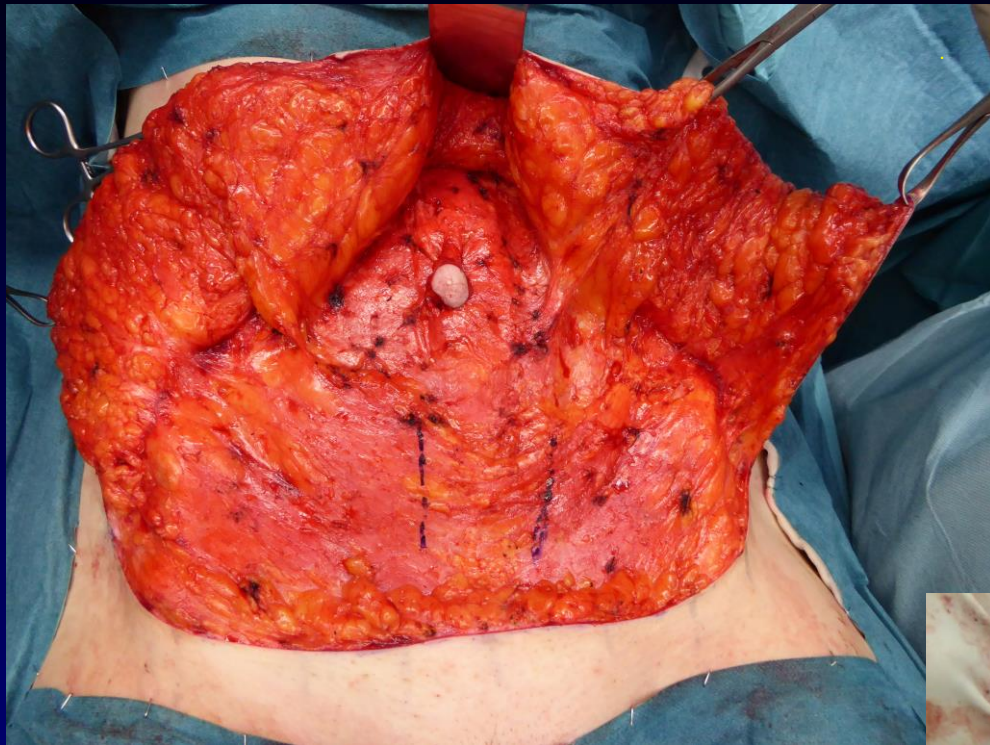
17. Suture midline

18. Mark umbi

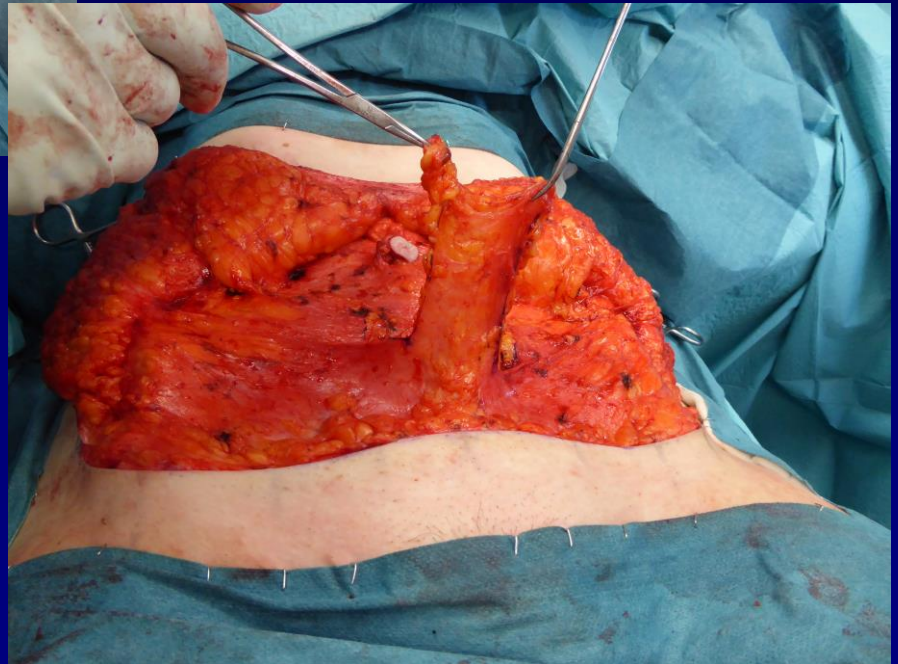
19. Close wounds 3 layers

20. umbilicoplasty

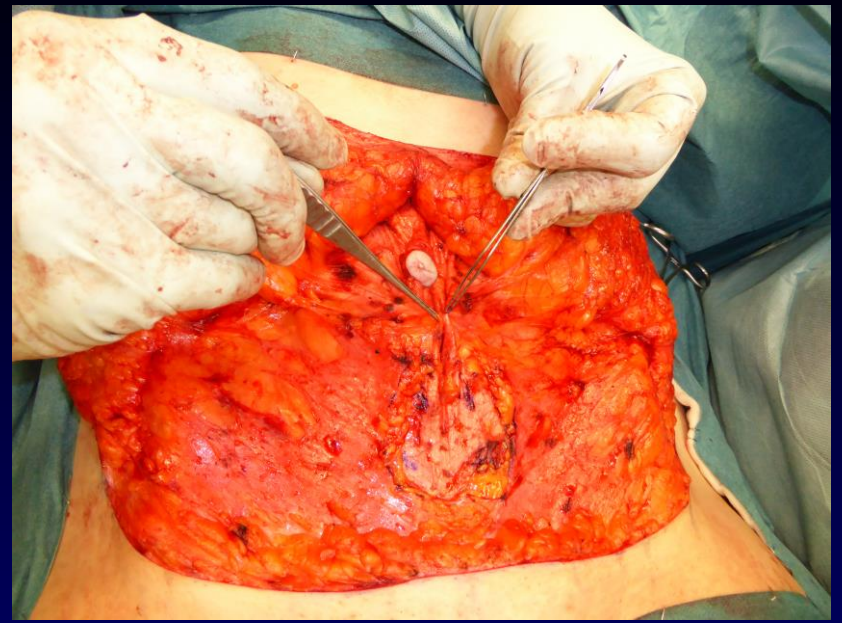
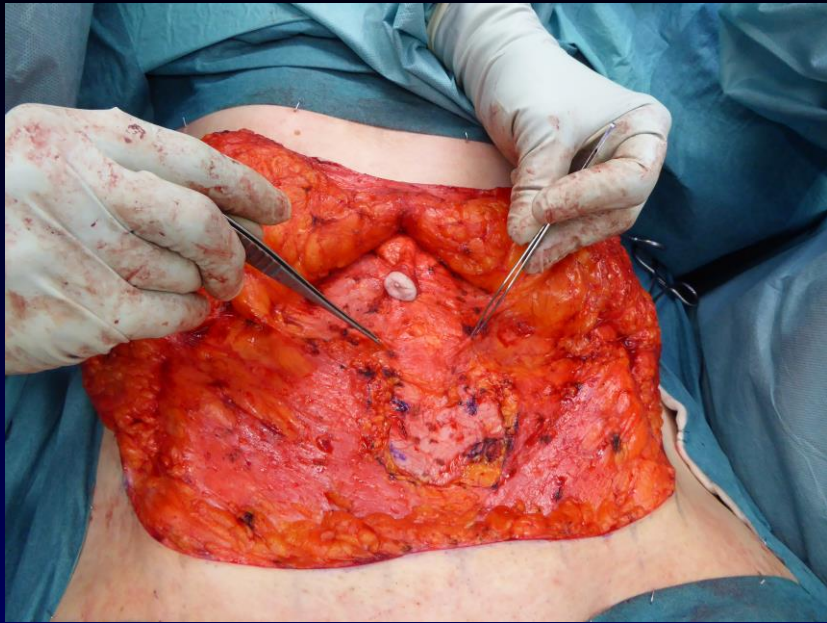



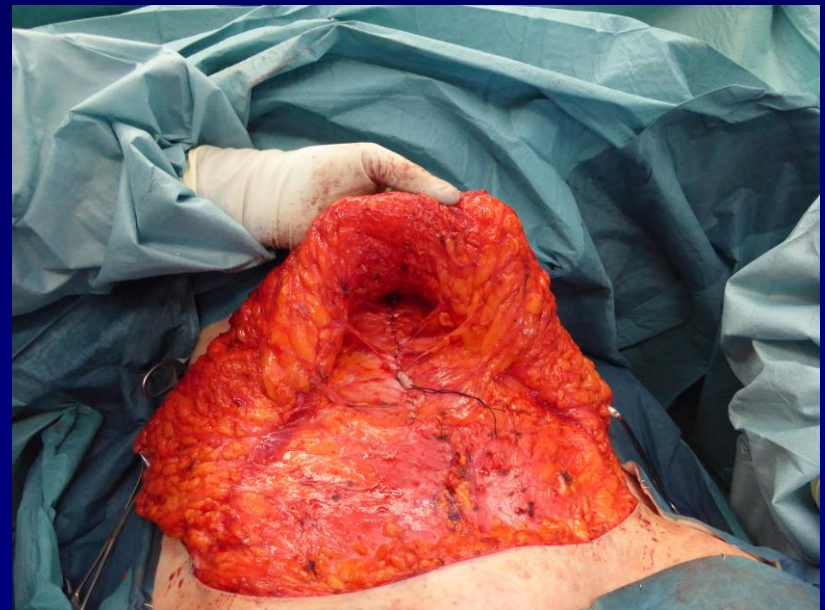
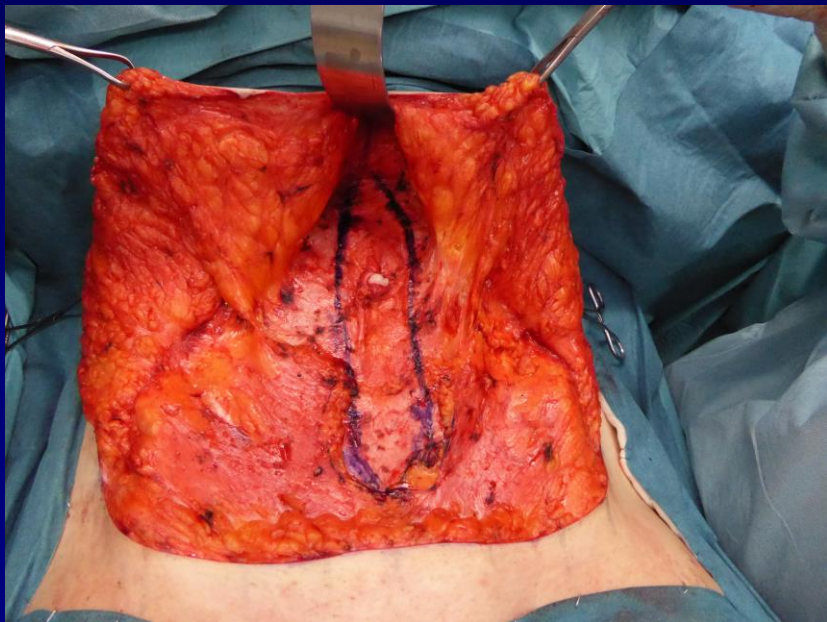
Resect midline strip  
of Scarpa's fascia







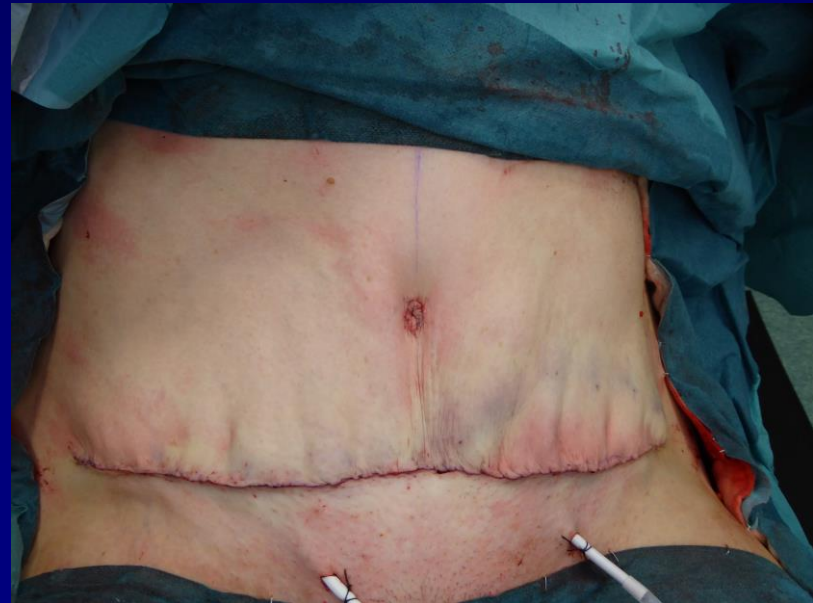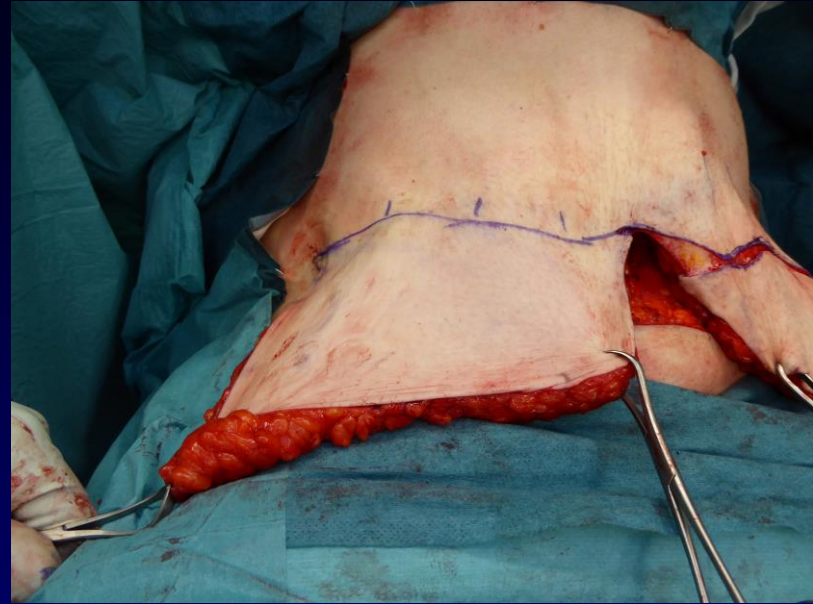
## Plication



# ABDOMINOPLASTY

## Technique [cont]

10. Selective undermining centrally
11. Plicate Rectus  
paralyse, mark, suture[permanent]
12. +/- quilting suts
13. Irrigate wound
14. Flex op table
15. Mark & resect skin +/- thin fat
16. Drains
17. Suture midline
18. Mark umbi
19. Close wounds 3 layers
20. umbilicoplasty





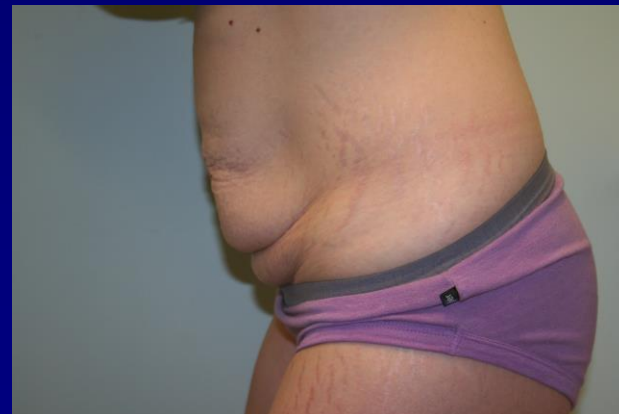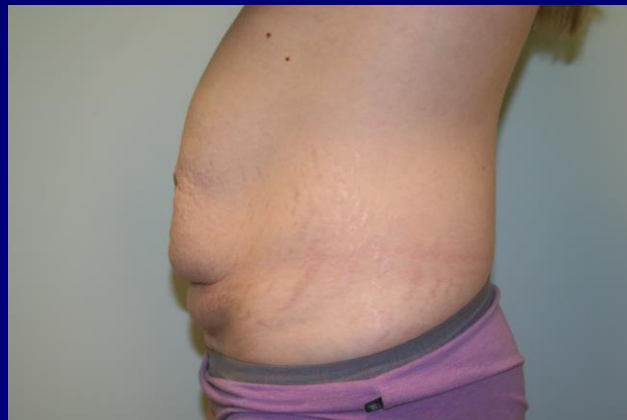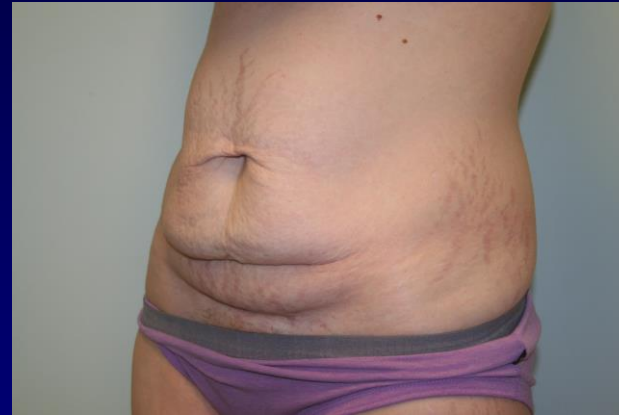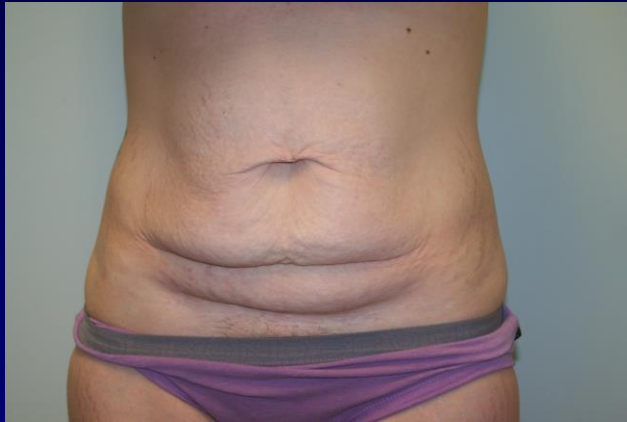# ABDOMINOPLASTY

## Post Op

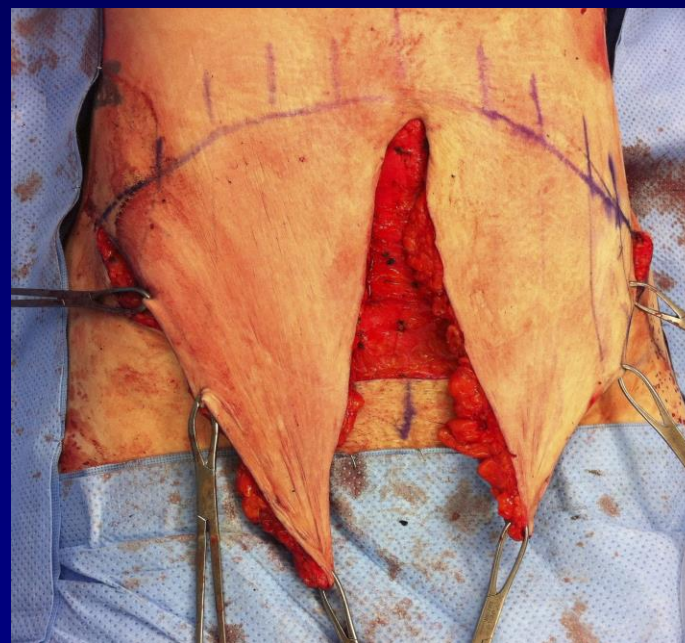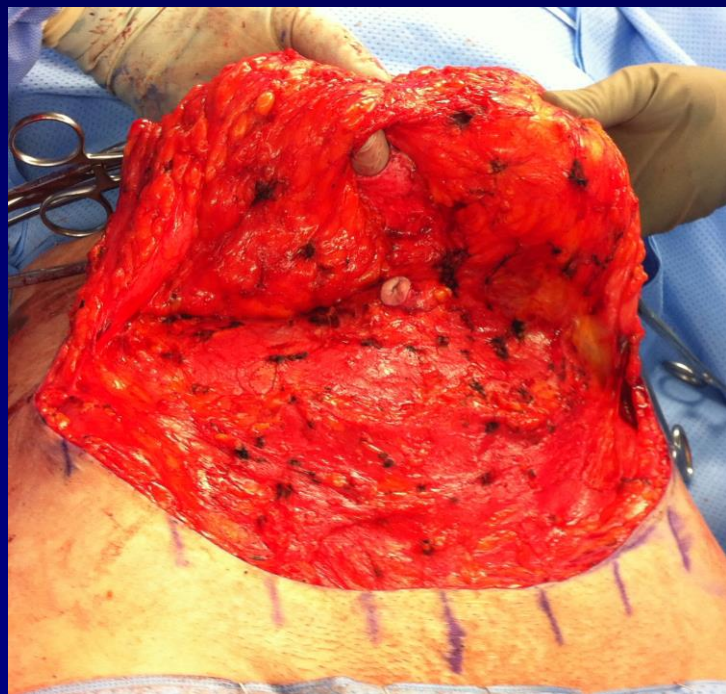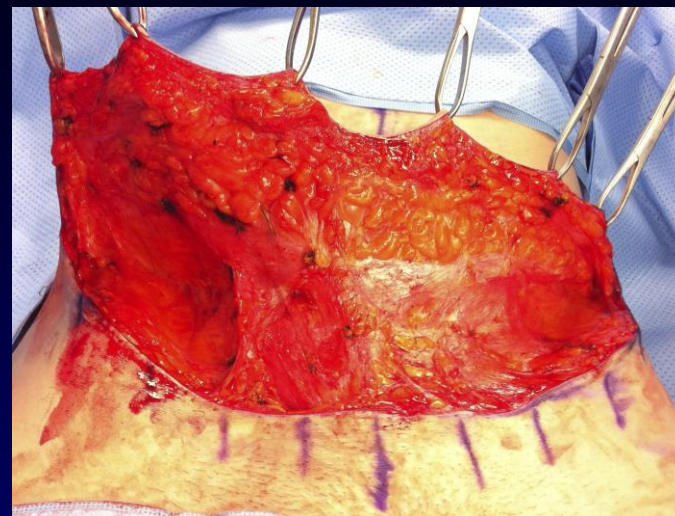
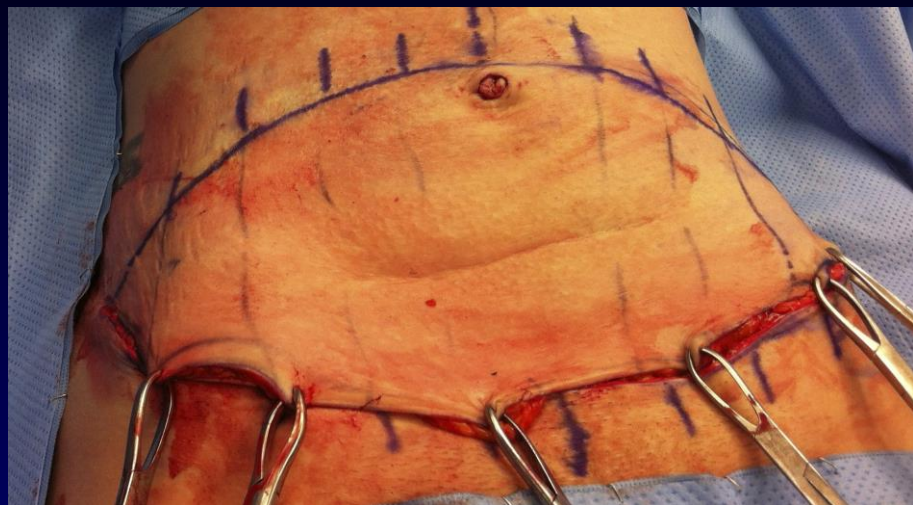
- Dressing
- Abdo binder
- Nurse flexed
- Remove IDC day 1
- Heparin / Clexane 2-3 days
- Drains < 30 ml /24hrs [usu 4 days]
- Ambulate stooped 1/52
- No vigorous ex for 3/12

# STANDARD ABDOMINOPLASTY [Radical]

Age : 31  
Children: 4 all delivered by Caesarian section  
Main concern: dislikes loose, stretched, abdo skin with overhang & unsightly scarring  
Examination: thin [BMI=21], striae, scars x2, divarication recti [3.5 cm ], lower overhanging rolls x2, mod pot belly

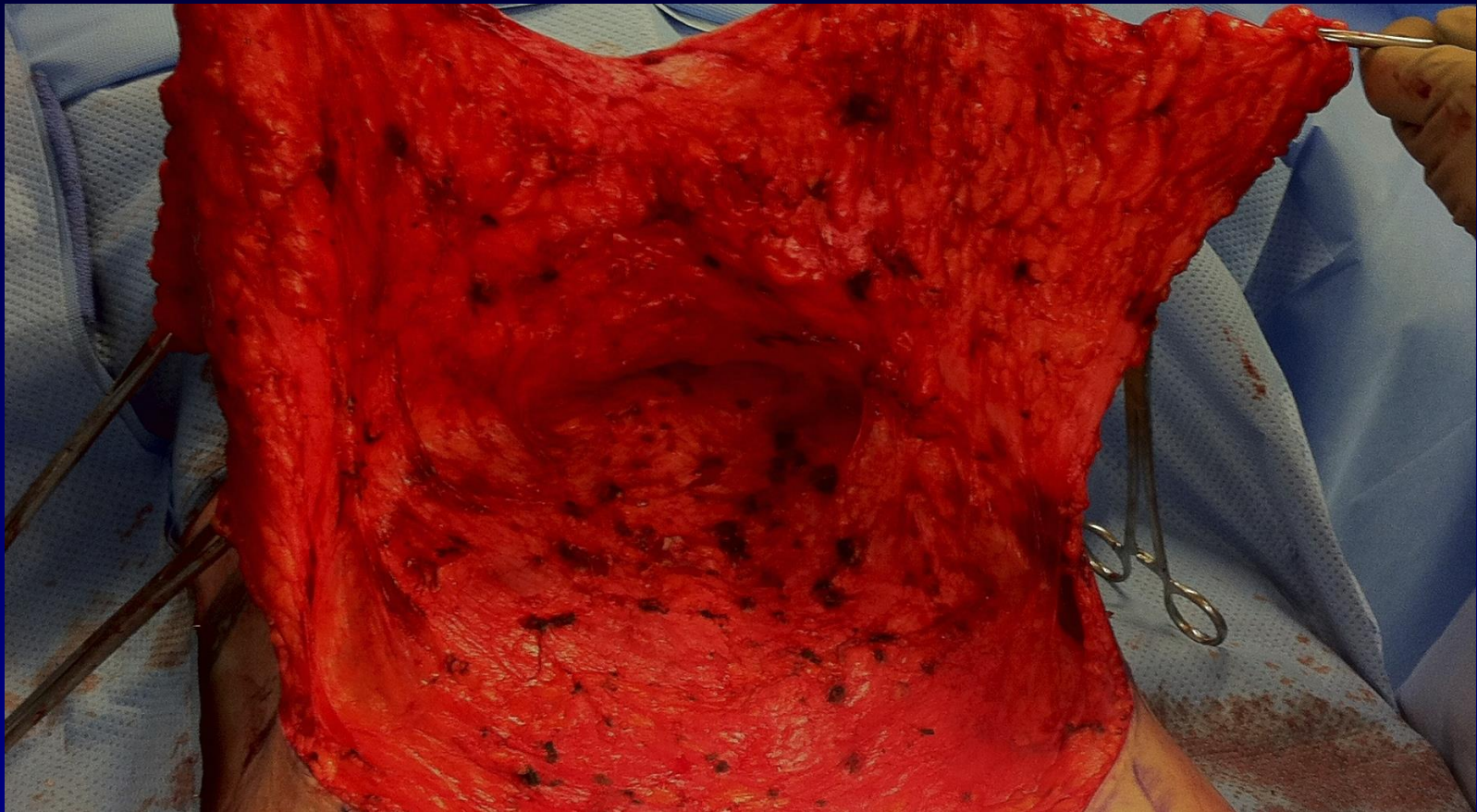

# STANDARD ABDOMINOPLASTY





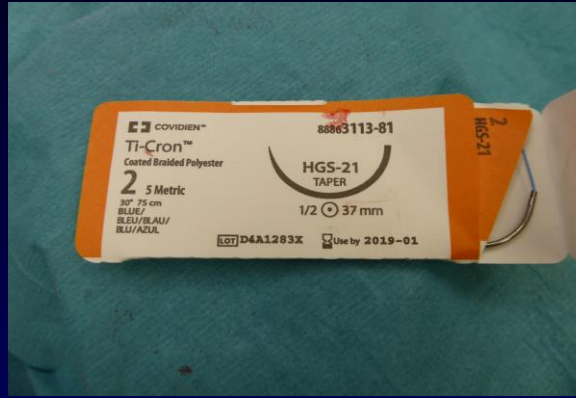
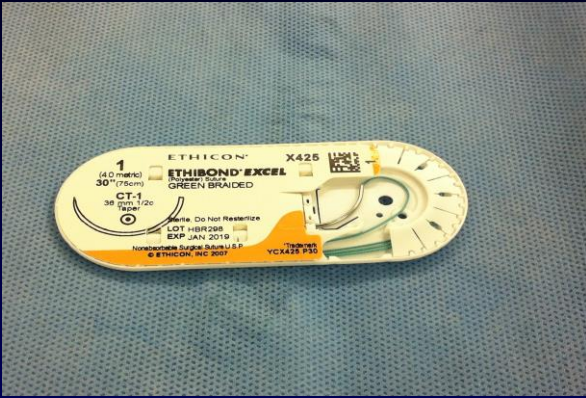# STANDARD ABDOMINOPLASTY



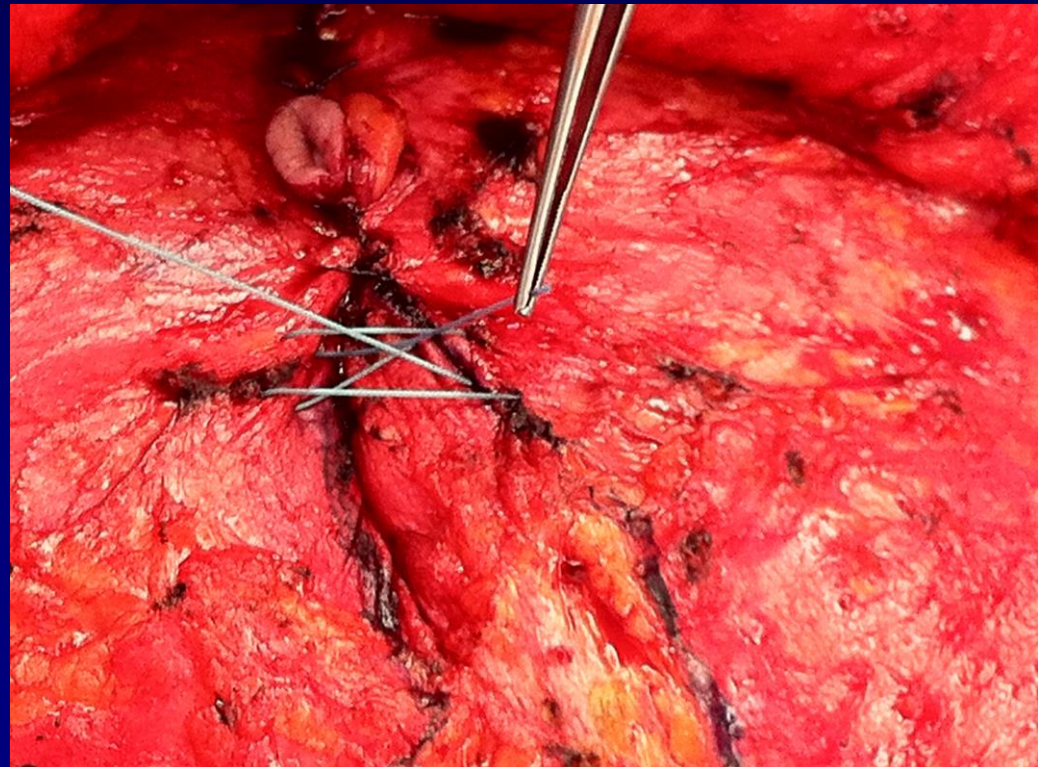
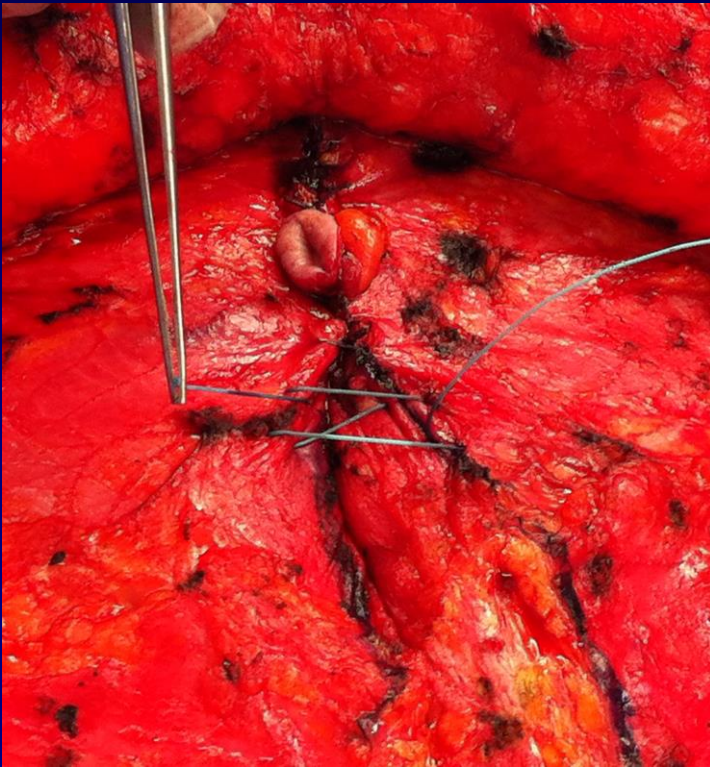


# STANDARD ABDOMINOPLASTY

## Plication [ 1 -2 layers]



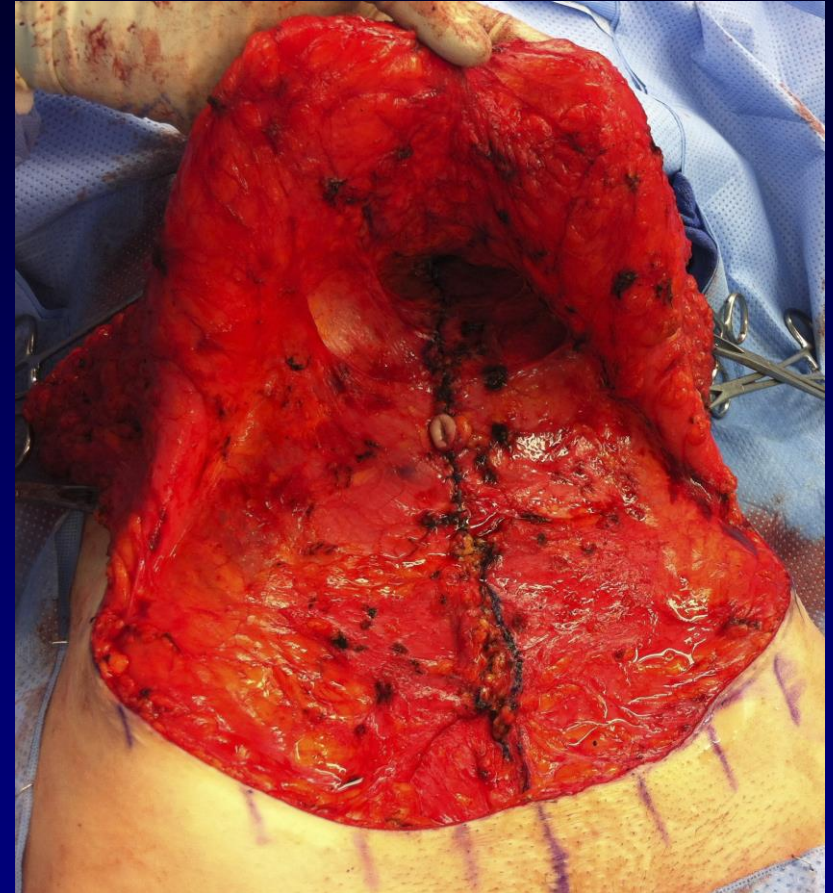
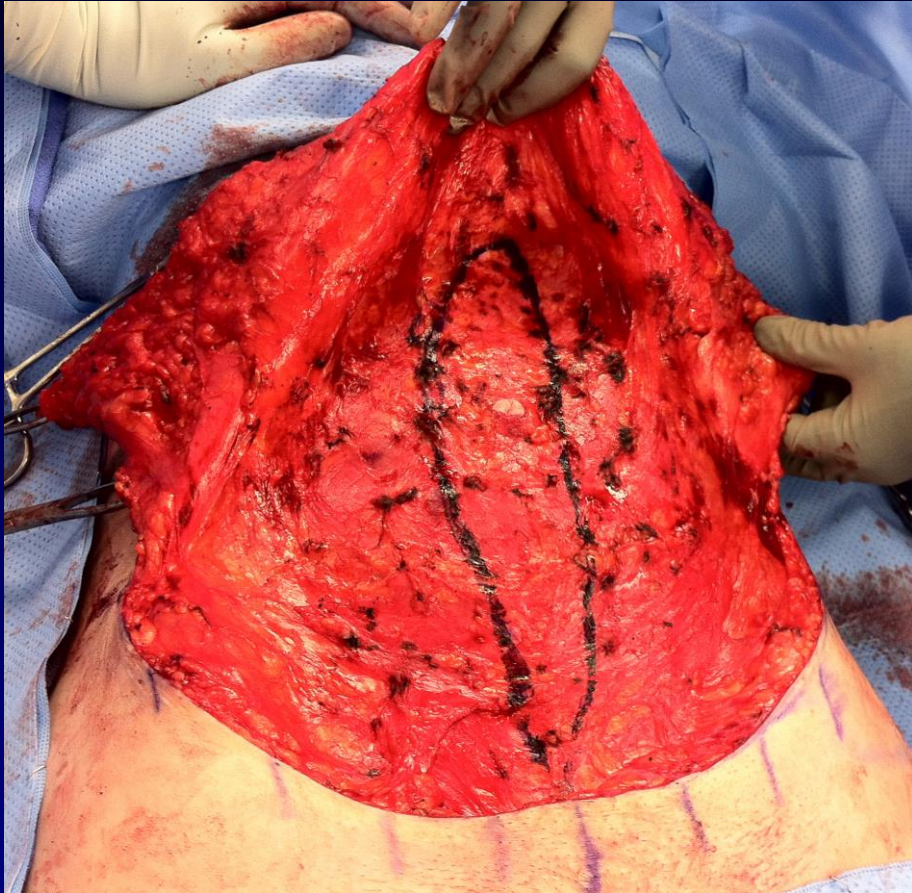
1<sup>st</sup> Layer  
permanent  
Ethibond /Ticron  
X suture





# STANDARD ABDOMINOPLASTY

## Plication

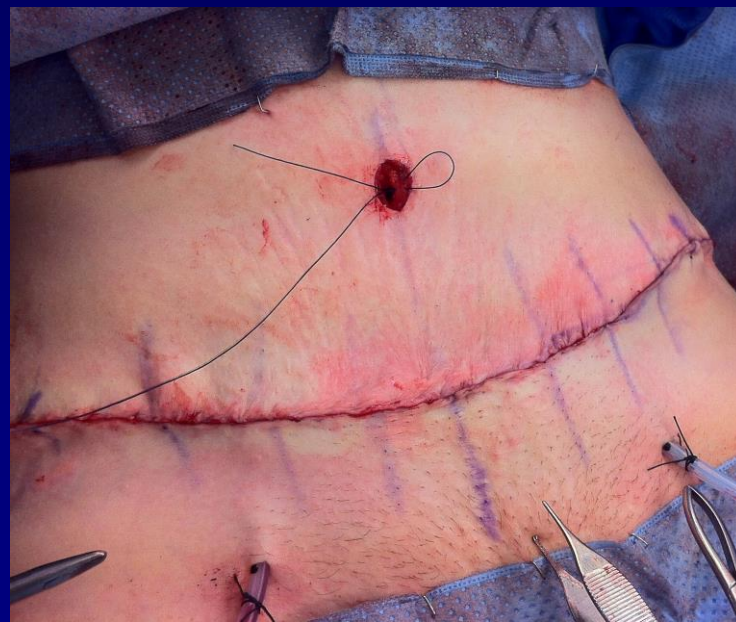
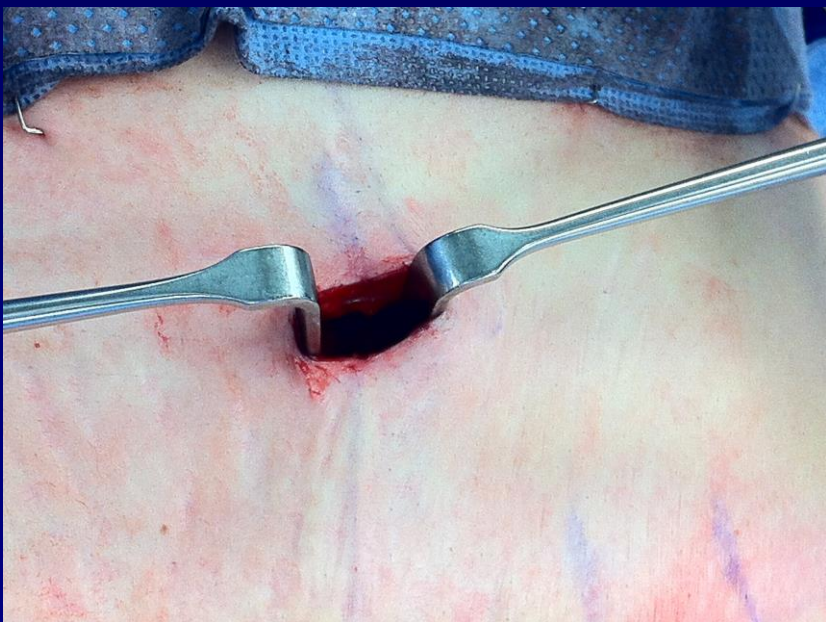
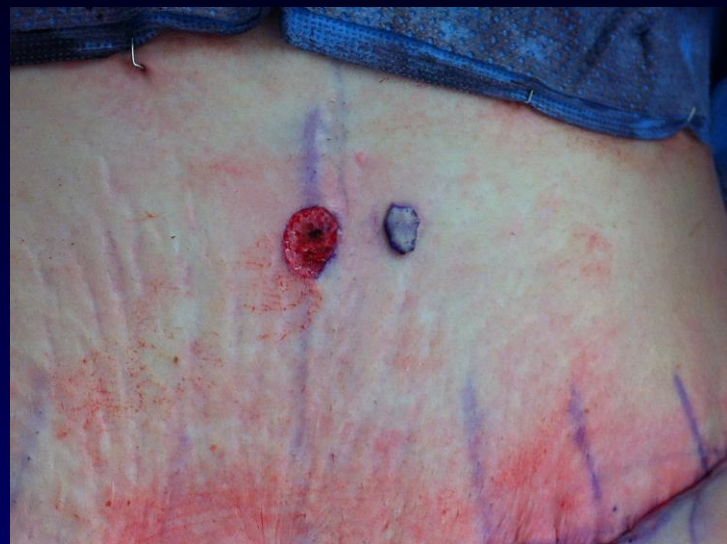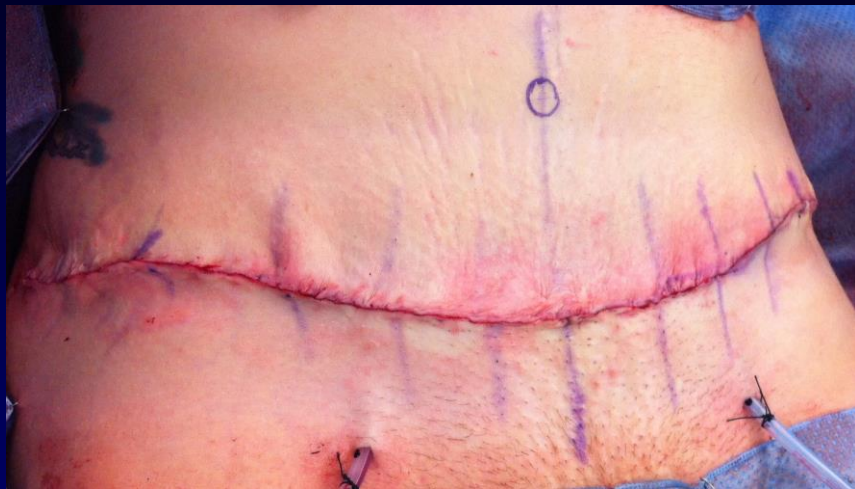2<sup>nd</sup> Layer:

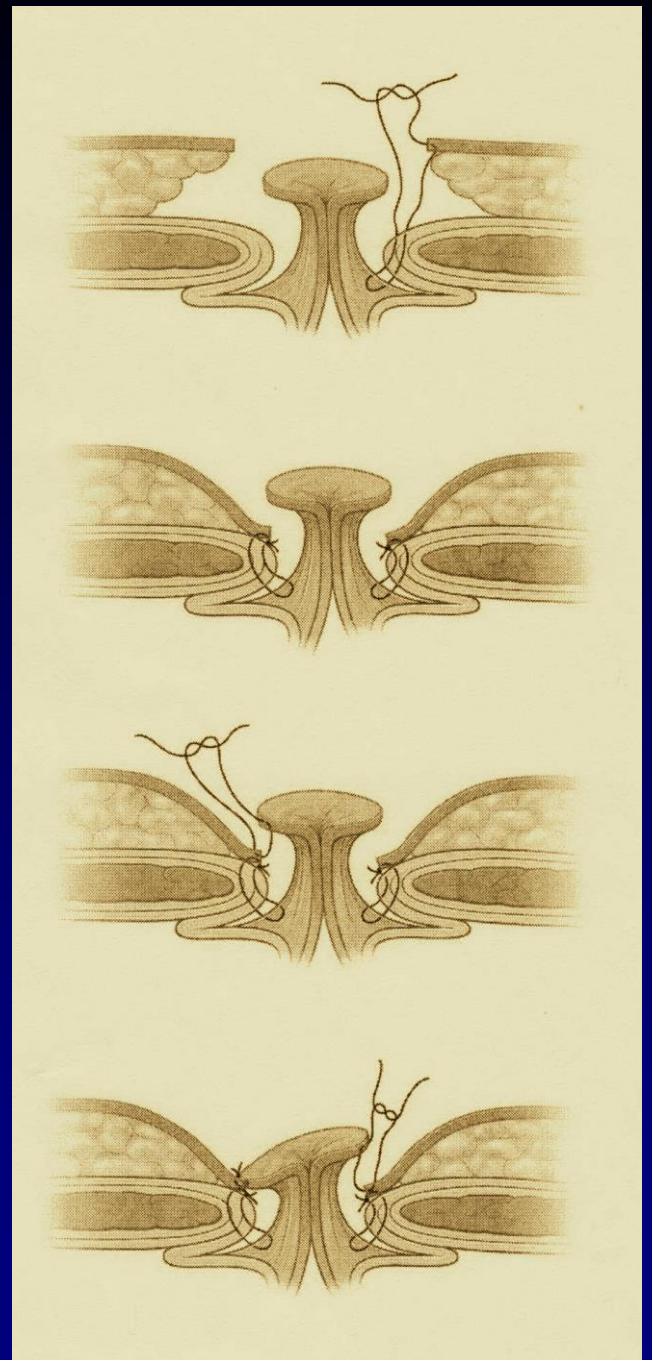
continuous, absorbable, barbed [V-lock etc]



# STANDARD ABDOMINOPLASTY

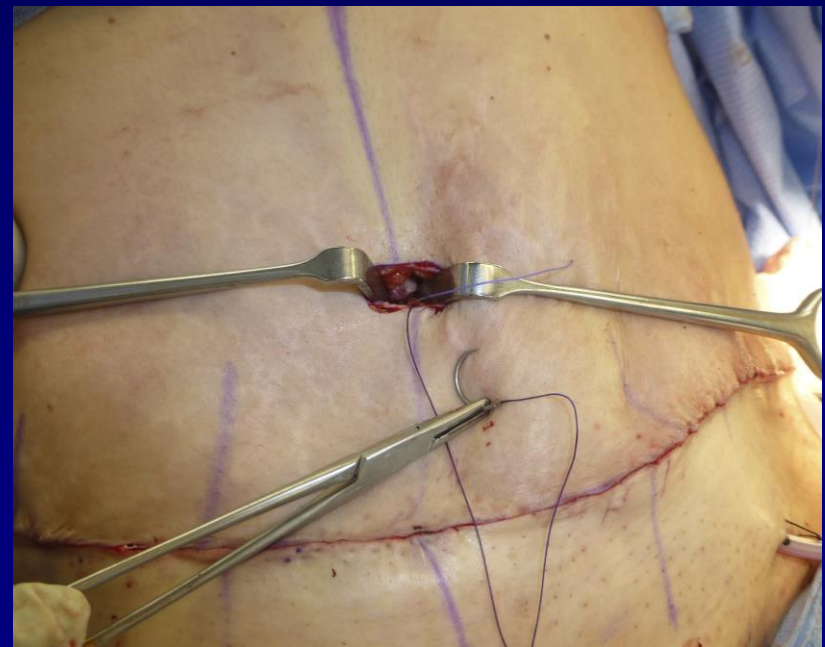
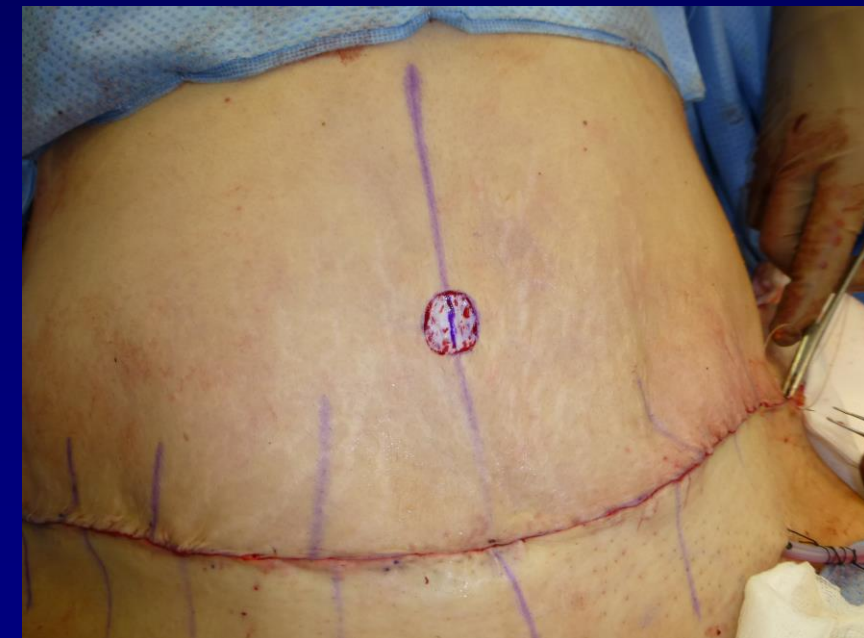
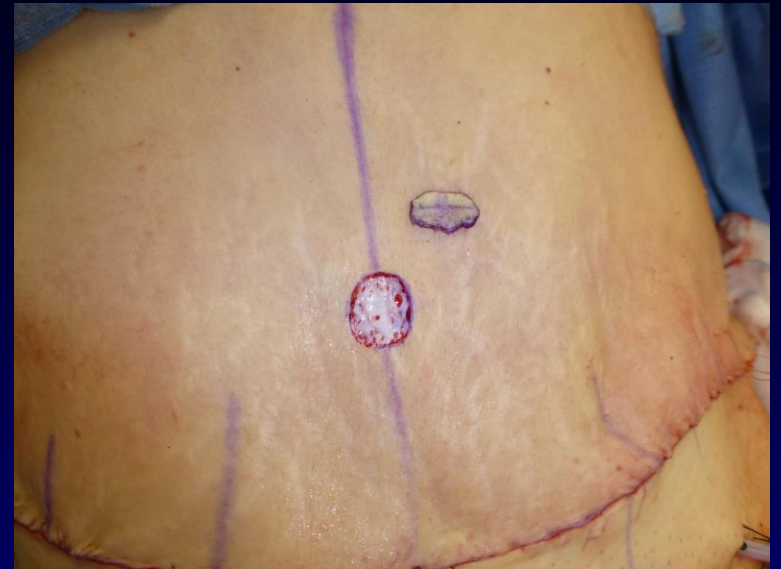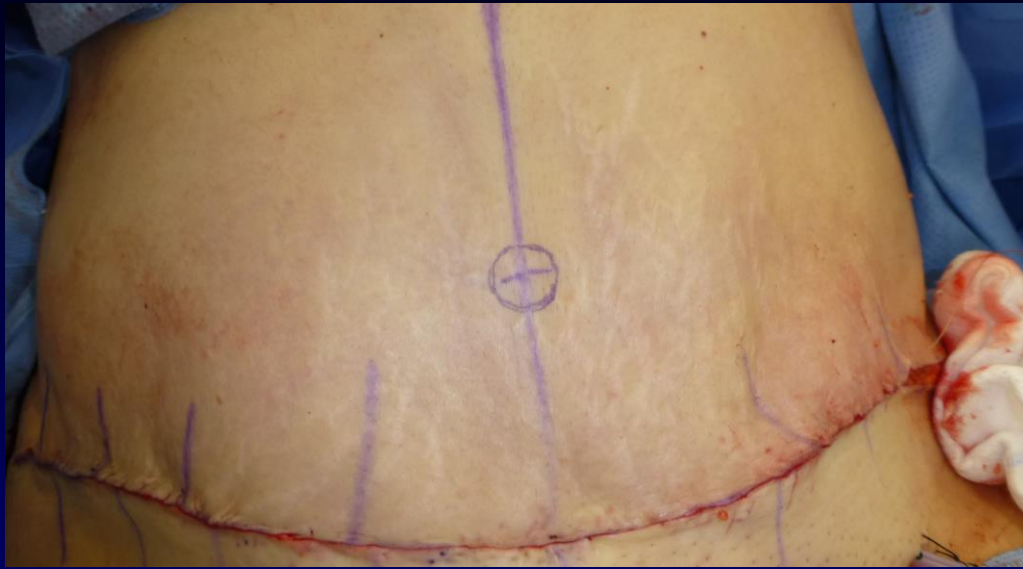# UMBILICOPLASTY

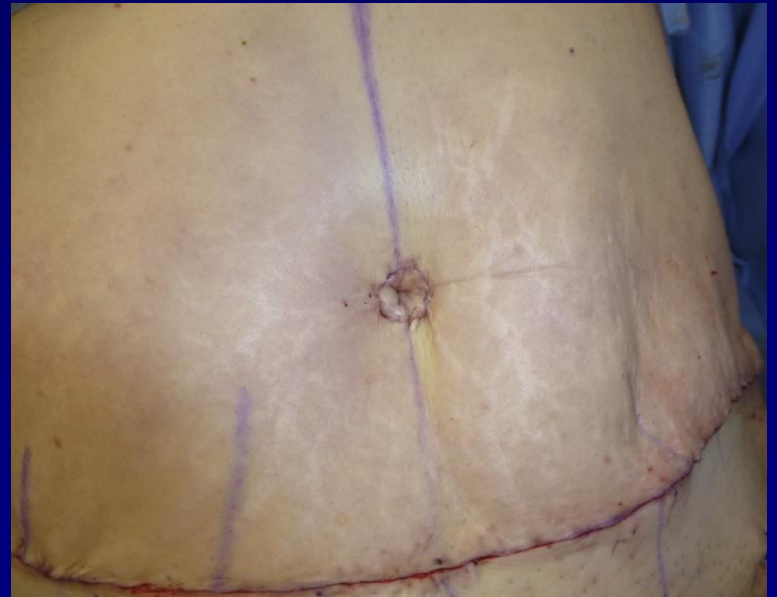
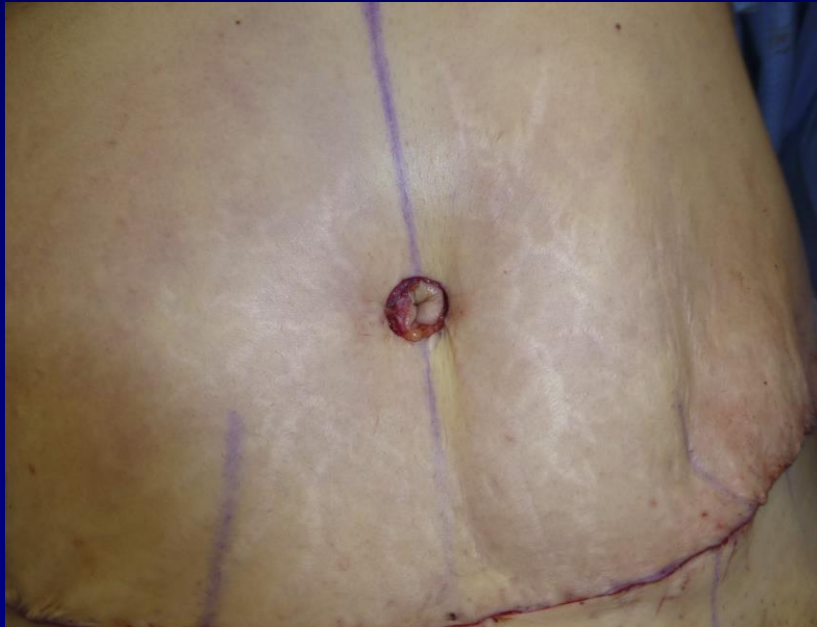
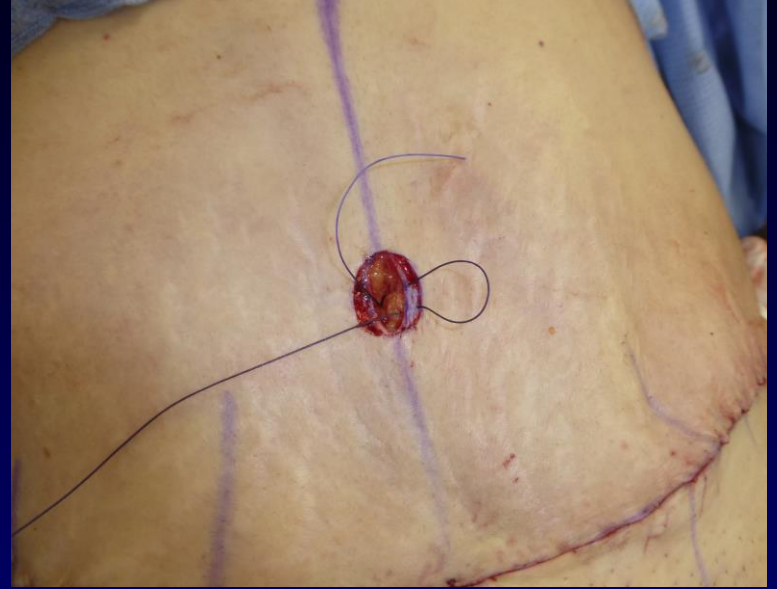

# UMBILICOPLASTY

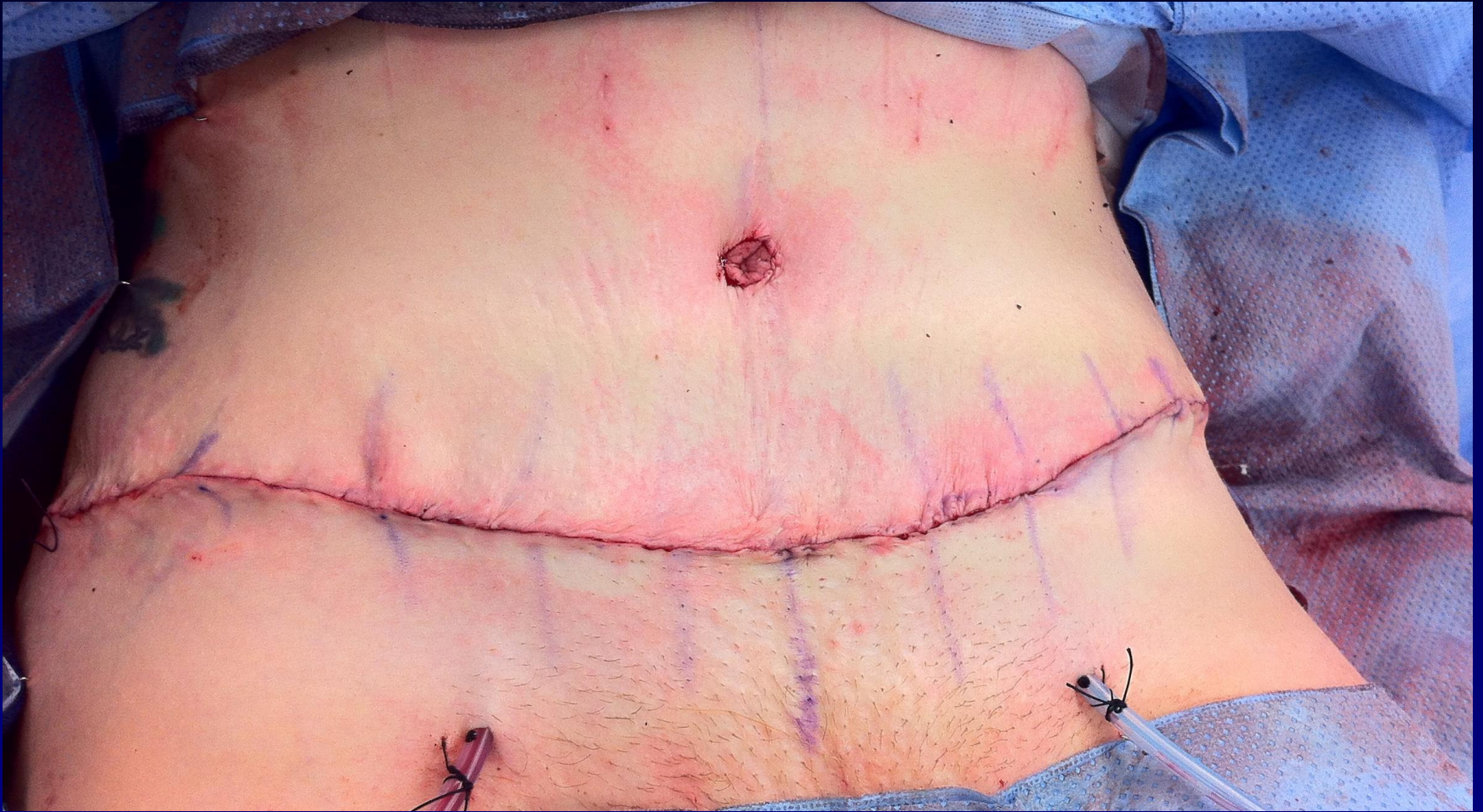

# UMBILICOPLASTY

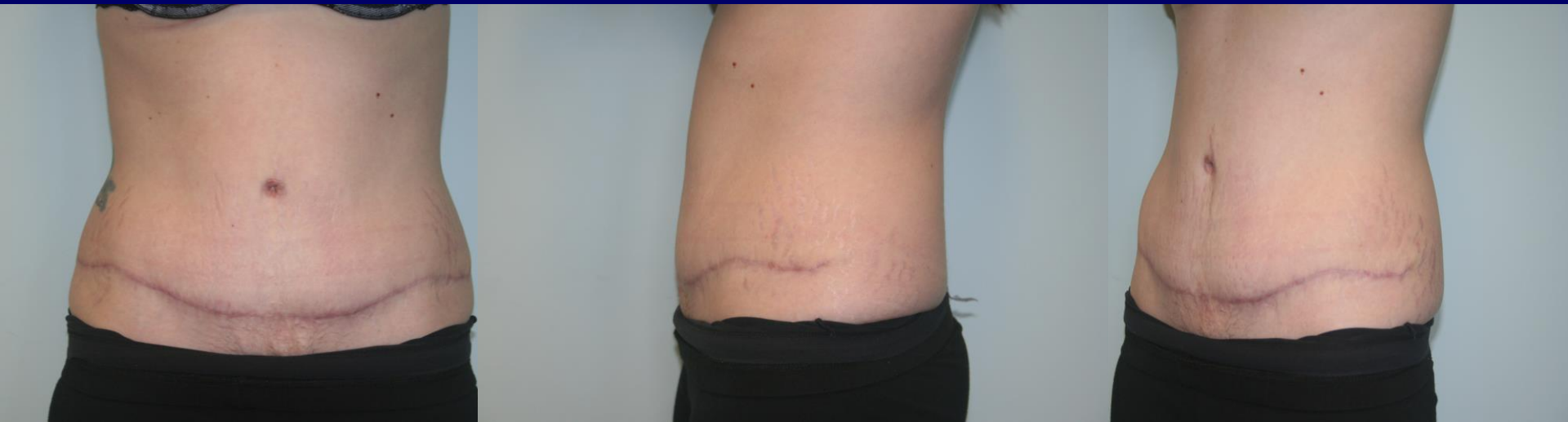
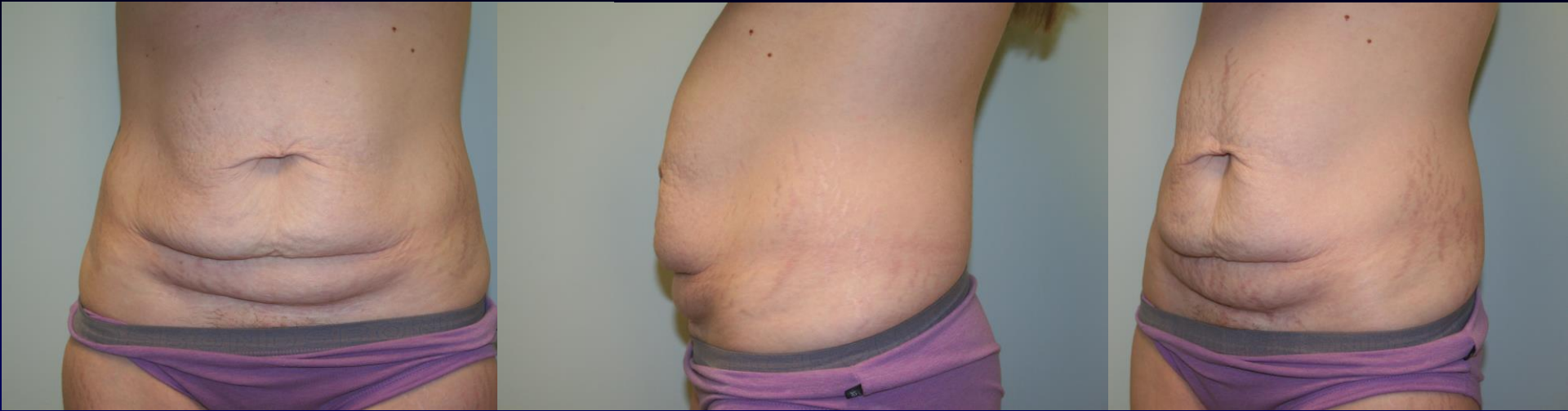


# STANDARD ABDOMINOPLASTY

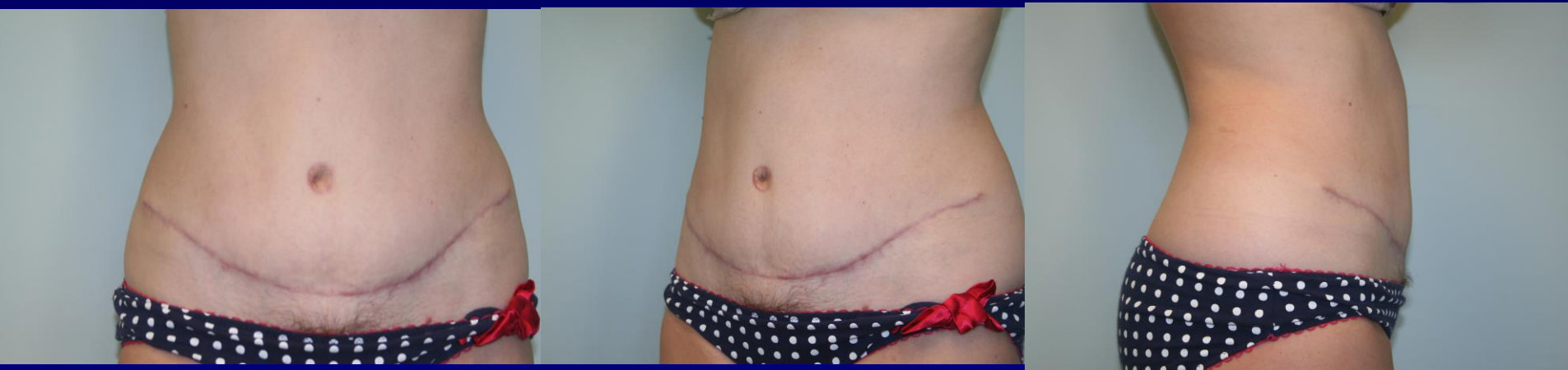
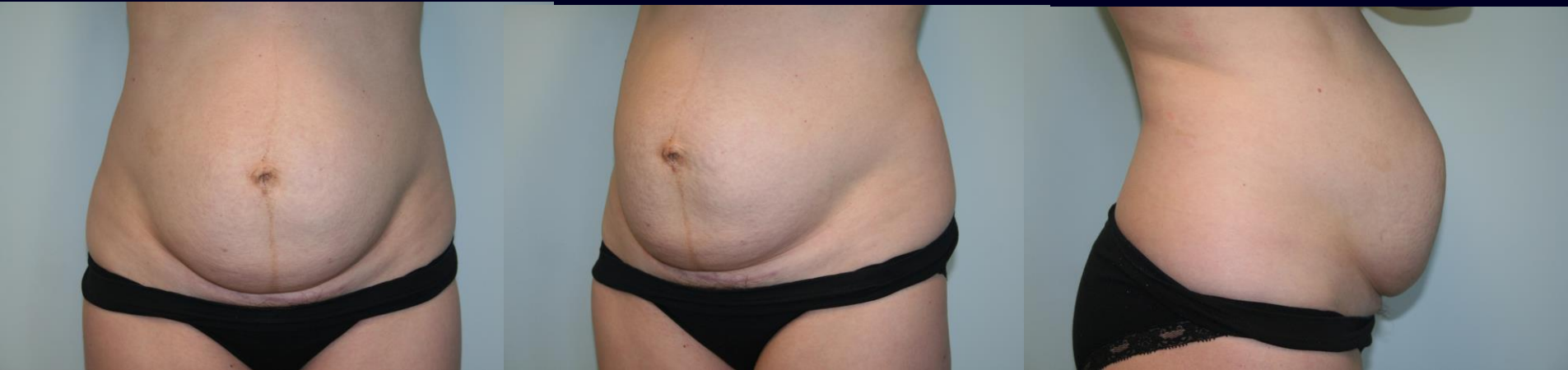
# STANDARD ABDOMINOPLASTY

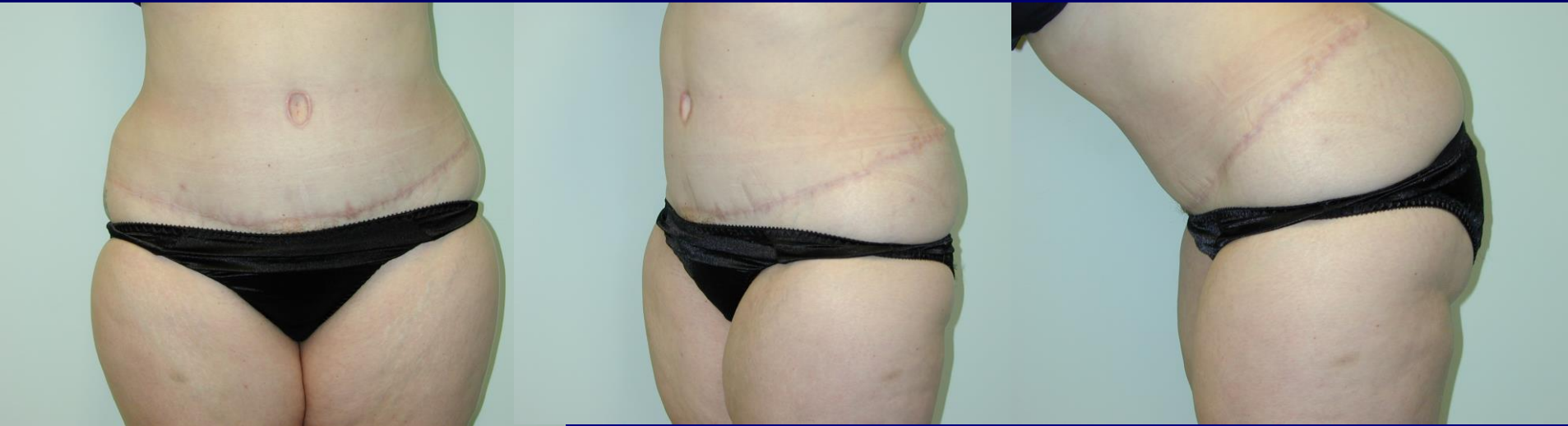
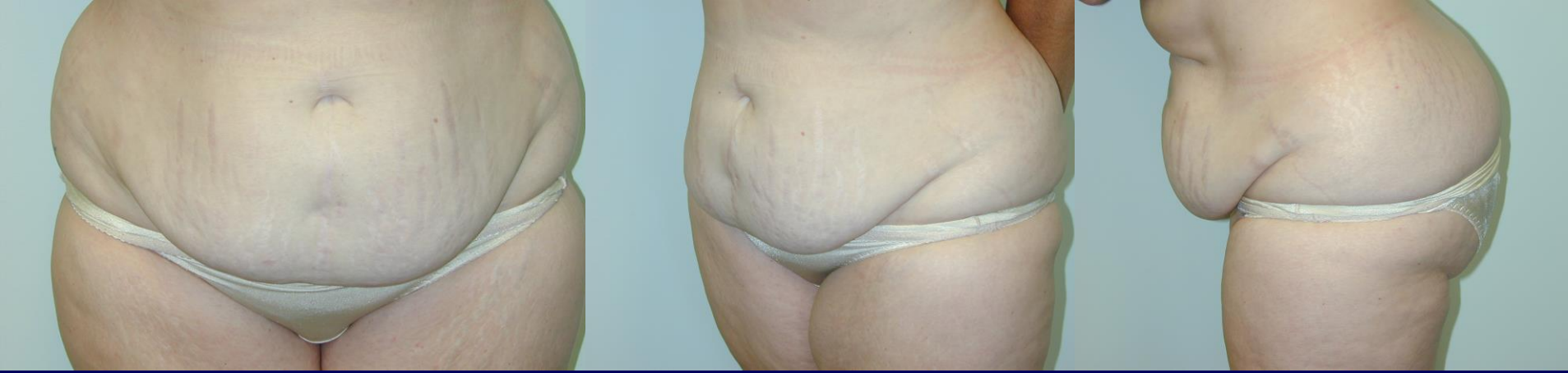


# STANDARD ABDOMINOPLASTY



# STANDARD ABDOMINOPLASTY



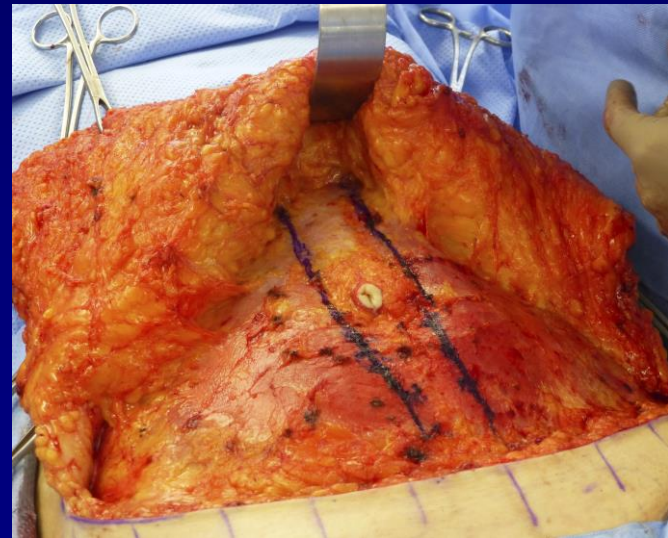
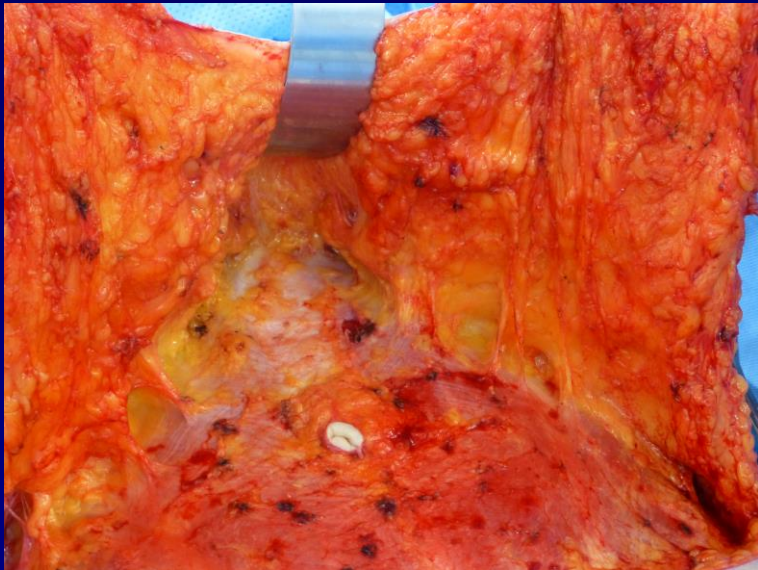
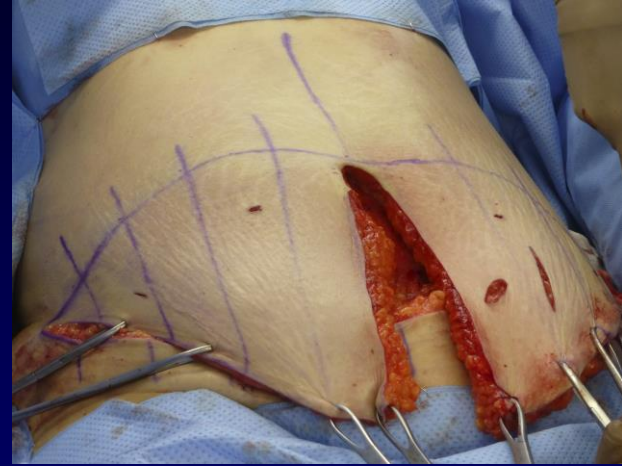
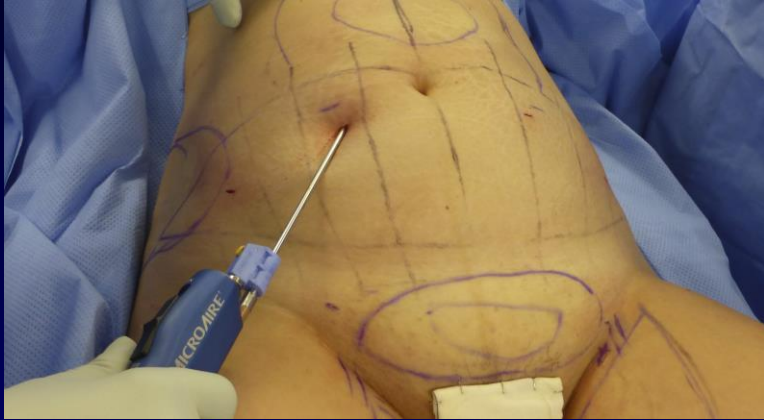# ABDOMINOPLASTY

## PROCEDURES

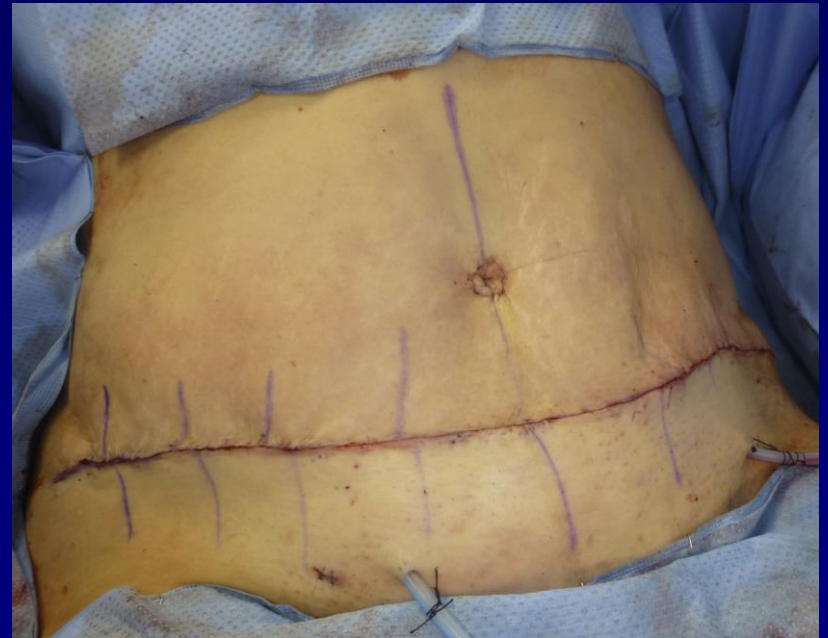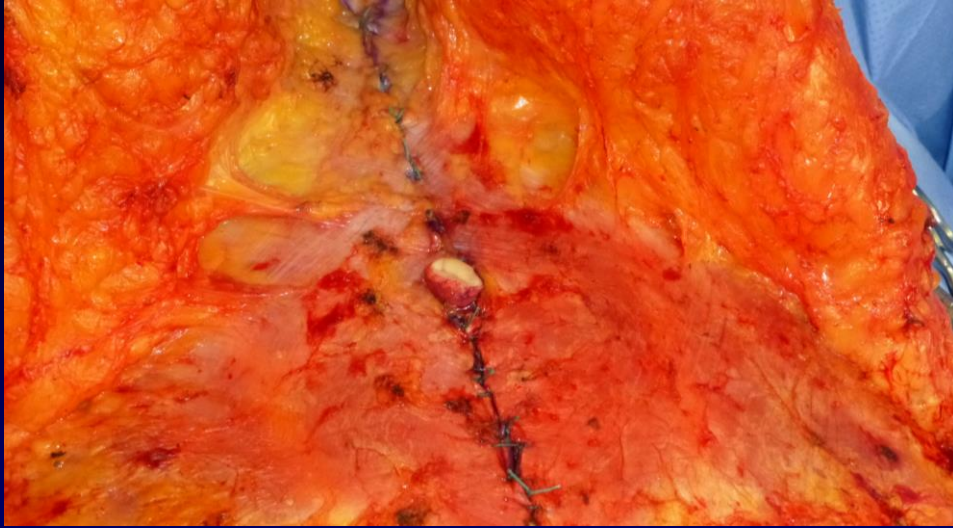
1. Liposuction only
2. " + diastasis repair
3. Subumbilical [mini] abdominoplasty
4. Standard [radical, traditional] abdominoplasty
5. **Lipo Abdominoplasty**
6. High lateral tension abdominoplasty [Lockwood]
7. Modified vertical abdominoplasty [fleur-de-lis]
8. Panniculectomy
9. Circumferential abdominoplasty [bodylift, belt lipectomy]
10. Reverse [upper] abdominoplasty
11. Other [lipo to other areas, hernia repairs, scar revisions, abdo op's eg hysters, other op's eg thighs, breasts, face.]



# LIPO ABDOMINOPLASTY



# LIPO ABDOMINOPLASTY



# ABDOMINOPLASTY

## PROCEDURES

1. Liposuction only
2. " + diastasis repair
3. Subumbilical [mini] abdominoplasty
4. Standard [radical, traditional] abdominoplasty
5. Lipo Abdominoplasty
6. High lateral tension abdominoplasty [Lockwood]
7. **Modified vertical abdominoplasty [fleur-de-lis]**
8. Panniculectomy
9. Circumferential abdominoplasty [bodylift, belt lipectomy ]
10. Reverse [upper] abdominoplasty
11. Other [lipo to other areas, hernia repairs, scar revisions, abdo op's eg hysters, other op's eg thighs, breasts, face.]



# Modified Vertical Abdominoplasty

## Fleur-De-Lis

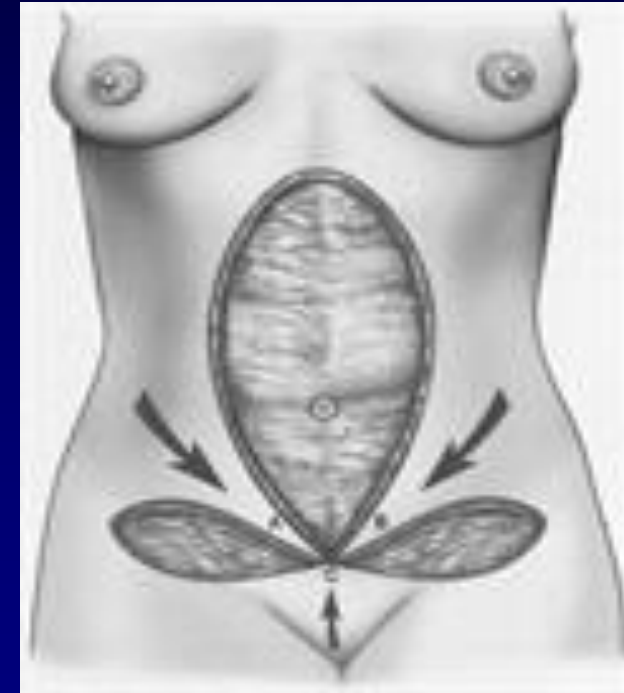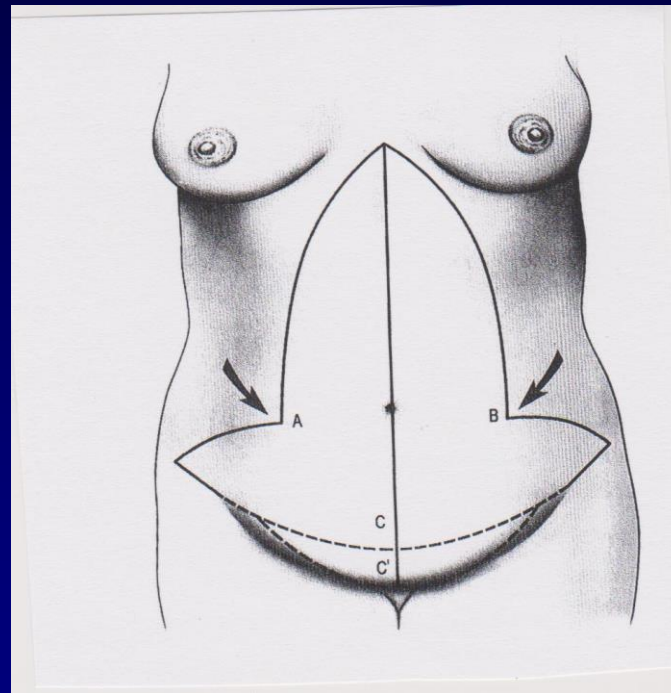
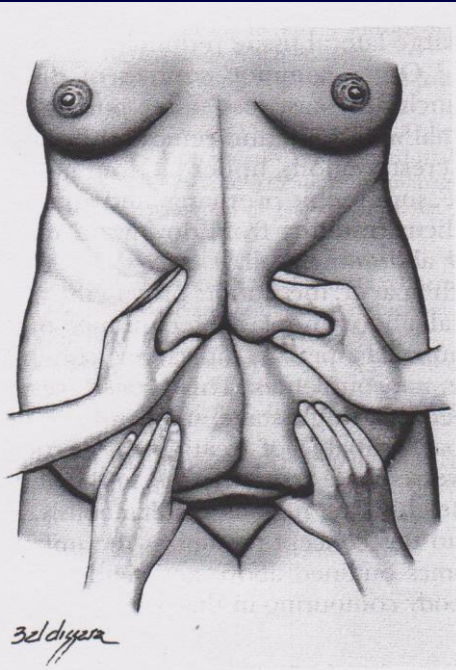


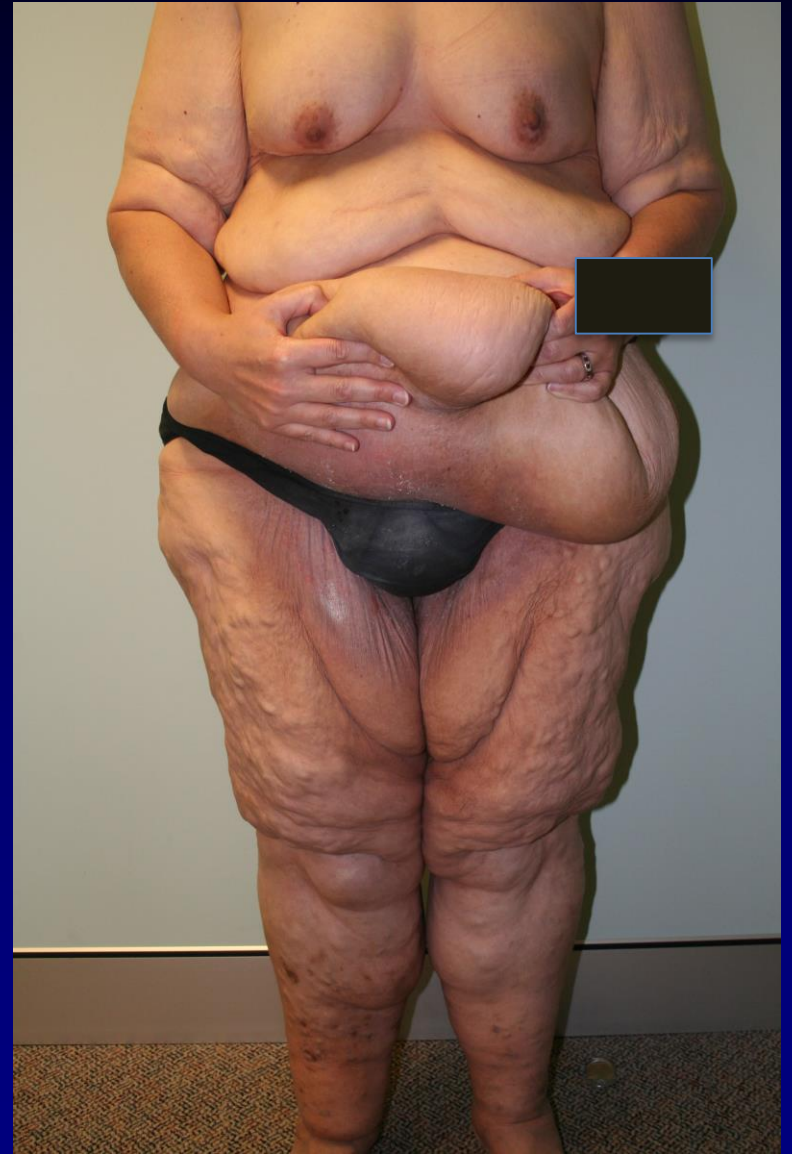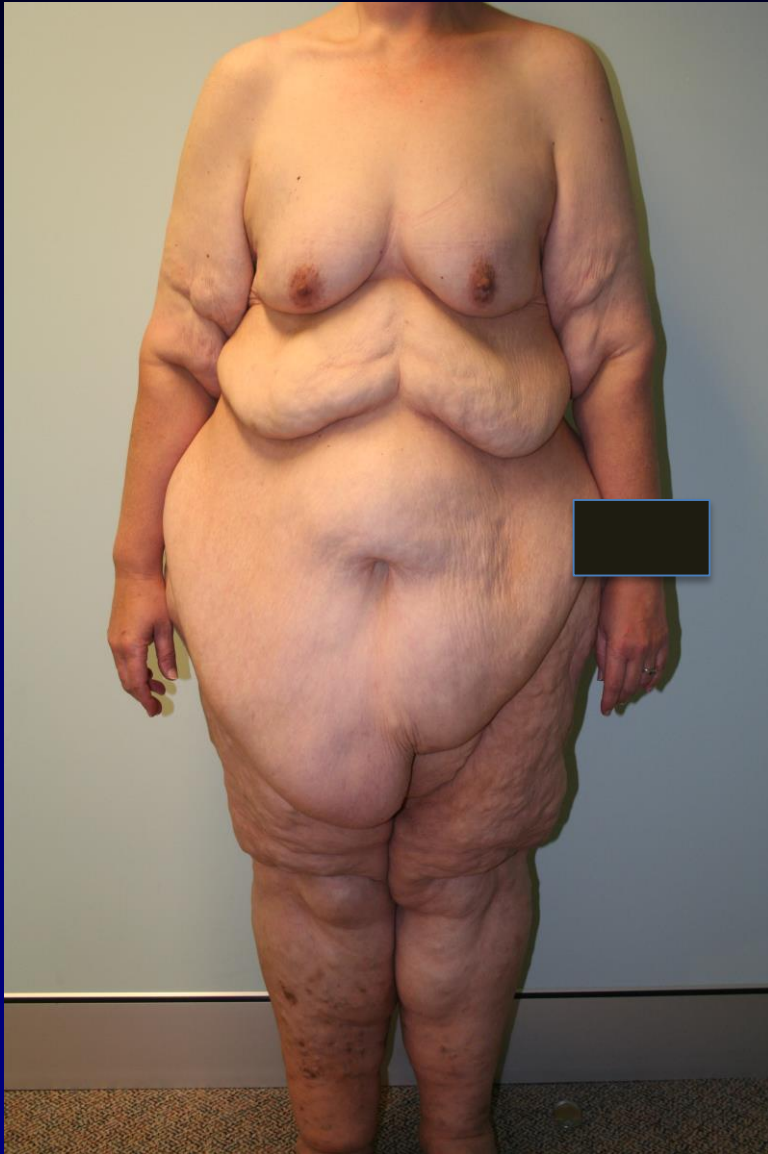
Fig. 1. With the patient standing, the tissue redundancies

# ABDOMINOPLASTY

## PROCEDURES

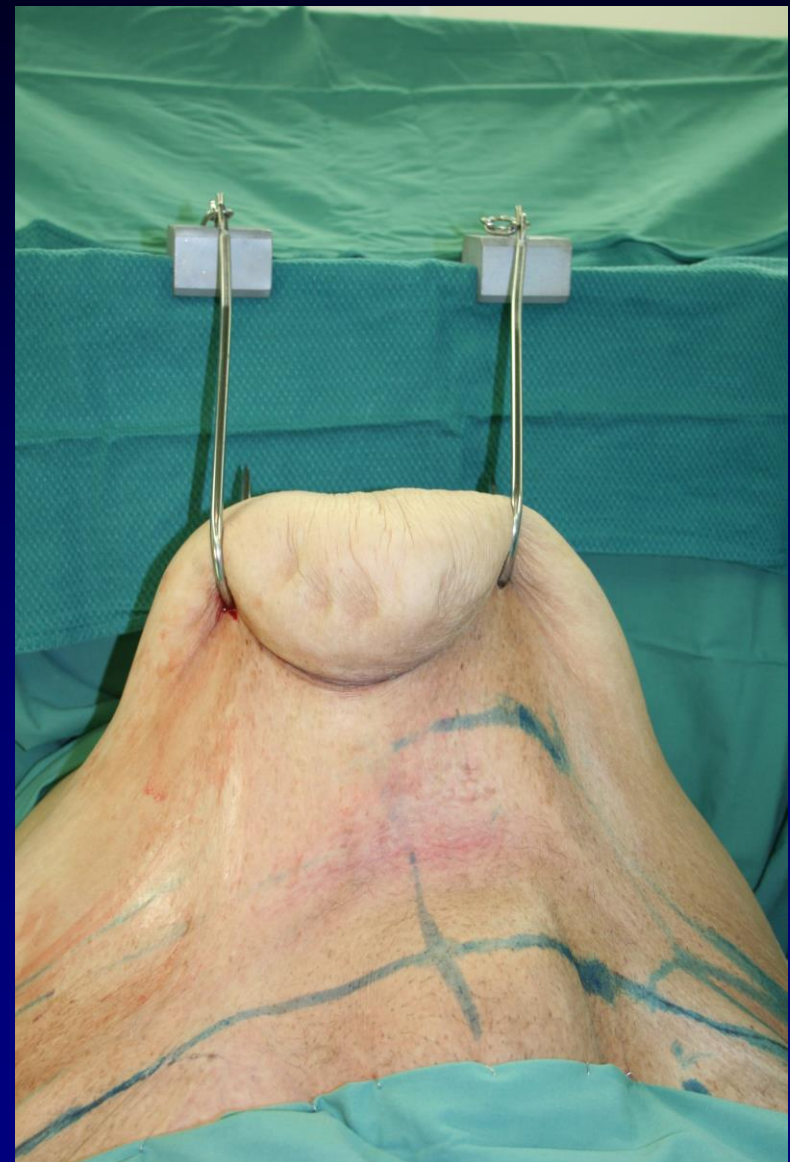
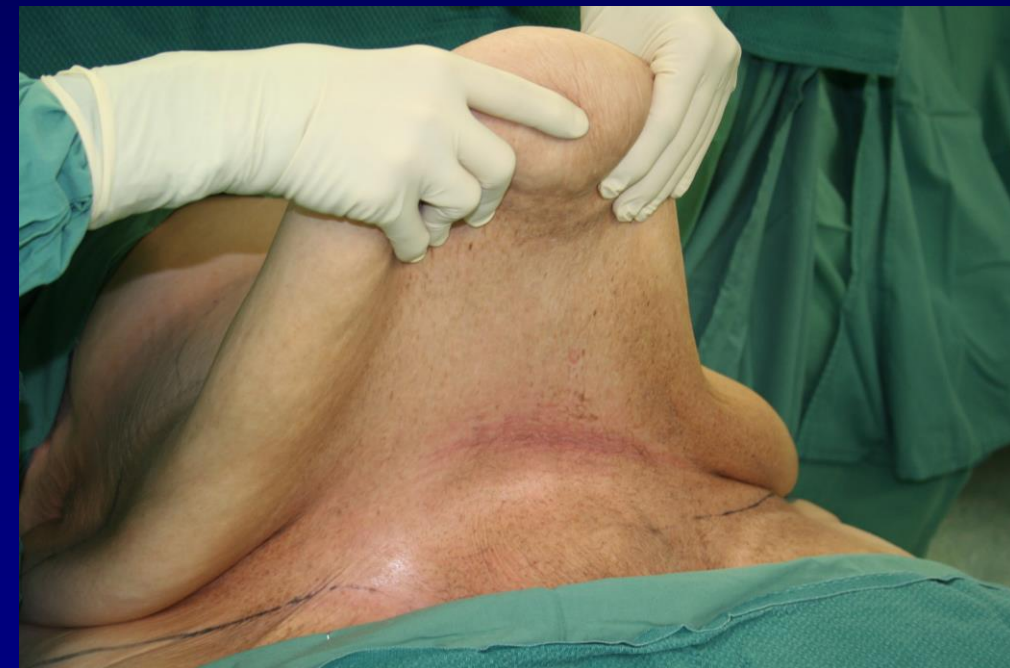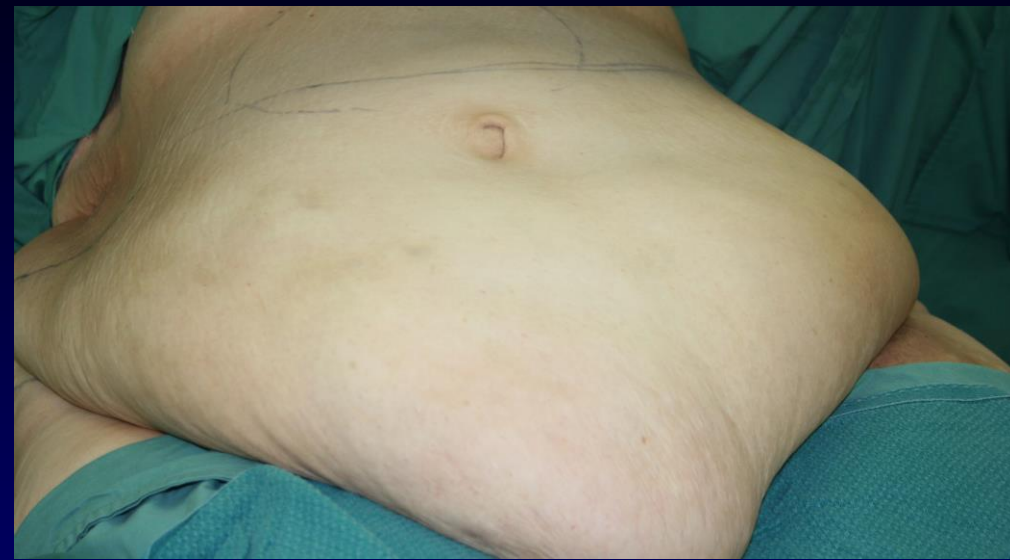1. Liposuction only
2. " + diastasis repair
3. Subumbilical [mini] abdominoplasty
4. Standard [radical, traditional] abdominoplasty
5. Lipo Abdominoplasty
6. High lateral tension abdominoplasty [Lockwood]
7. Modified vertical abdominoplasty [fleur-de-lis]
8. **Panniculectomy**
9. Circumferential abdominoplasty [bodylift, belt lipectomy]
10. Reverse [upper] abdominoplasty
11. Other [lipo to other areas, hernia repairs, scar revisions, abdo op's eg hysters, other op's eg thighs, breasts, face.]

# PANNICULECTOMY

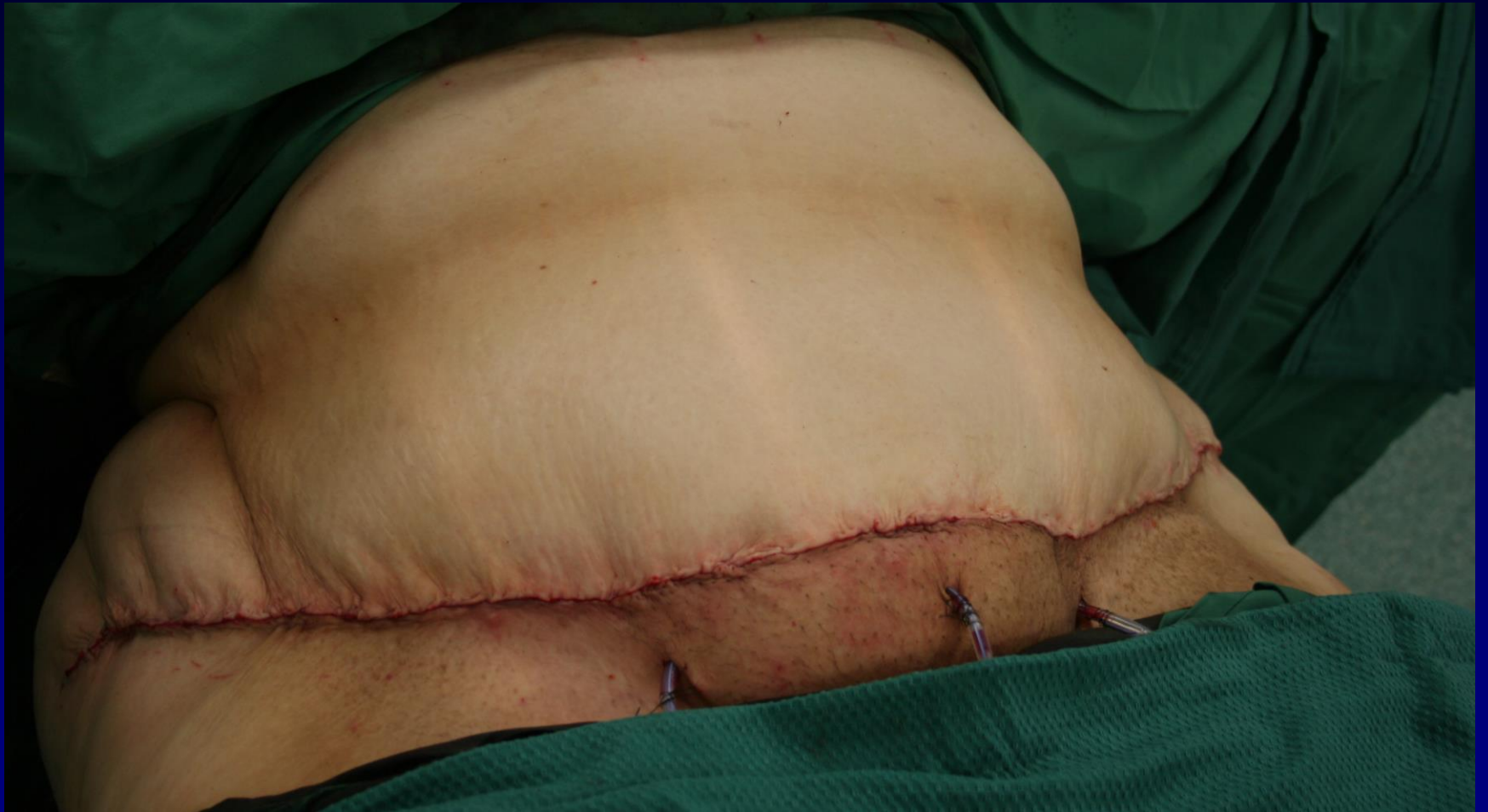



# PANNICULECTOMY



# PANNICULECTOMY



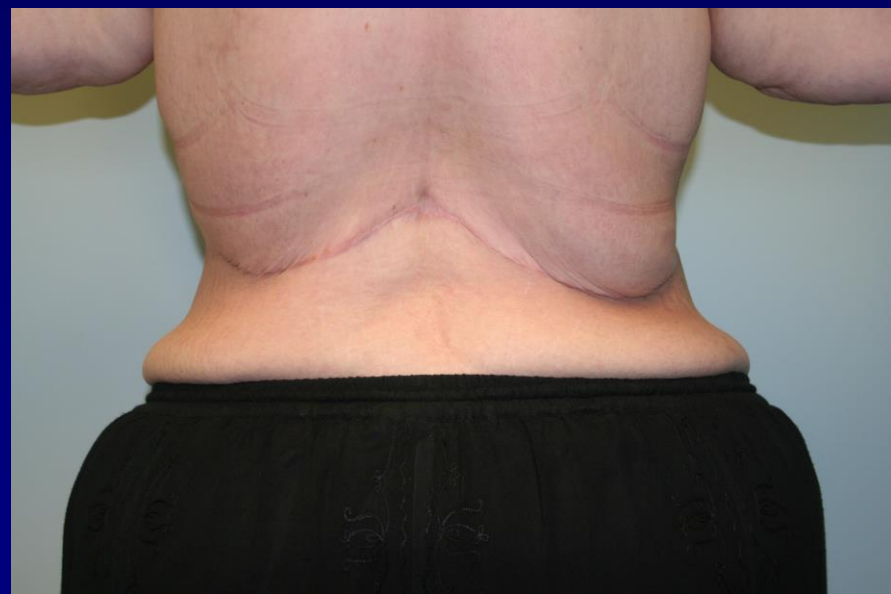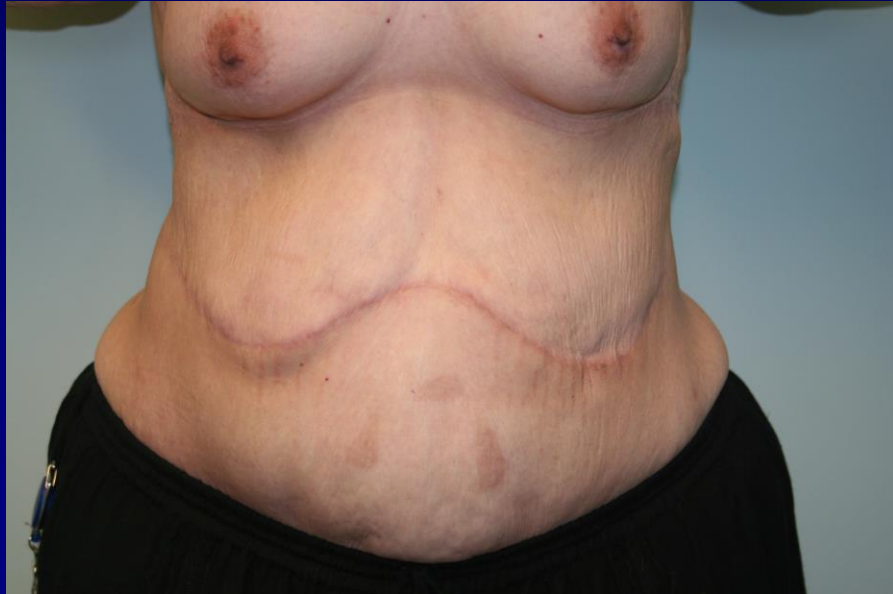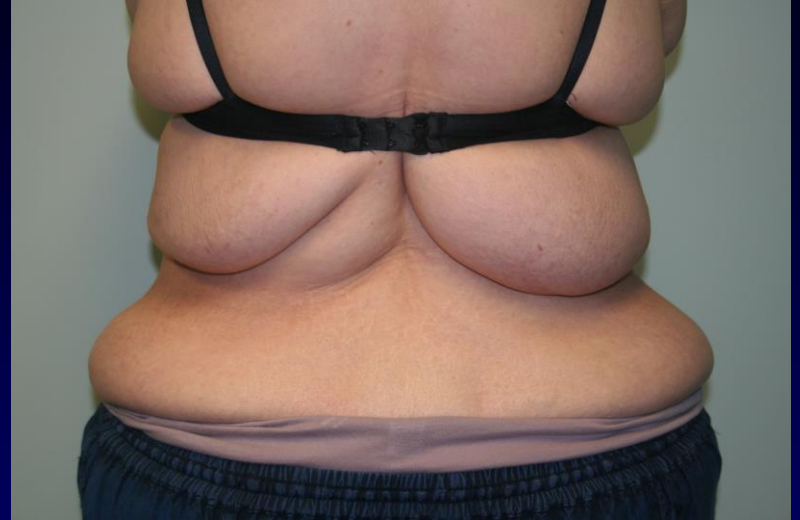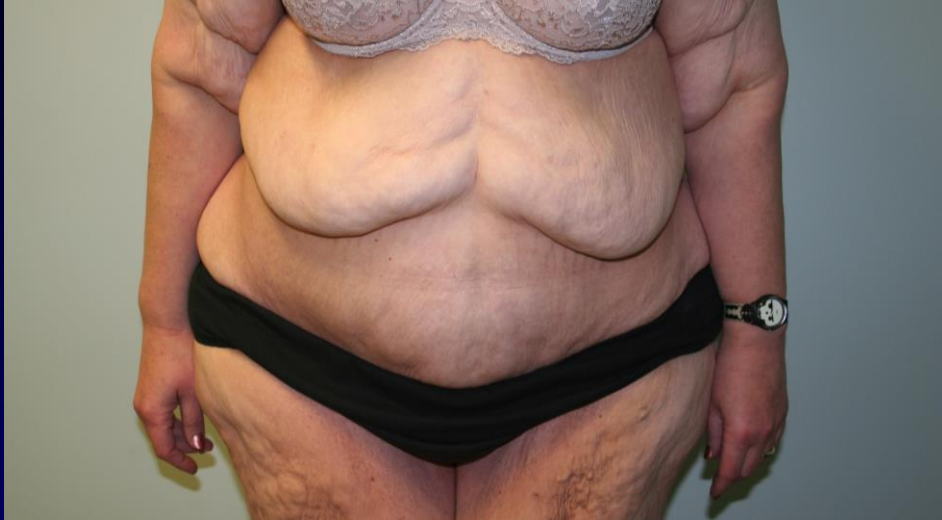# ABDOMINOPLASTY

## PROCEDURES

1. Liposuction only
2. " + diastasis repair
3. Subumbilical [mini] abdominoplasty
4. Standard [radical, traditional] abdominoplasty
5. Lipo Abdominoplasty
6. High lateral tension abdominoplasty [Lockwood]
7. Modified vertical abdominoplasty [fleur-de-lis]
8. Panniculectomy
9. Circumferential abdominoplasty [bodylift, belt lipectomy]
10. Reverse [upper] abdominoplasty
11. Other [lipo to other areas, hernia repairs, scar revisions, abdo op's eg hysters, other op's eg thighs, breasts, face.]



# CIRCUMFERENTIAL LIPECTOMY

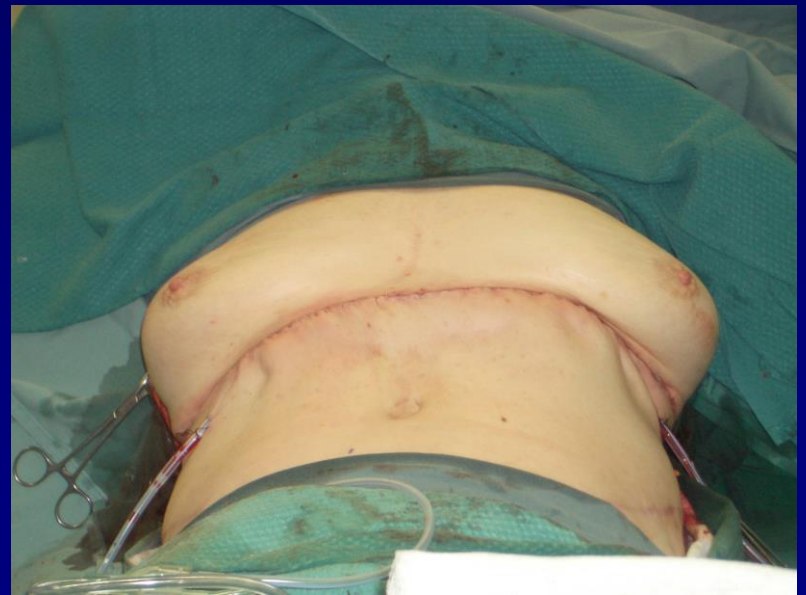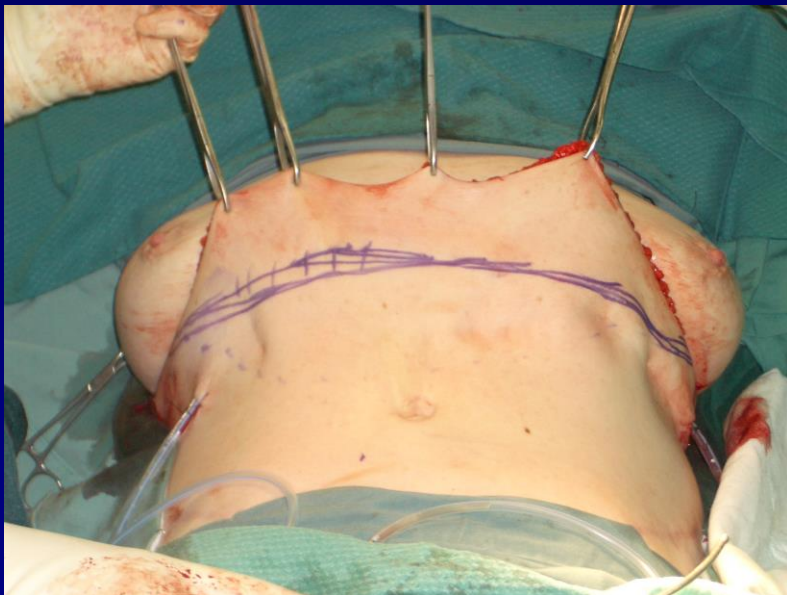
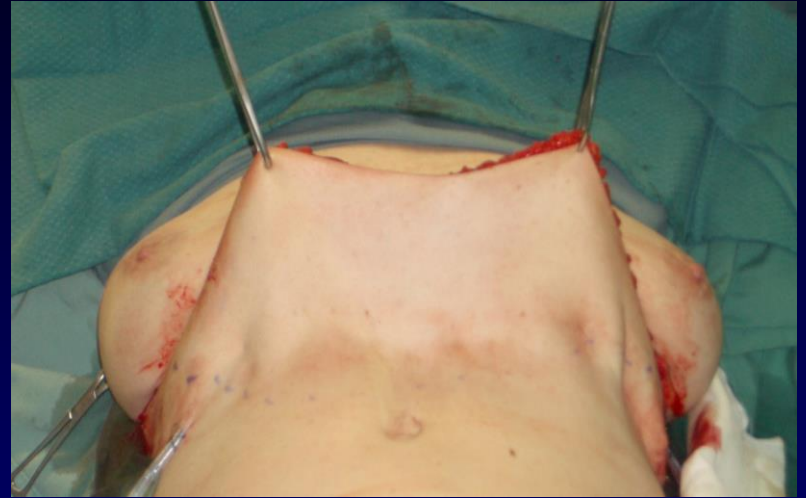

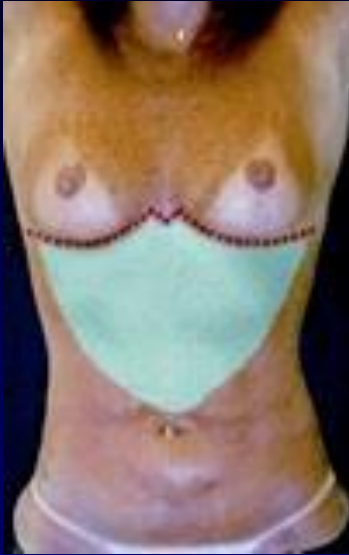
# ABDOMINOPLASTY

## PROCEDURES

1. Liposuction only
2. " + diastasis repair
3. Subumbilical [mini] abdominoplasty
4. Standard [radical, traditional] abdominoplasty
5. Lipo Abdominoplasty
6. High lateral tension abdominoplasty [Lockwood]
7. Modified vertical abdominoplasty [fleur-de-lis]
8. Panniculectomy
9. Circumferential abdominoplasty [bodylift, belt lipectomy ]
10. Reverse [upper] abdominoplasty
11. Other [lipo to other areas, hernia repairs, scar revisions, abdo op's eg hysters, other op's eg thighs, breasts, face.]

# REVERSE [Upper] ABDOMINOPLASTY



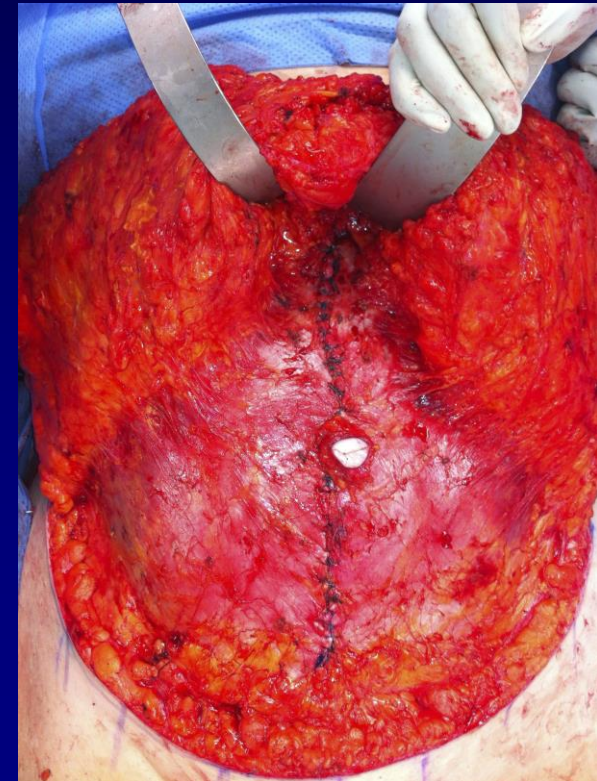
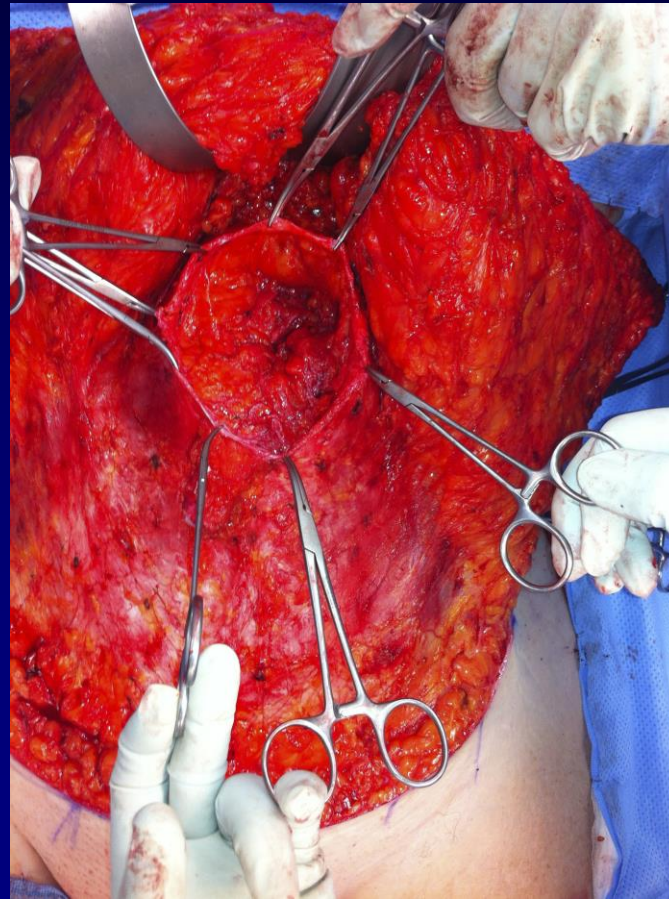
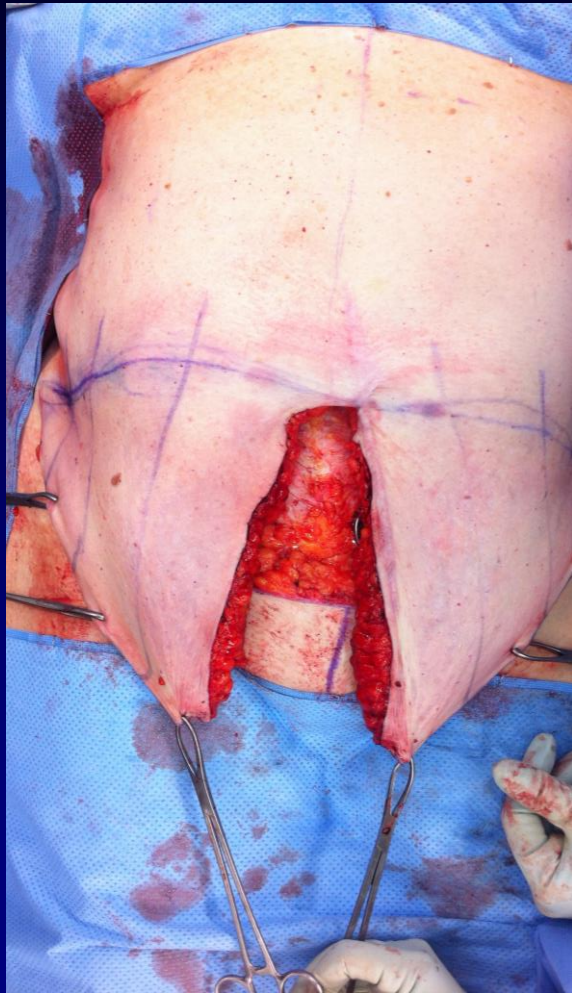


# ABDOMINOPLASTY

## PROCEDURES

1. Liposuction only
2. " + diastasis repair
3. Subumbilical [mini] abdominoplasty
4. Standard [radical, traditional] abdominoplasty
5. Lipo Abdominoplasty
6. High lateral tension abdominoplasty [Lockwood]
7. Modified vertical abdominoplasty [fleur-de-lis]
8. Panniculectomy
9. Circumferential abdominoplasty [bodylift, belt lipectomy ]
10. Reverse [upper] abdominoplasty
11. Other [lipo to other areas, hernia repairs, scar revisions, abdo op's eg hysters, other op's eg thighs, breasts, face.]

# INCISIONAL HERNIA & ABDOMINOPLASTY



# ABDOMINOPLASTY

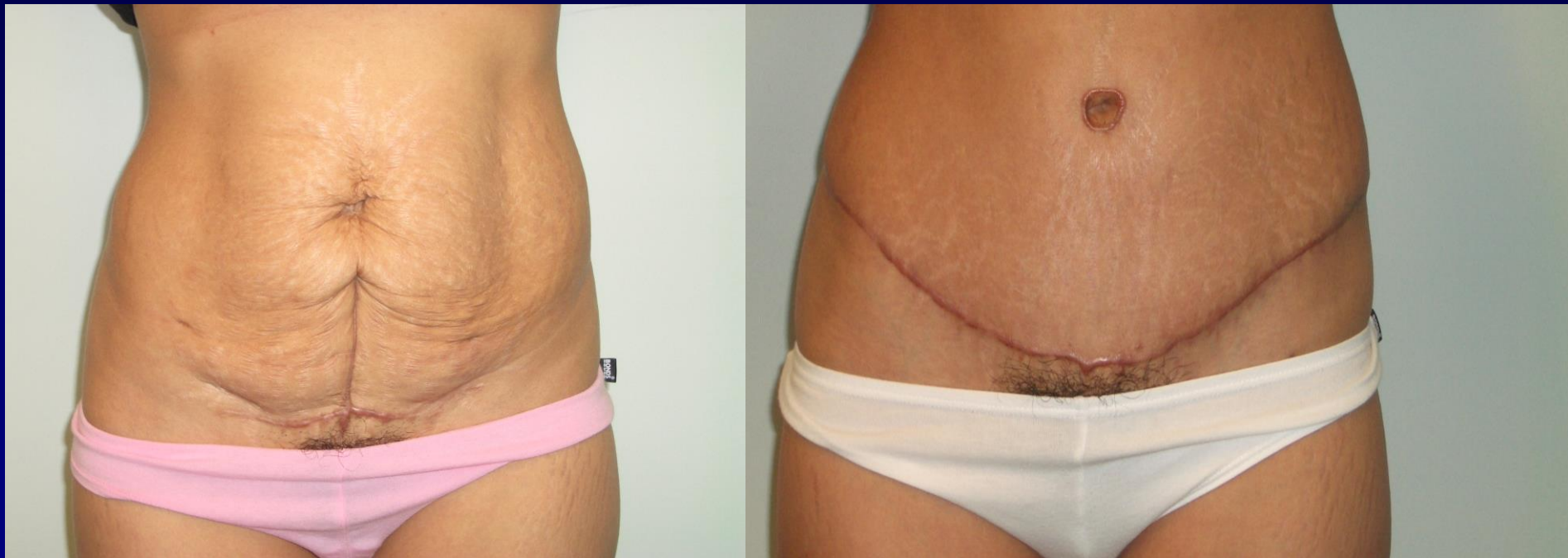## Complications

1. Seroma
2. Haematoma
3. Infection
4. Wound dehiscence
5. Skin & fat necrosis
6. Suprapubic hypoaesthesia
7. Injury to LCNT
8. Umbilical necrosis
9. Umbilical malposition
10. Pulling up of genitalia
11. Scars
12. Dogs ears
13. DVT/PE

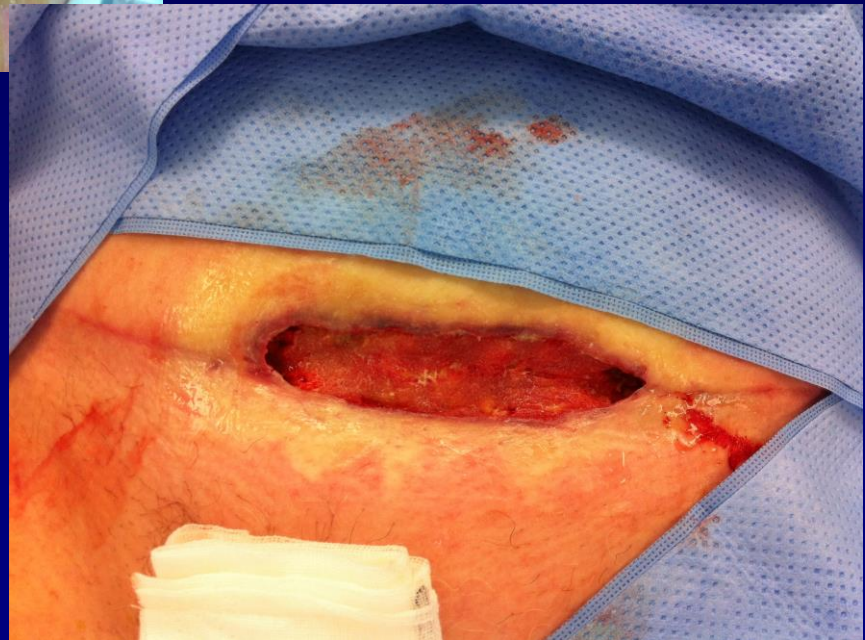
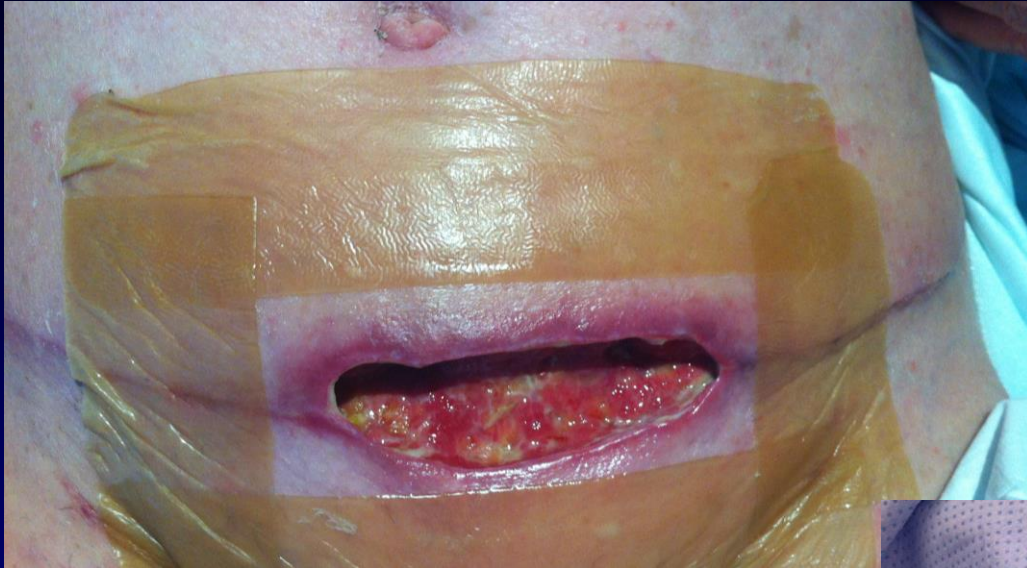
# STANDARD ABDOMINOPLASTY

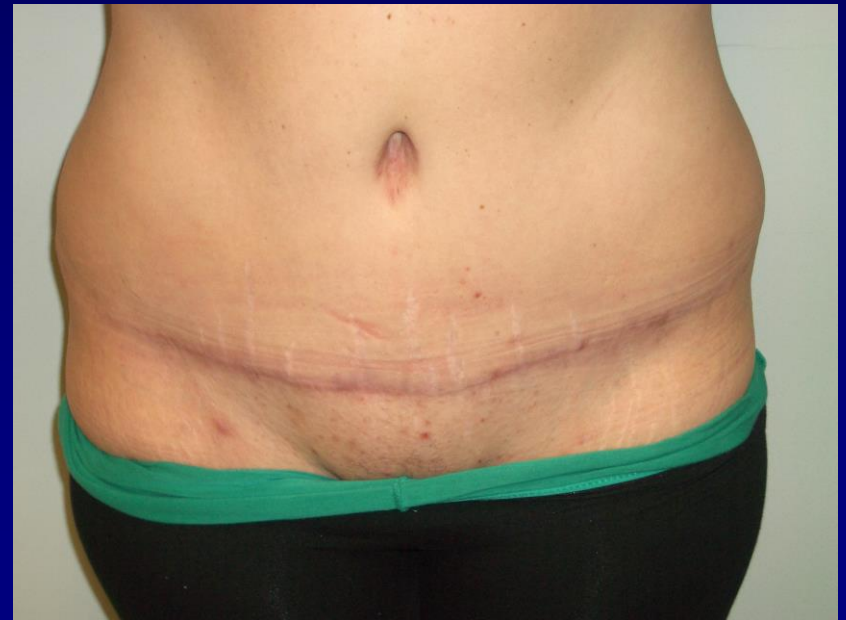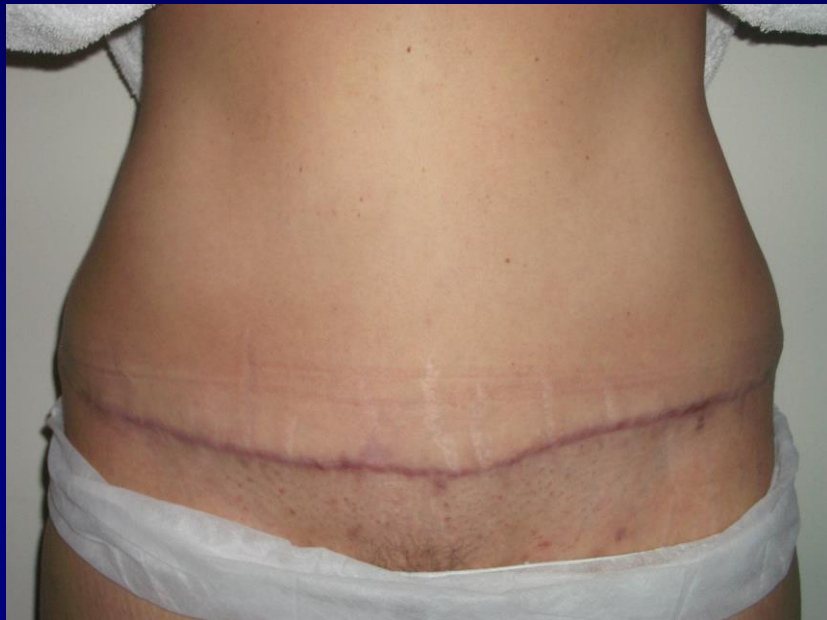
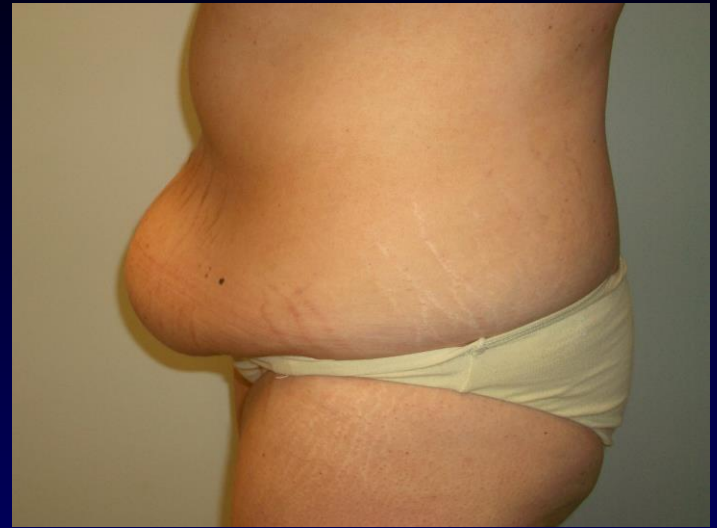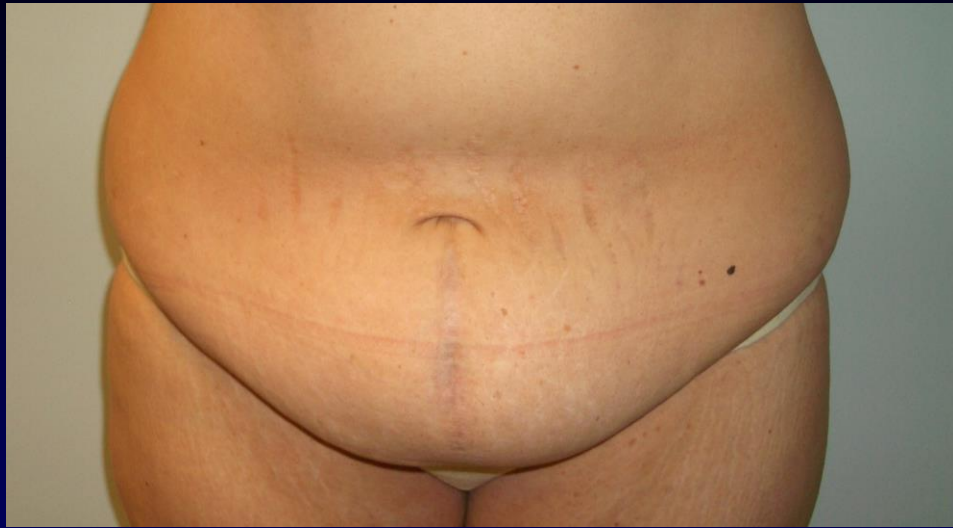## Hypertrophic scars



# Necrosis after Lipo abdominoplasty



# PREVIOUS UMBILICAL HERNIA REPAIR







Rotto

Cottesloe



# MASTOPEXY

Chris Allen

March 2014







# Pathogenesis

- Stretched collagen [skin & ligaments]
- Involution of gland

# Causes

1. Mammary hypertrophy
1. Changes in weight [obesity & wt loss]
1. Post partum
1. Post menopausal
1. Tuberous breasts

# Classification

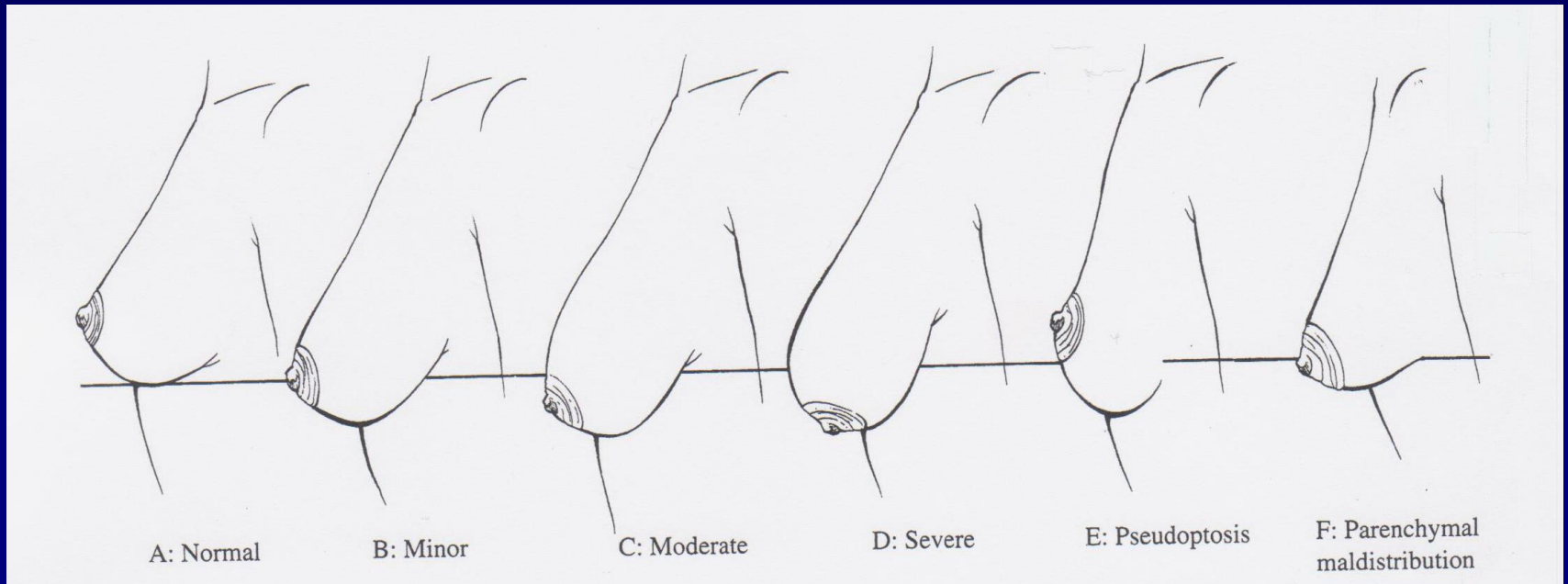
- Regnault ptosis grading scale [ nipple position ]

Grade I mild ptosis --at IMF

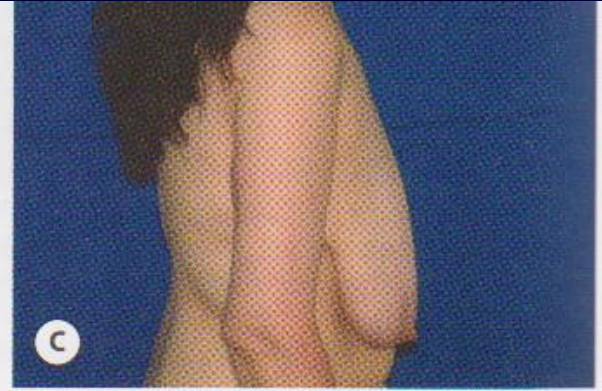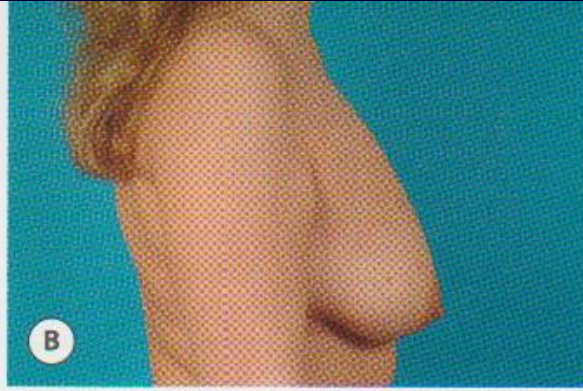
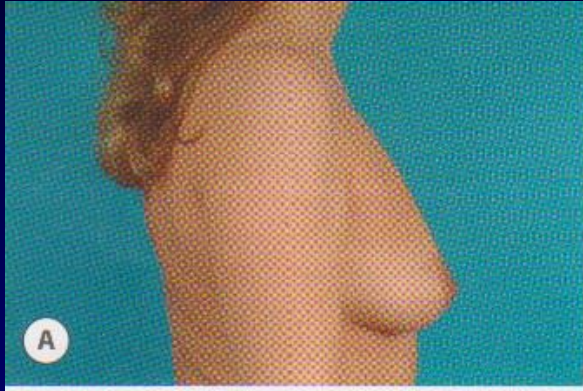Grade II moderate ptosis --below IMF, above lowest contour

Grade III severe ptosis --below IMF, at lowest contour

Pseudoptosis --nipple above but gland below IMF







# Options

1. Augment with implant [grade I ptosis]
1. Mastopexy + implant
1. Mastopexy + small reduction
1. Mastopexy only

# Surgical considerations

1. Scar .... minimise
2. Shape .... improve
3. Upper pole .... fullness [implant or re-shaping]
4. Longevity ....sustainable results



# Surgical Techniques

1. Skin Resection

2. Glandular Reshaping

# 1. Skin Resection

1. Crescent Mastopexy

1. Circumareolar Mastopexy [periareolar, donut]

[a] Benelli

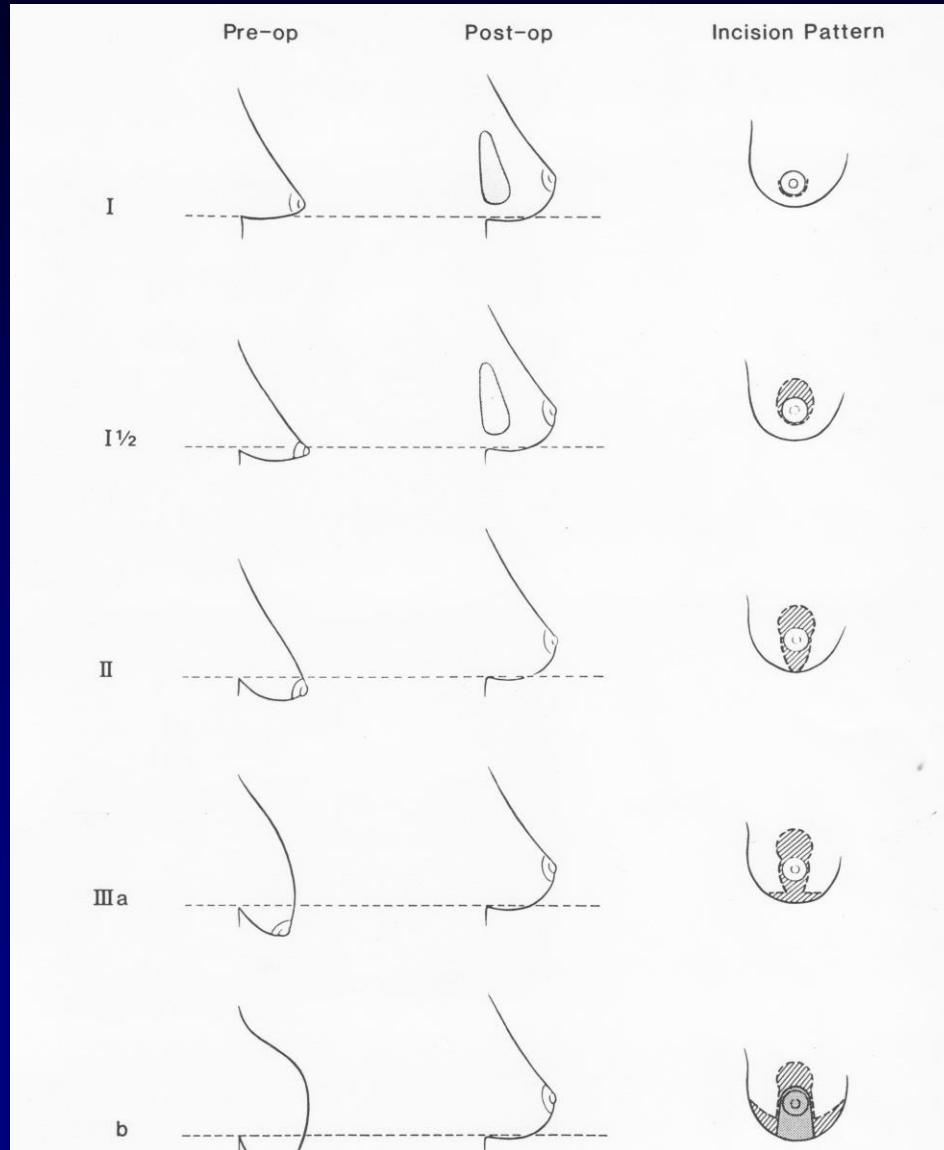
[b] Goes [mesh]

3. Circumvertical Mastopexy [short scar, lollipop]

4. Inverted-T mastopexy [anchor]

# Skin incisions

Ptosis  
grade



augment only

circum areolar +  
implant

circum vertical

inverted – T [short]

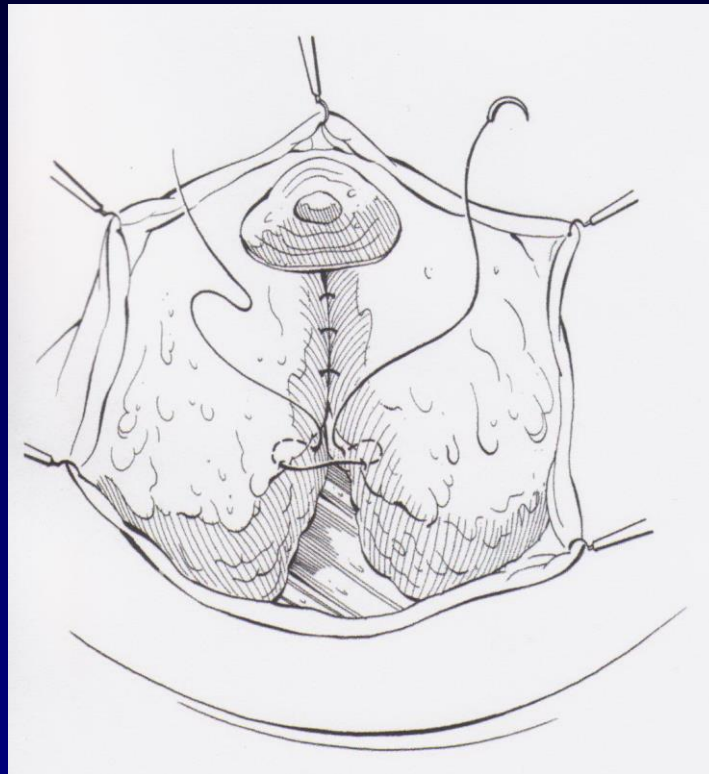
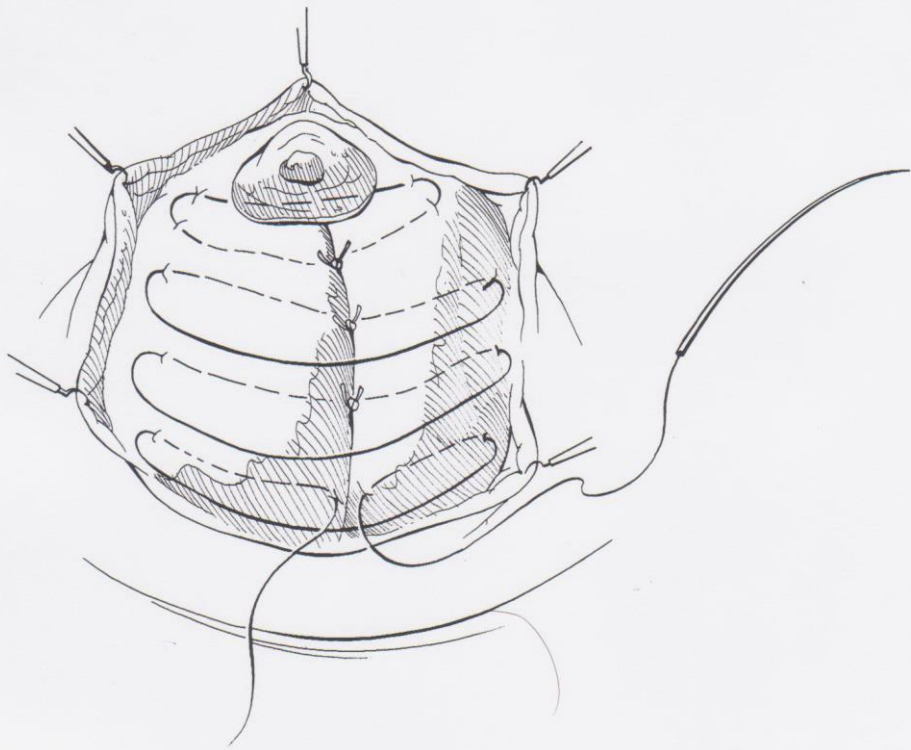
inverted – T [wise]



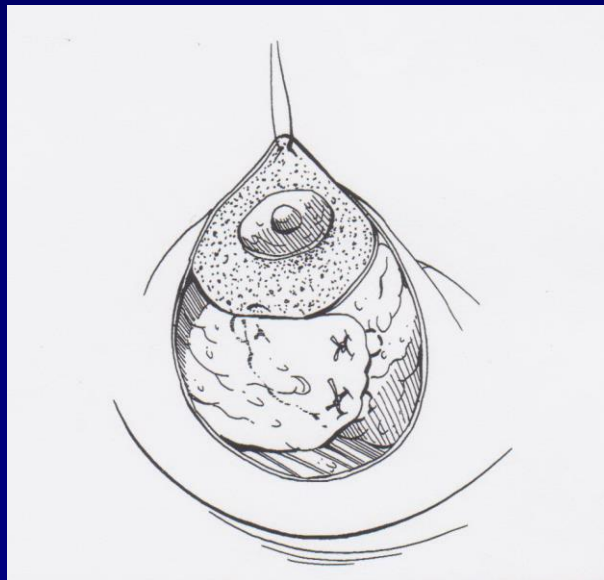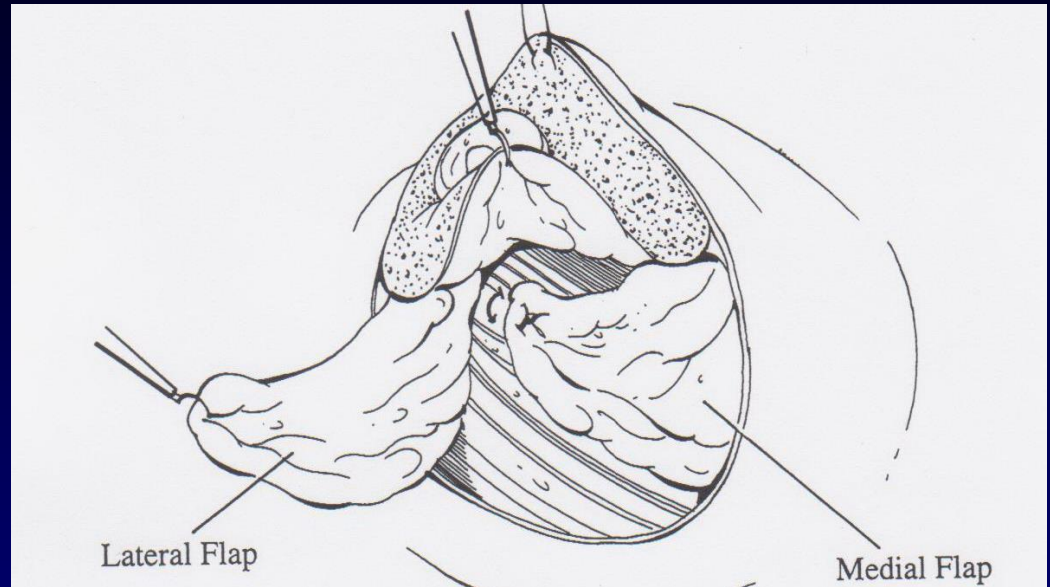
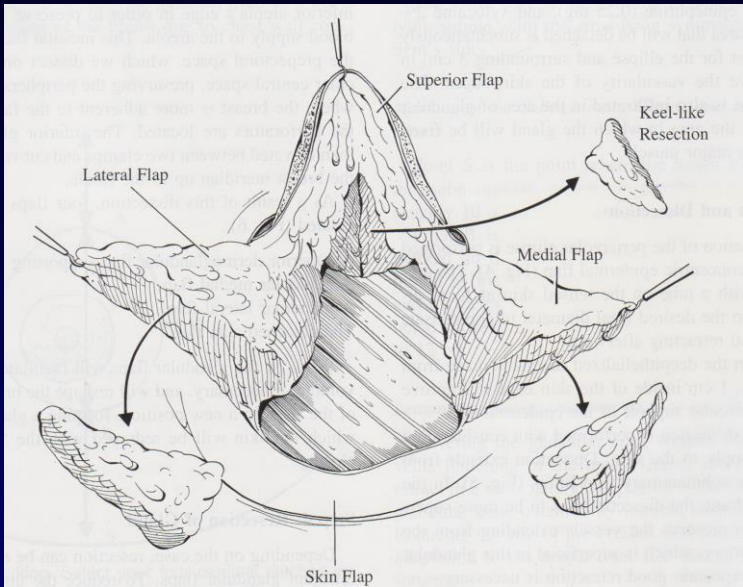
## 2. Glandular Reshaping

1. Suture invagination & plication
2. Medial & lateral criss cross flaps [Bennelli]
3. Mesh [Goes]
4. Inferiorly based central flap [Graf, Ritz ]
5. Inferior pedicle [SPAIR-Hammond]
6. Upper pole “auto-augmentation” [Le Jour, Hammond ]

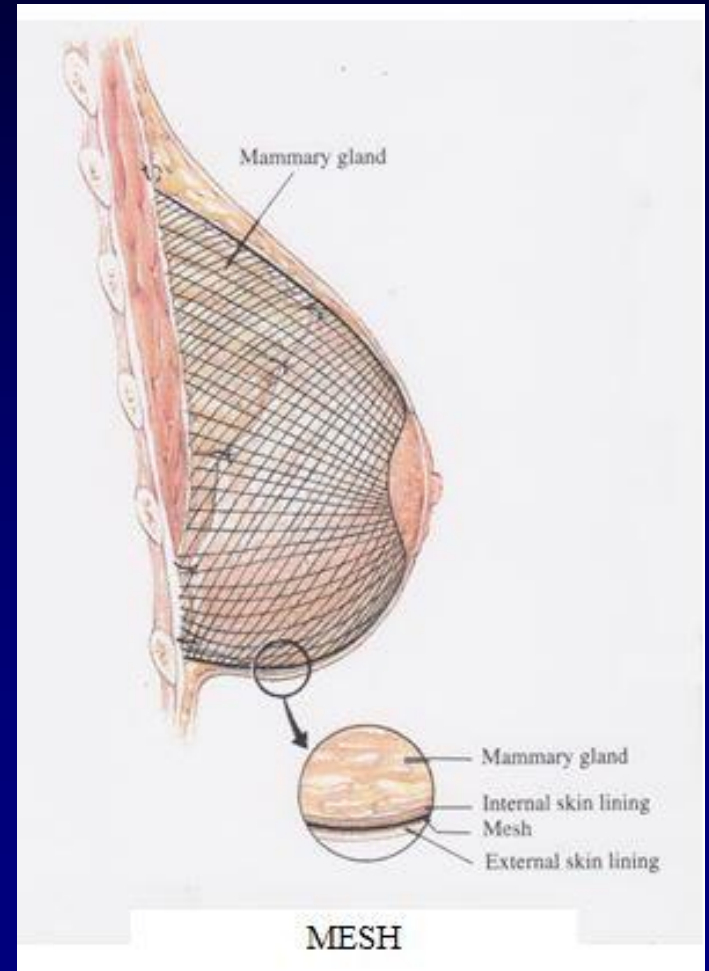
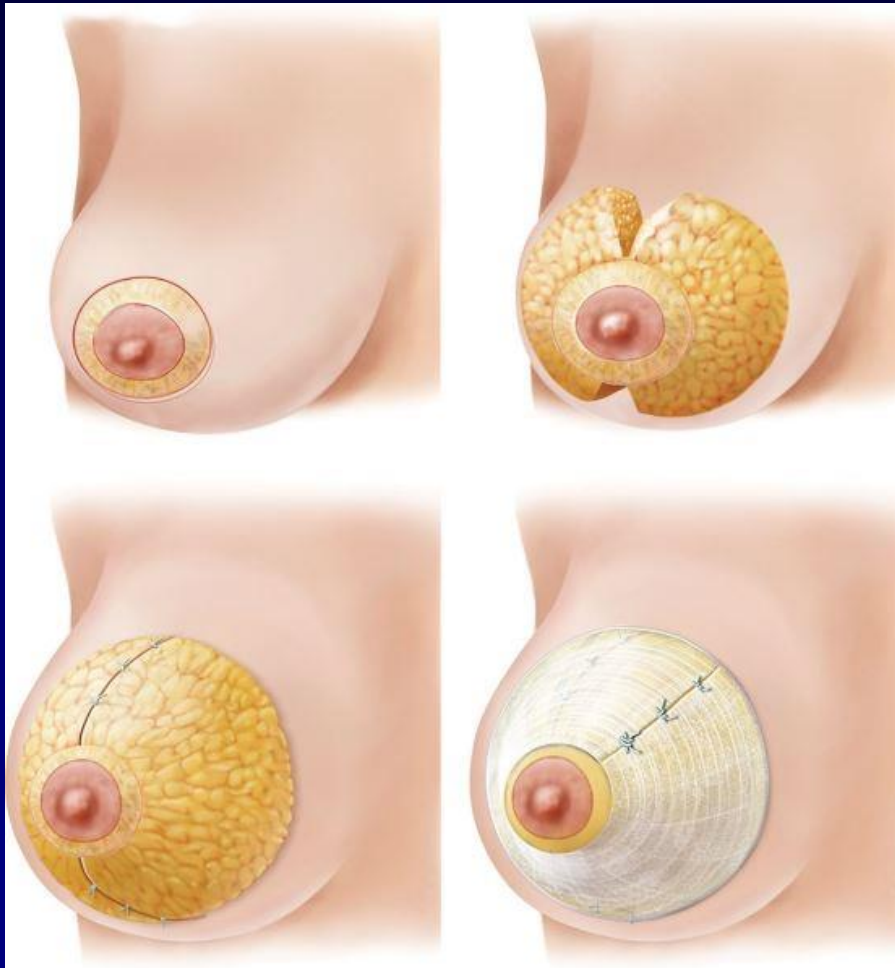
# Plication invagination



# Medial & lateral criss cross flaps

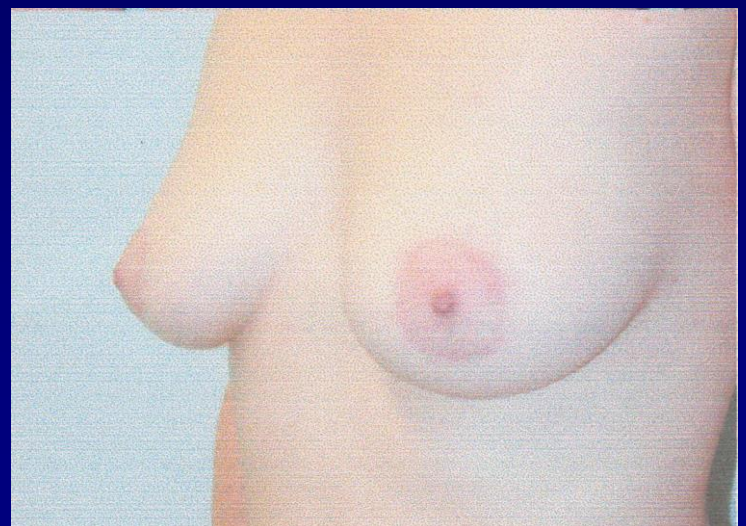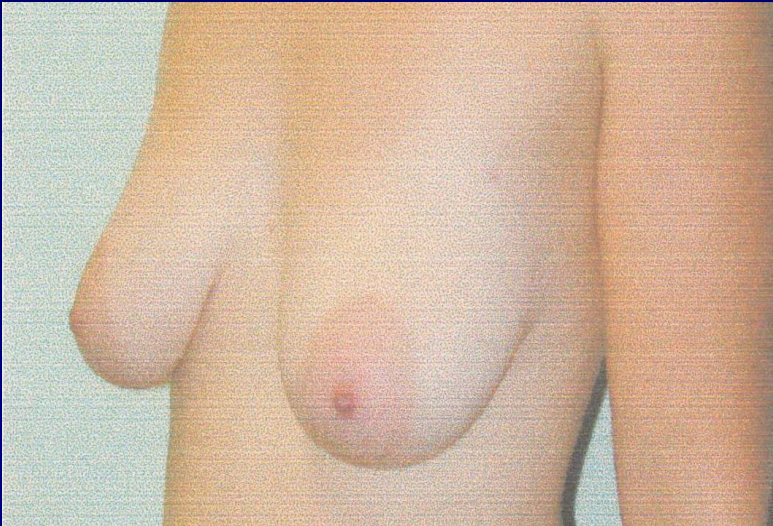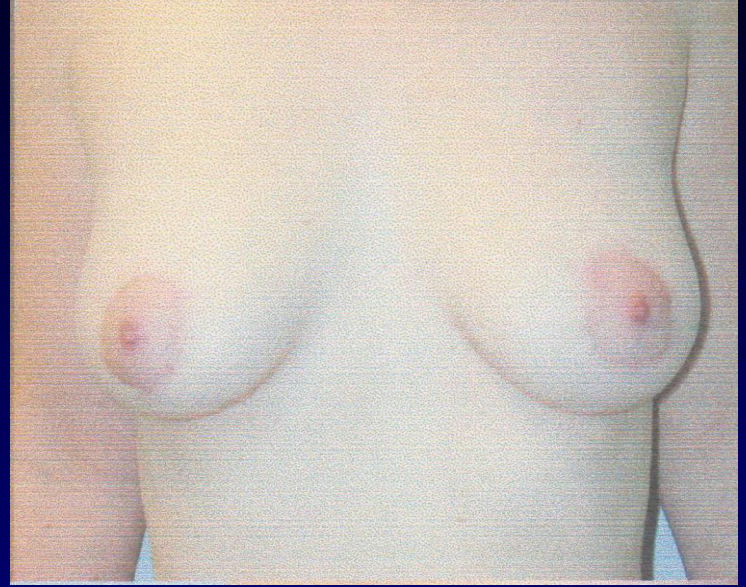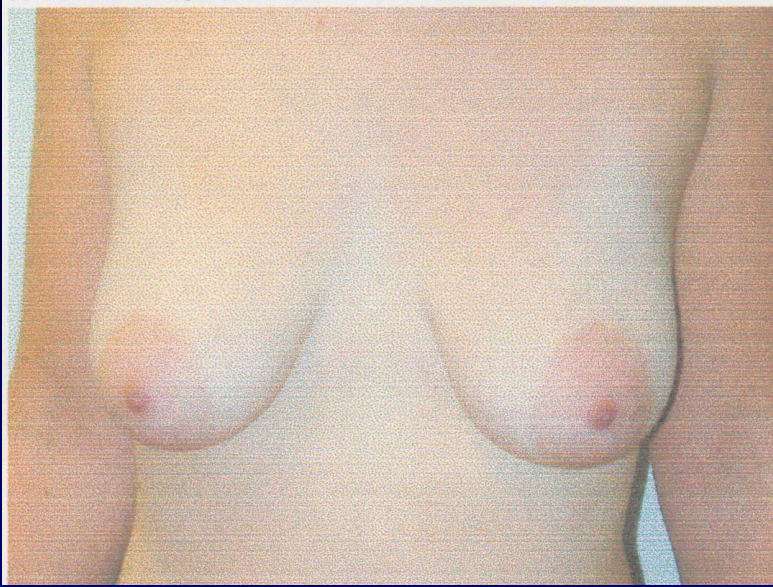


# Circumareolar with mesh [Goes]



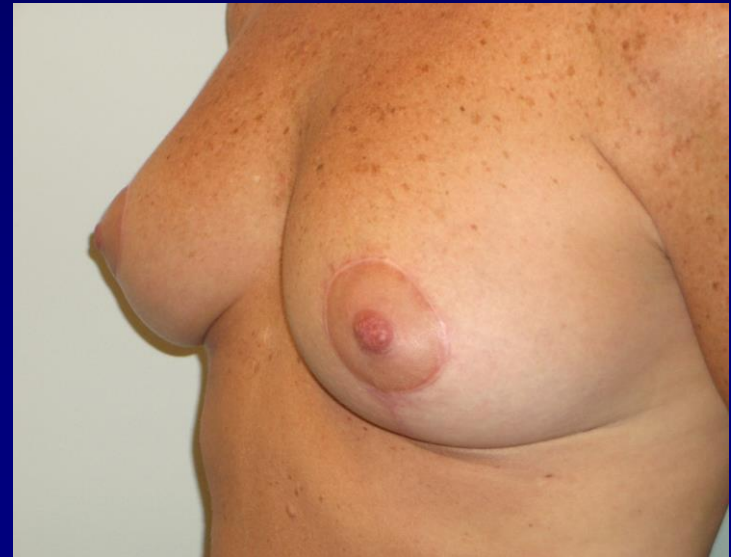
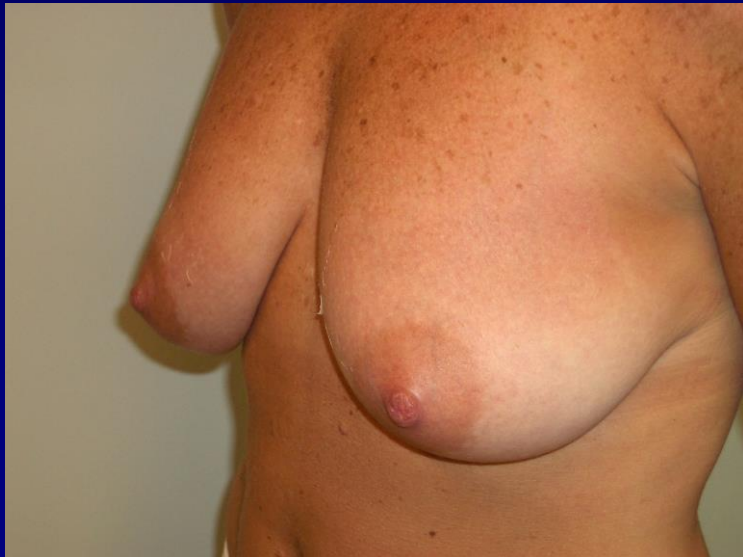
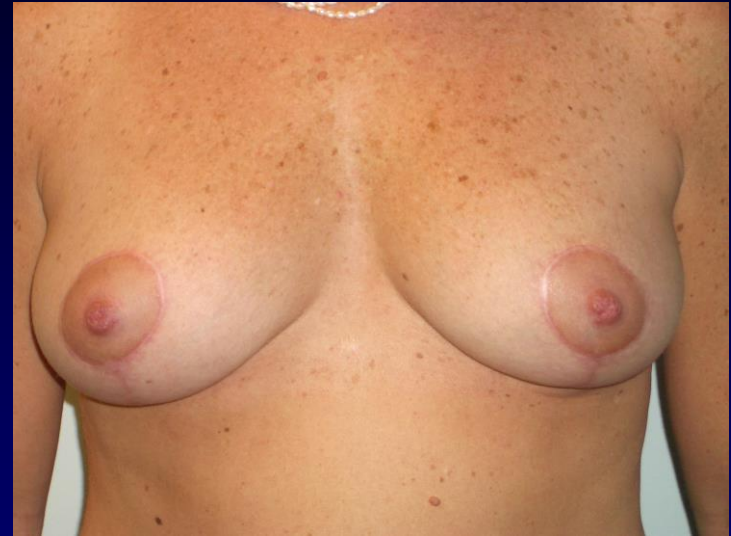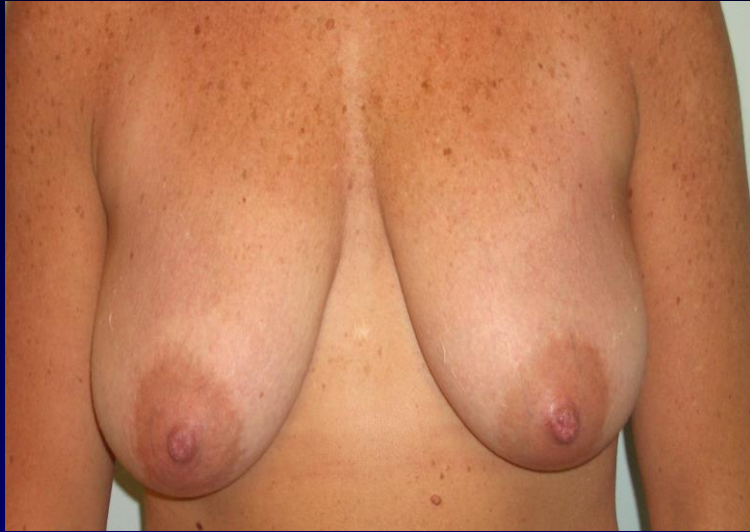# Periareolar mastopexy with mesh

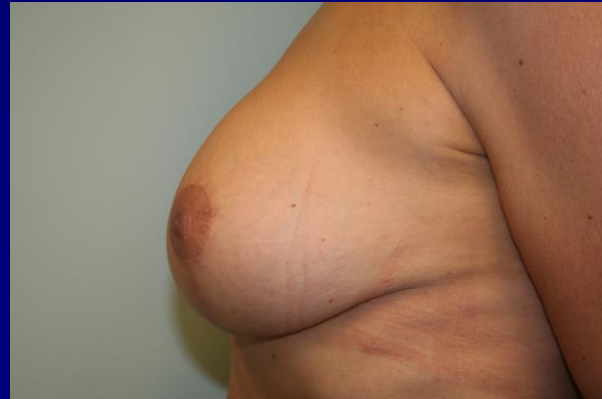
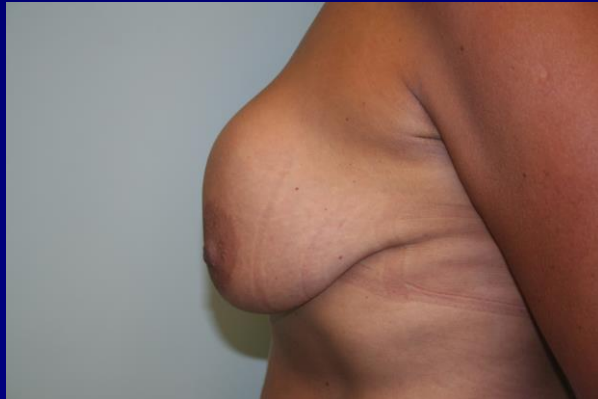
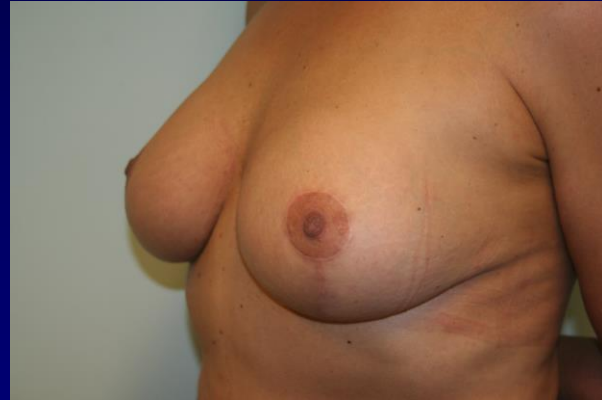
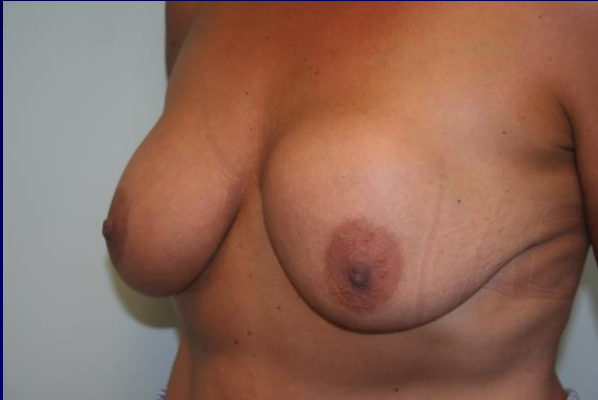
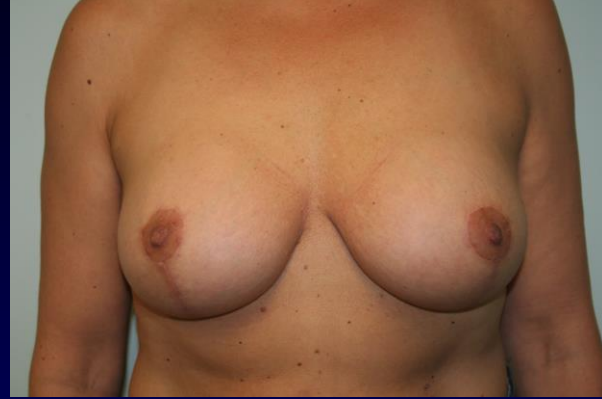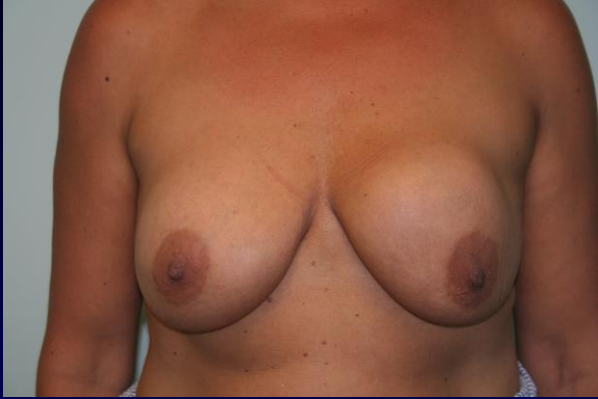# Circumvertical mastopexy



# Inverted -T mastopexy [ previous augmentation ]



# Mastopexy

Inferior pedicle central flap & autoaugmentation

Skin envelope

circumvertical with J, L, or T pattern

Glandular Reshaping

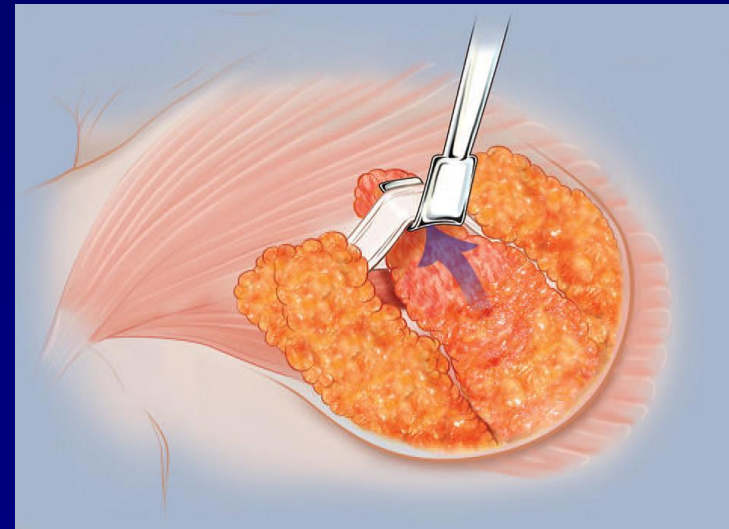
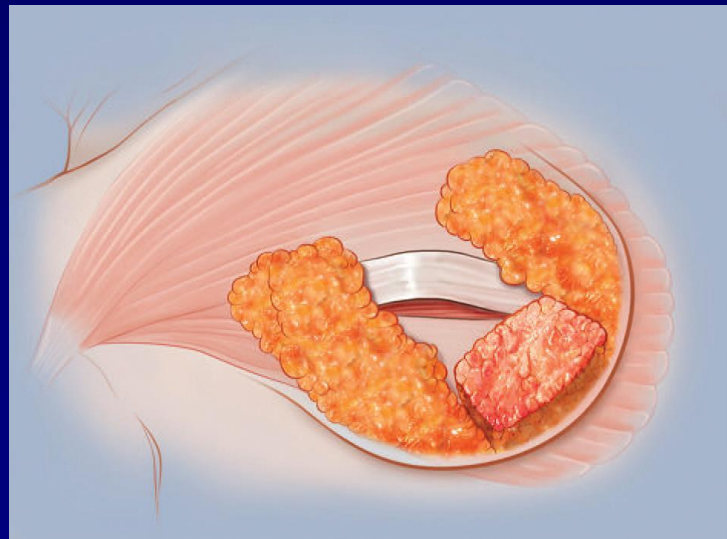
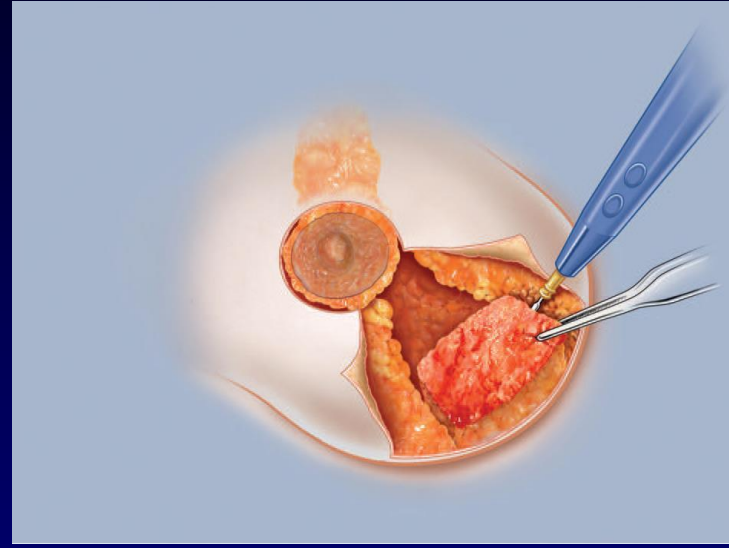
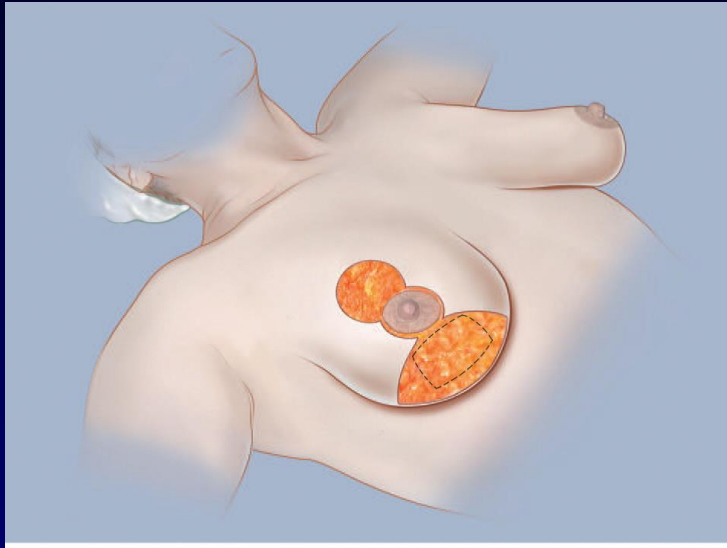
1. inf pedicle central flap [Graf]

+

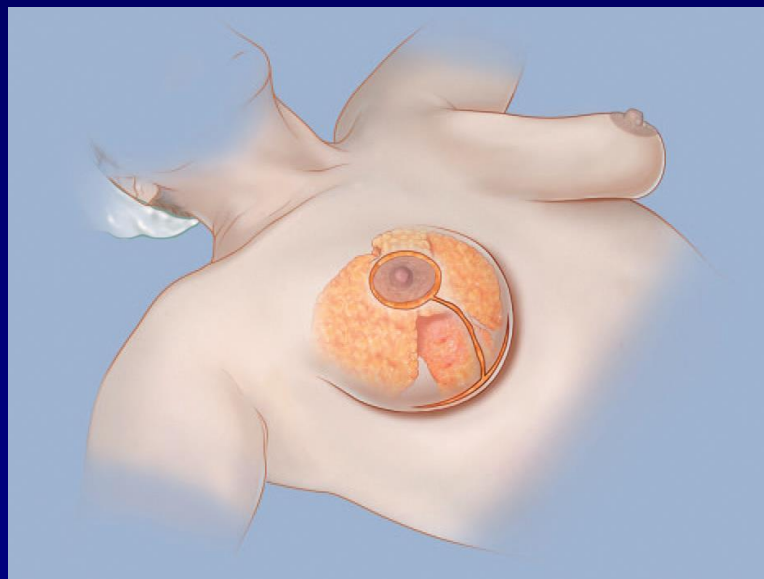
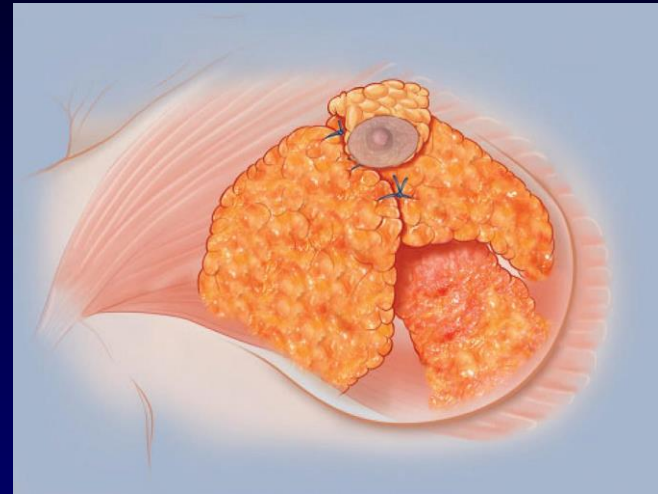
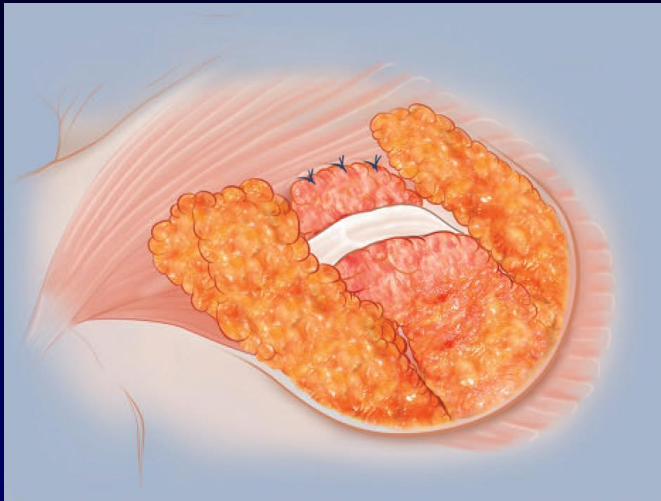
2. upper pole autoaugmentation



# Inferior pedicle central flap



# Inferior pedicle central flap



# Mastopexy

## Markings

Midline

Breast meridian

IMF

New top of areola at IMF

Lateral displacement of breast

Medial           “           “           “

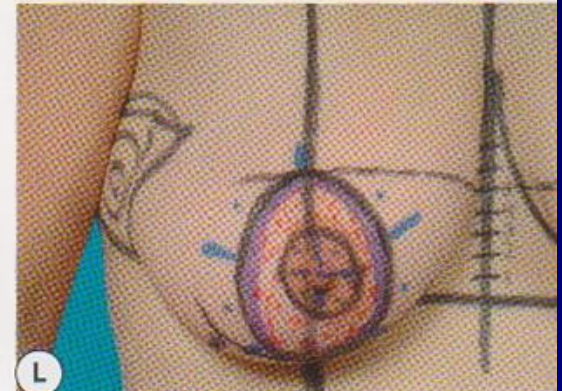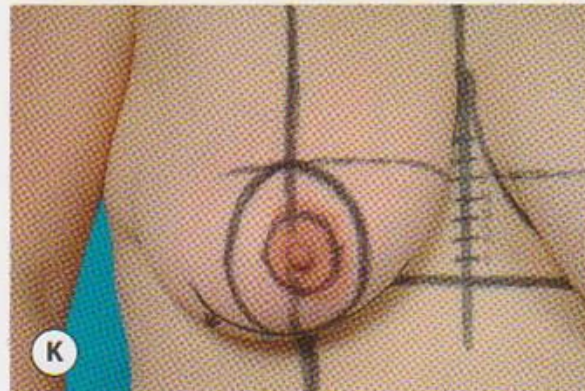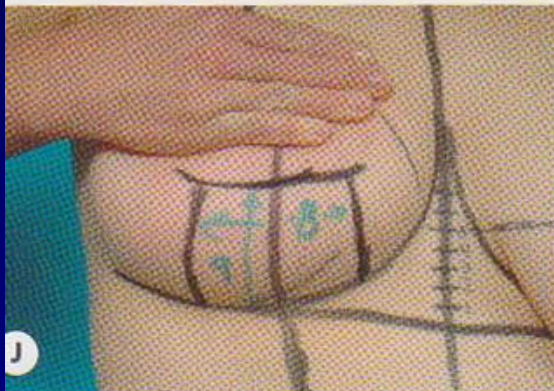
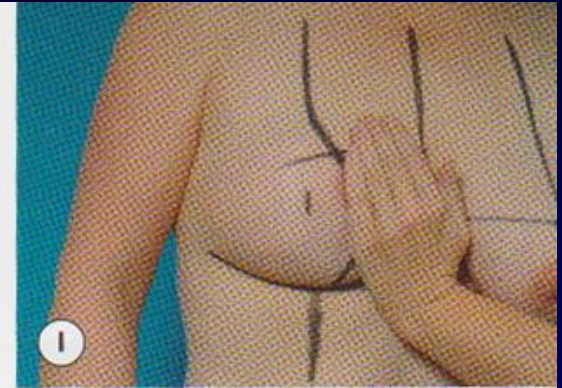
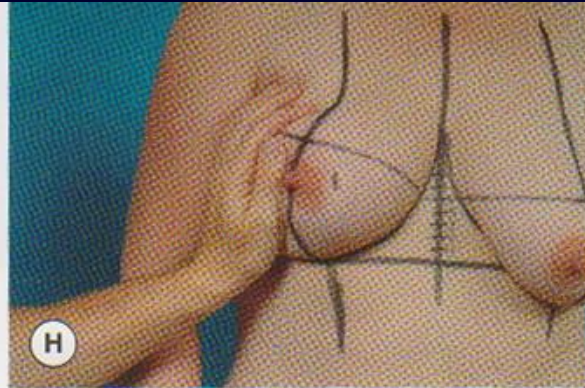
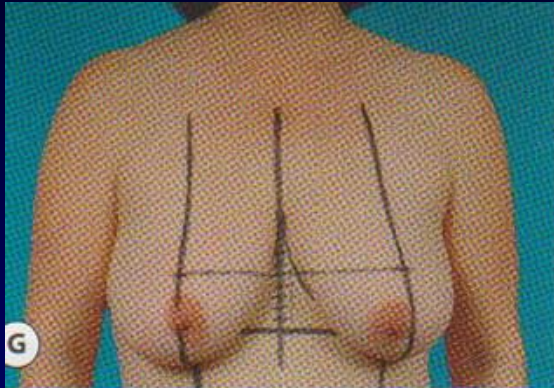
Mark new areola

Mark new IMF [ 2-4 cm above old IMF ]

Mark inf flap [ 5 by 5 cm ] -2cm below areola & 2cm above old IMF



# Markings





# Mastopexy

## Technique

Deepith around areola & flap

Incise & mobilise flap

Undermine beneath NAC superiorly

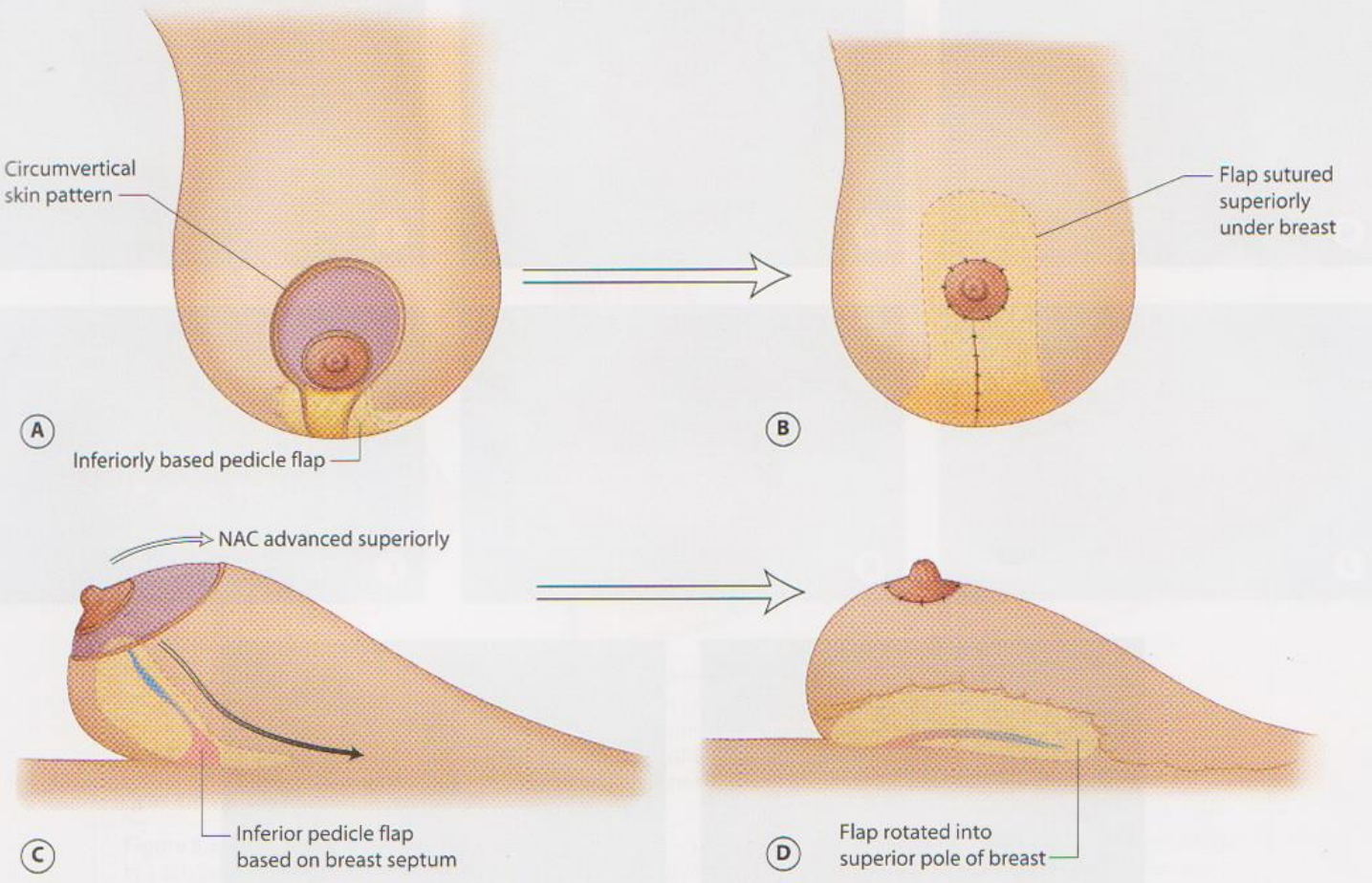
Advance & fix flap superiorly to Pec fascia

Autoaugment

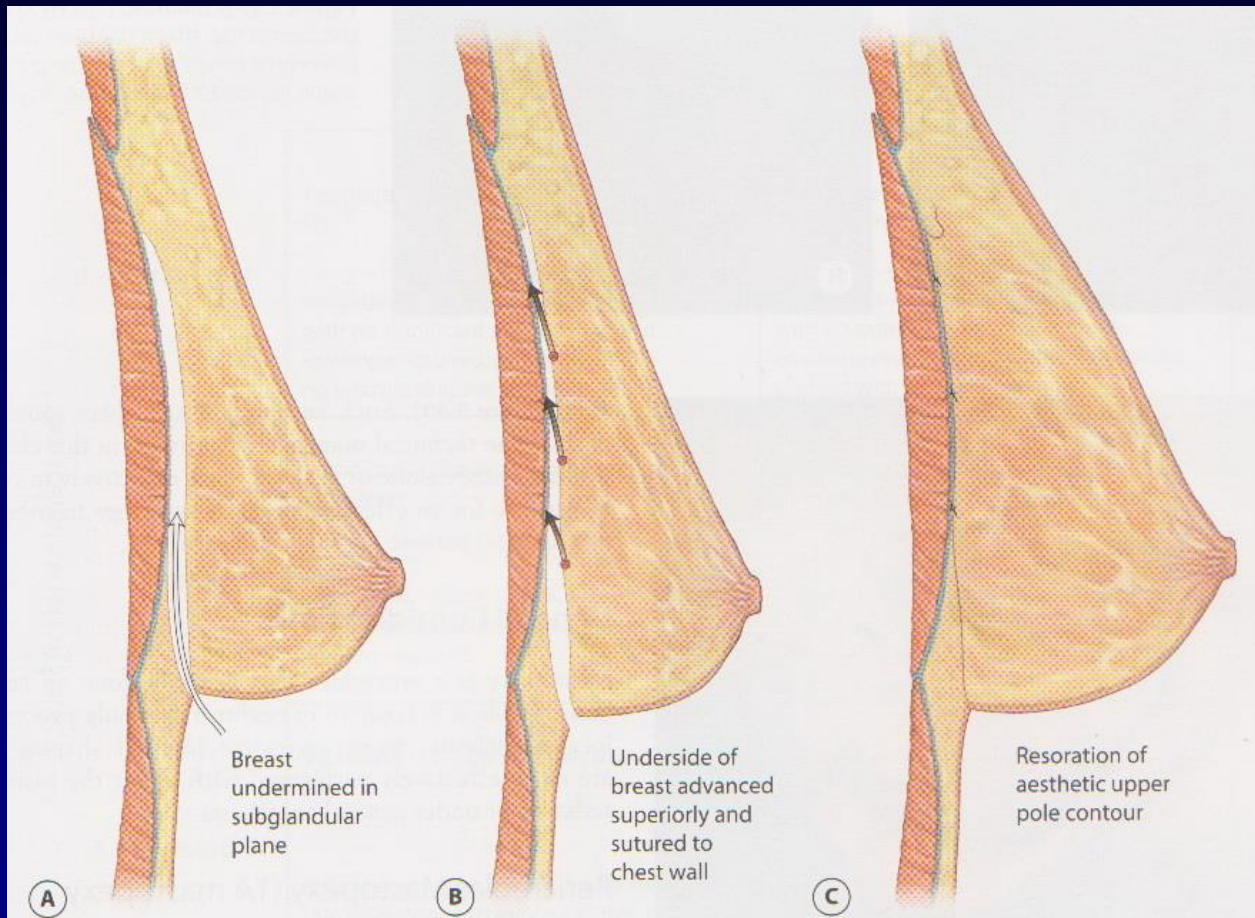
Suture medial & lateral pillars

Round block suture

# Inferior flap



# Autoaugmentation of superior pole

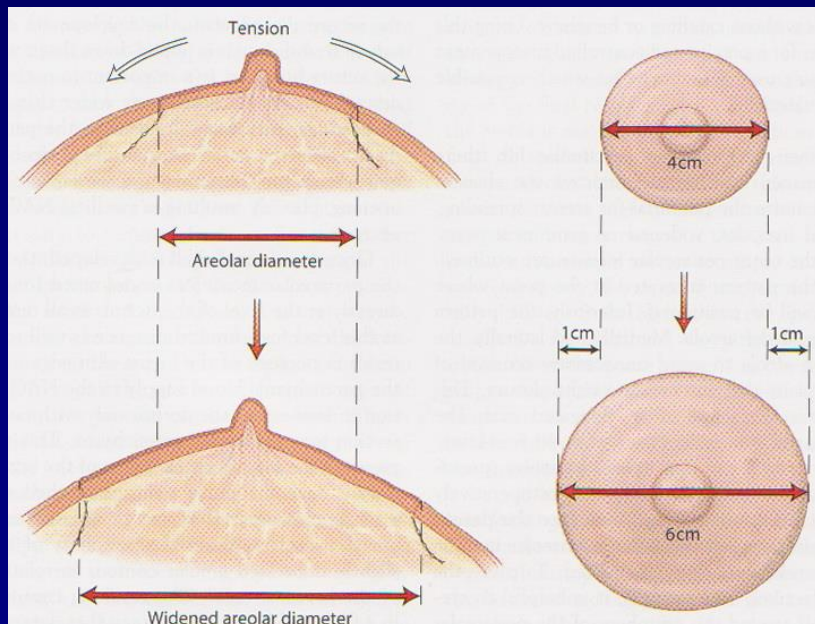




# Round block suture

1. Purse string [ Benelli ]

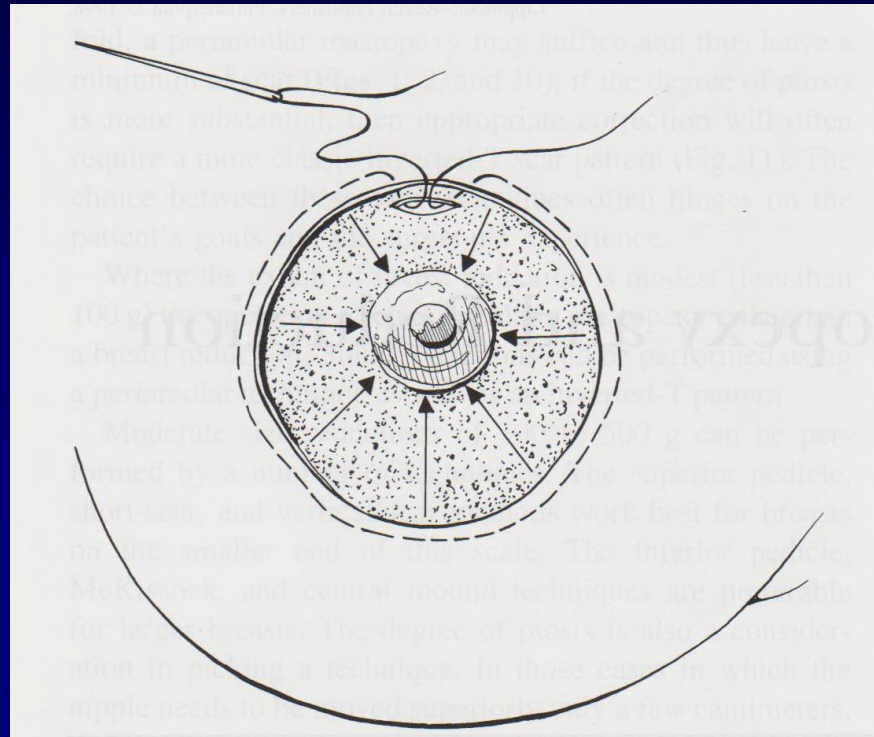
2. Wagon or pin wheel [ Hammond ]



# Round block suture

Purse string

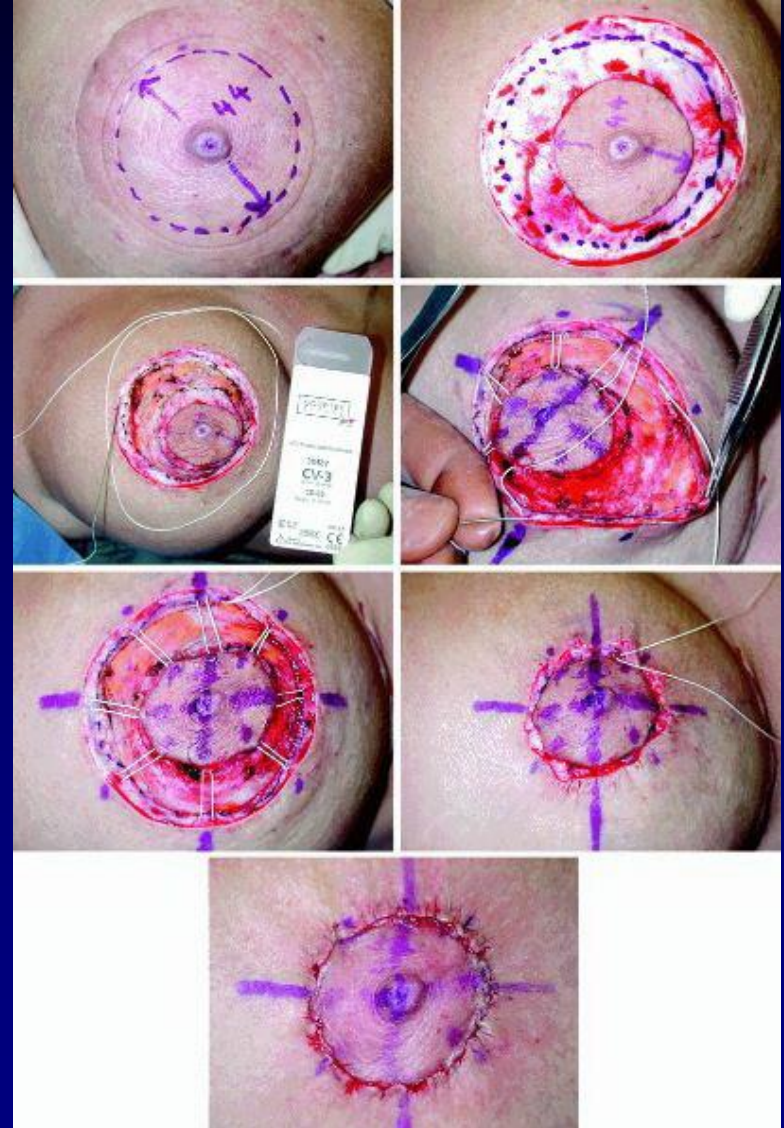
[ Benelli ]



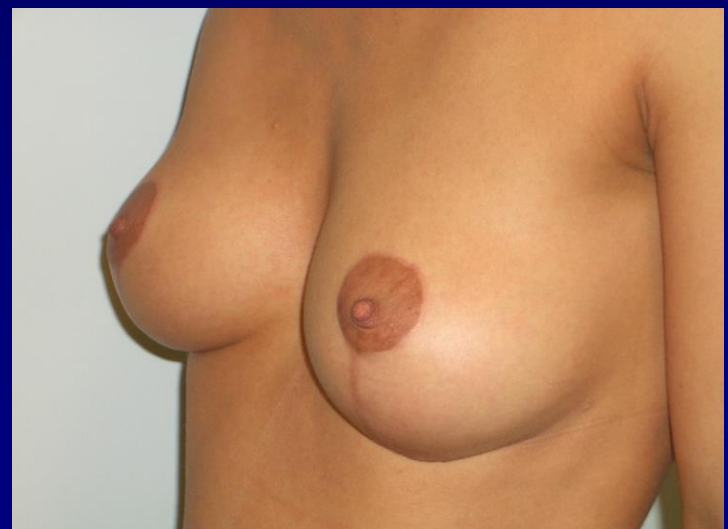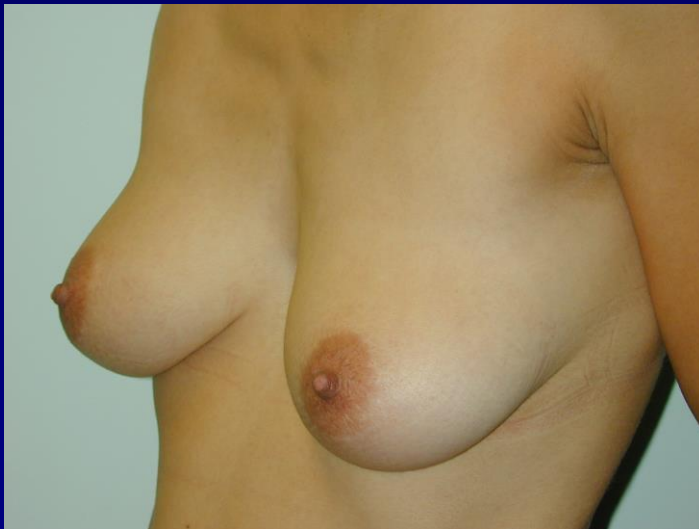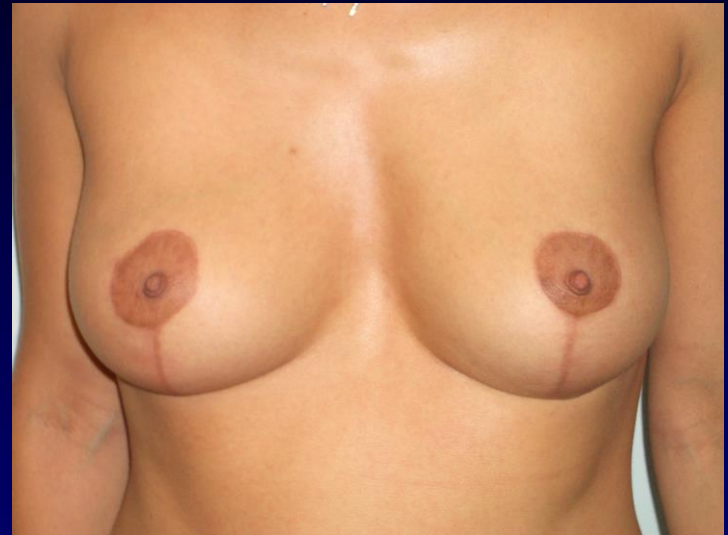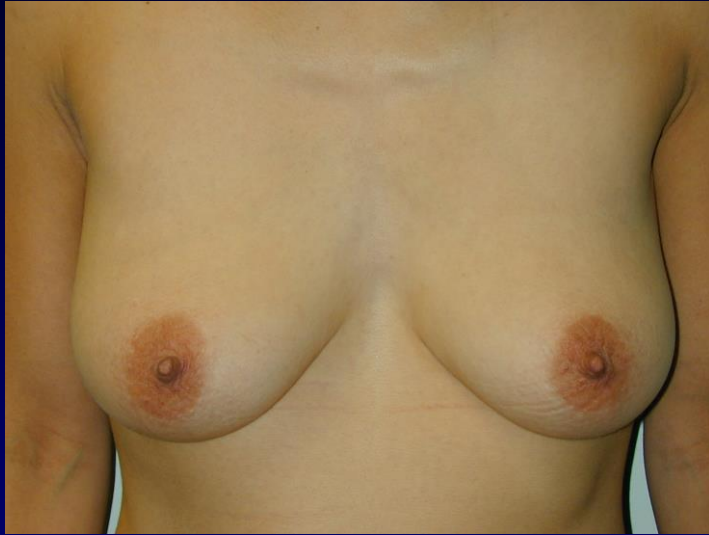# Round block suture

Wagon or pin wheel

[ Hammond ]

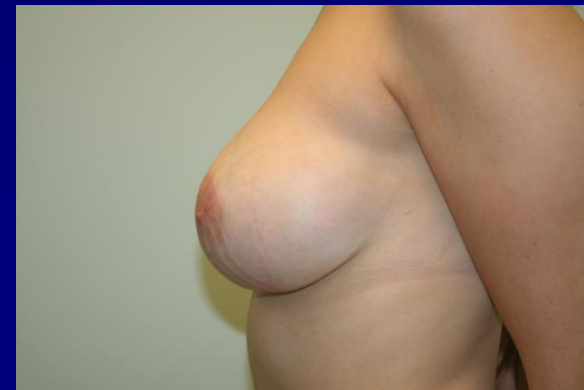
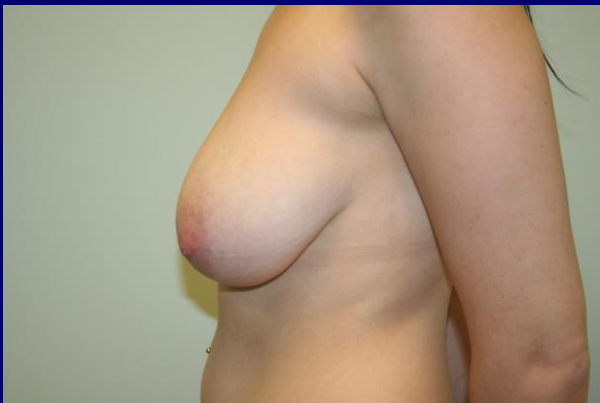
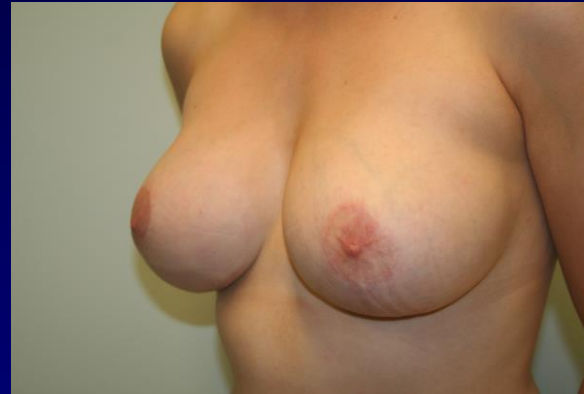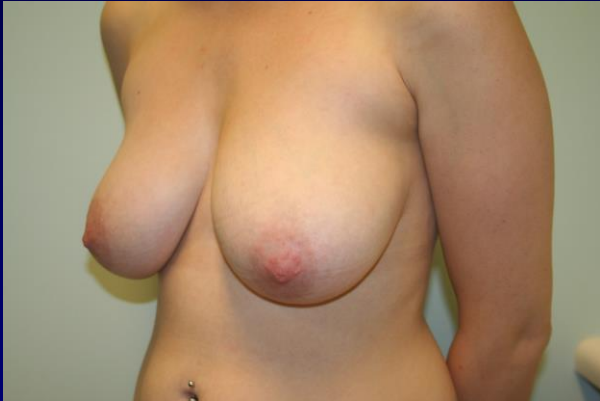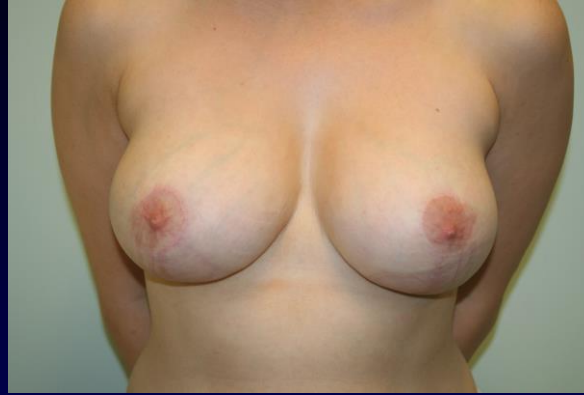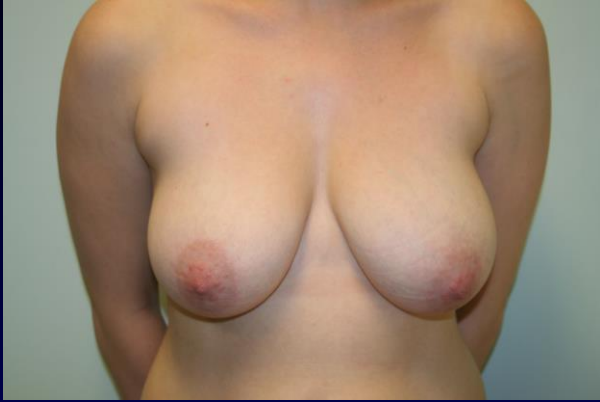# Circumvertical with inferior central flap [Graf]

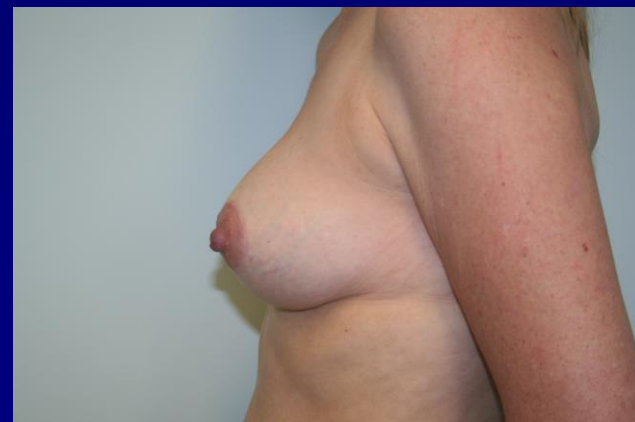
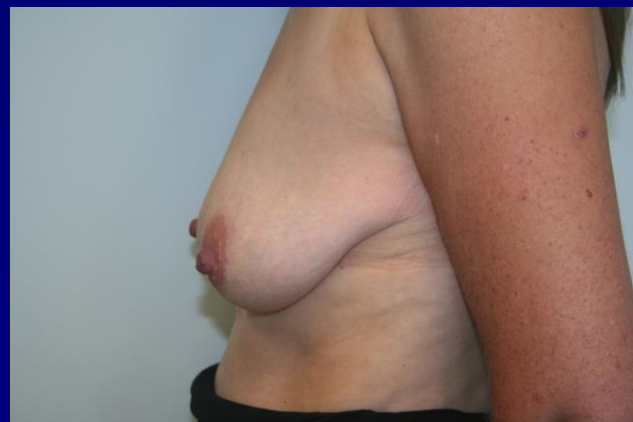
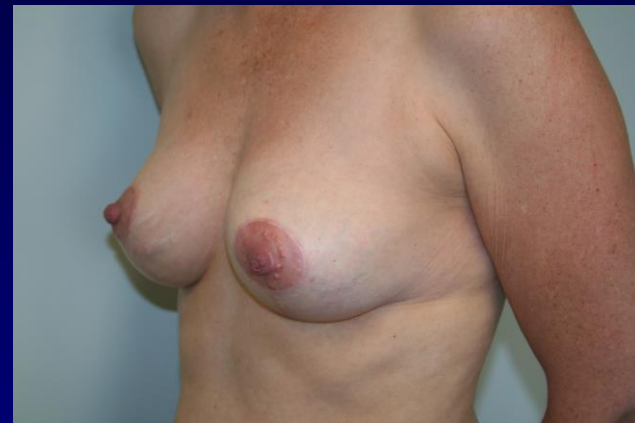
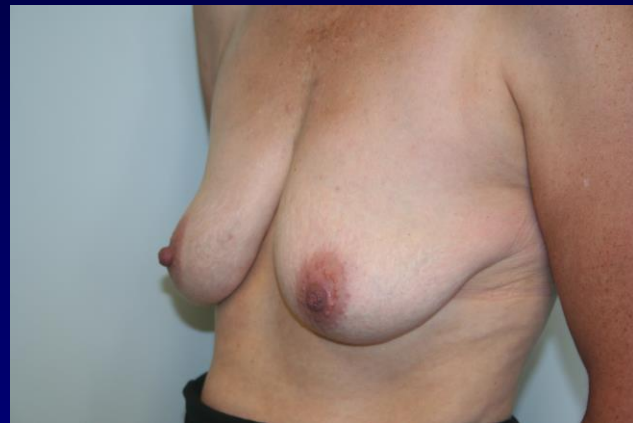
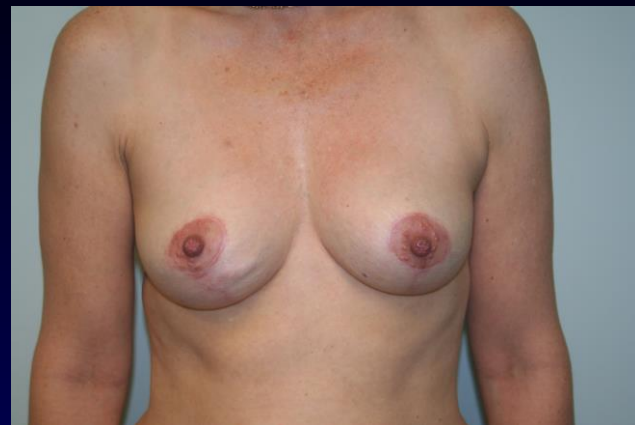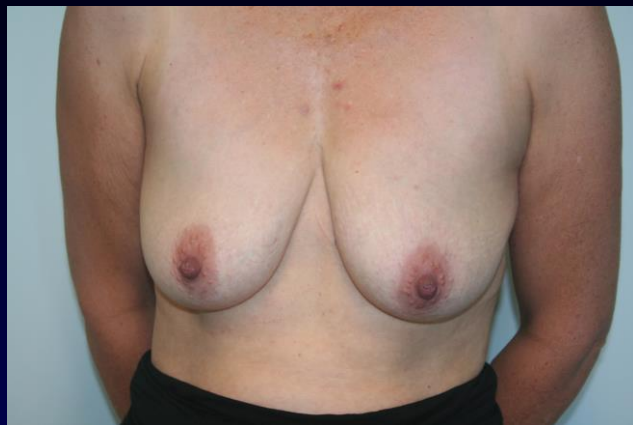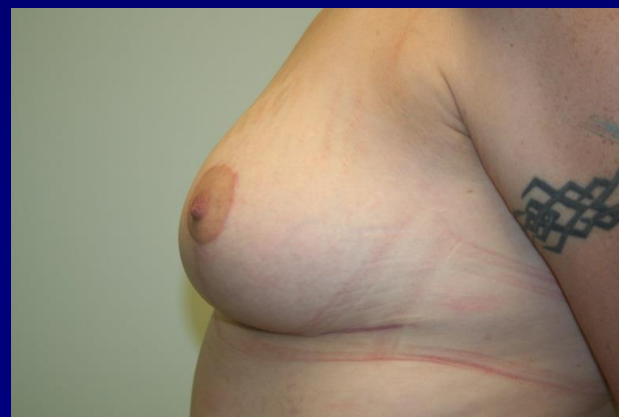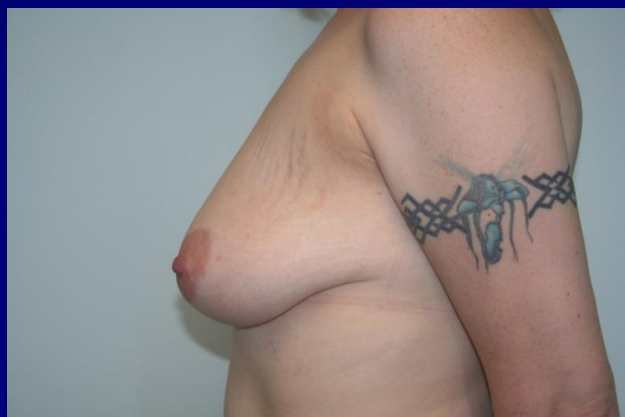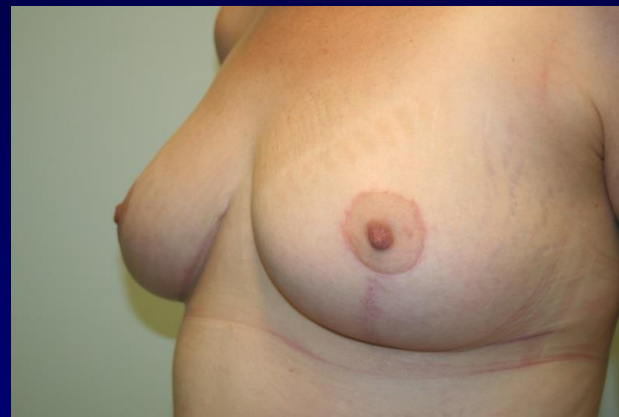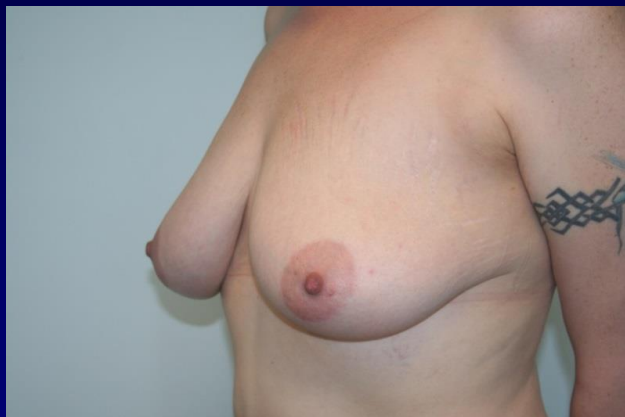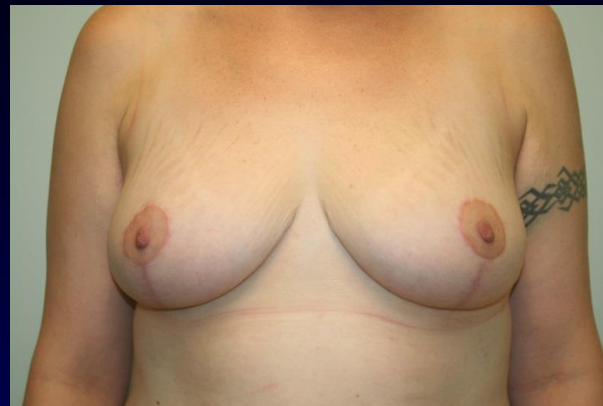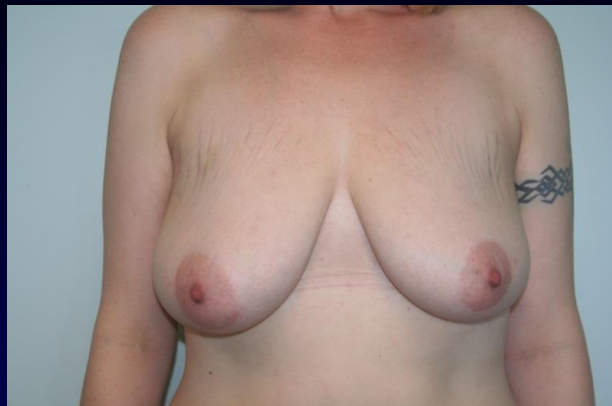# Circumvertical with inf central flap [Graf]



# Circumvert with inf flap ]Graf] & auto augment

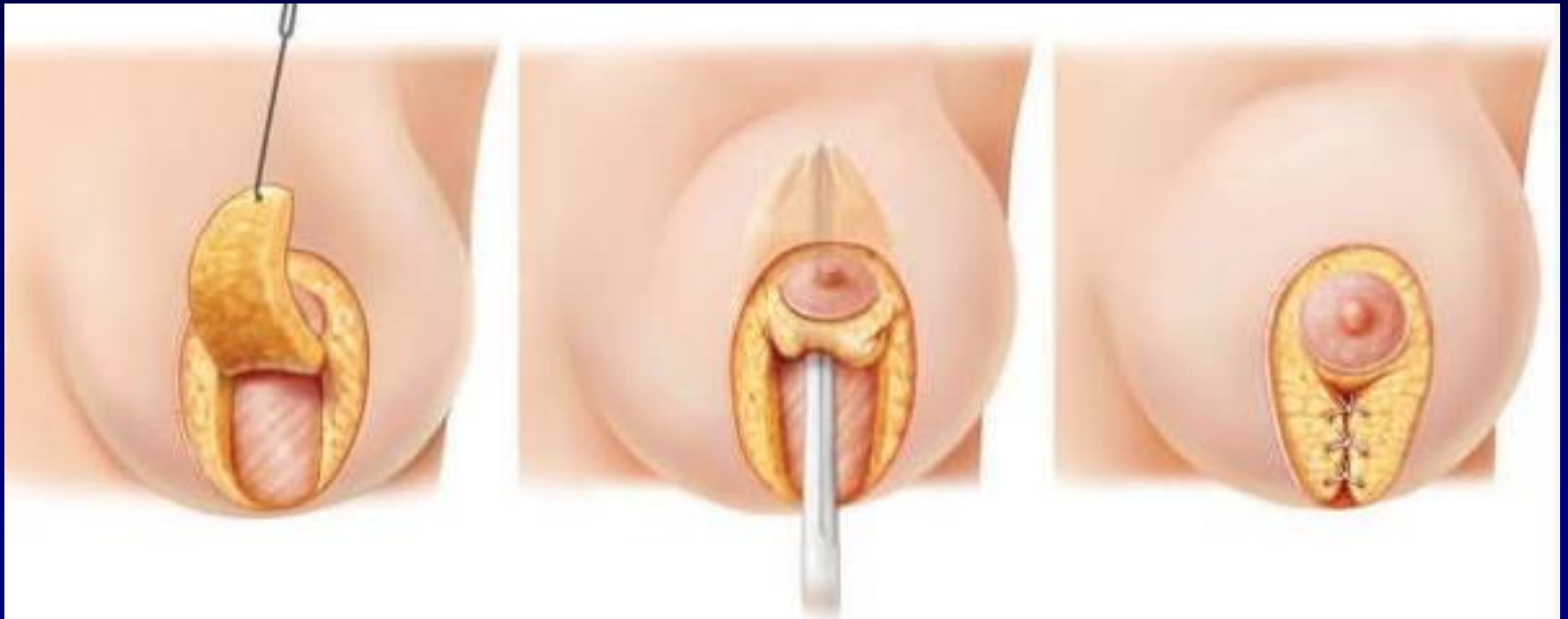


# Circumvertical with inf flap [Graf] & autoaugment



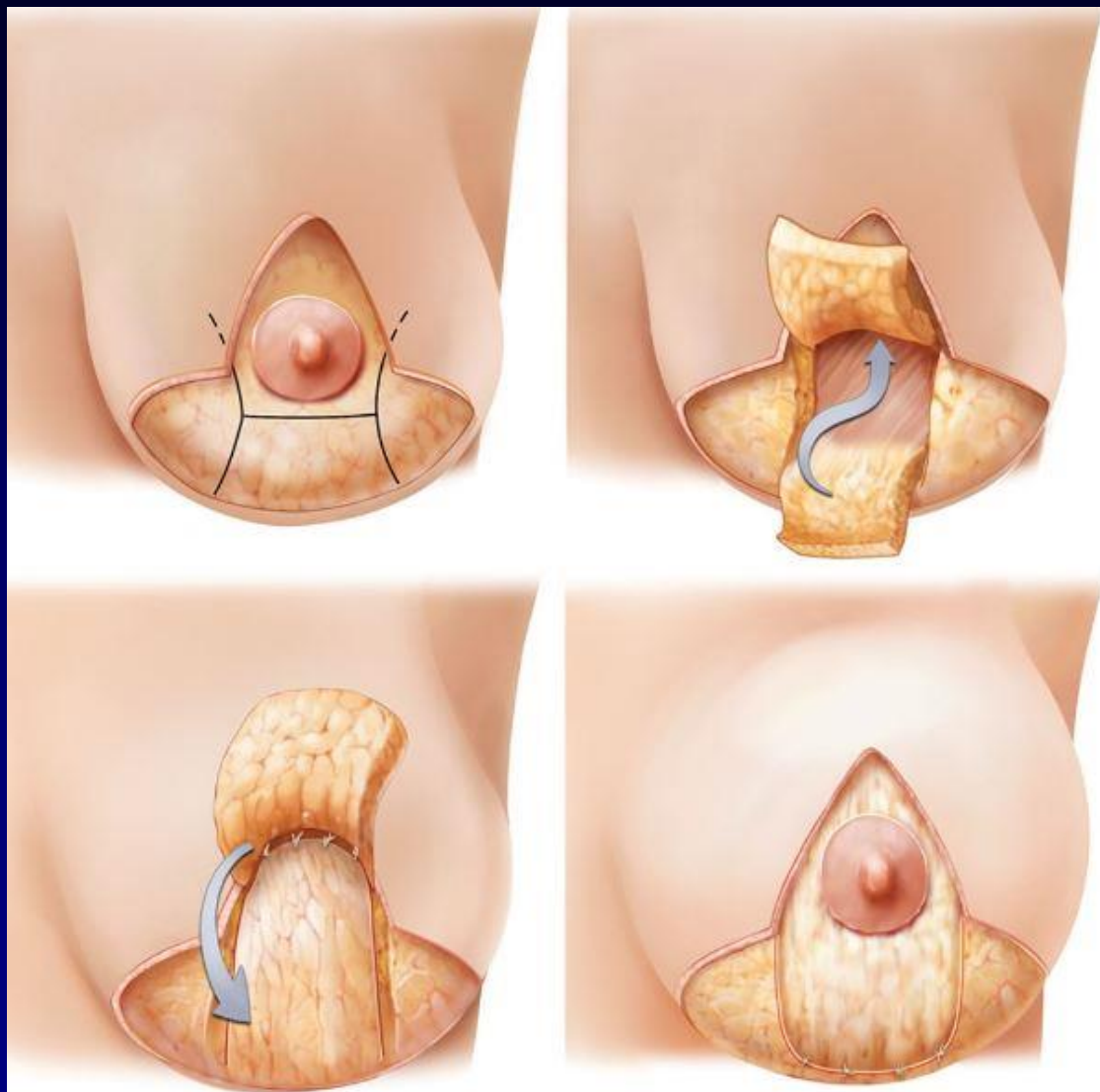
# Other Variations

Vertical mastopexy with superiorly based inferior flap

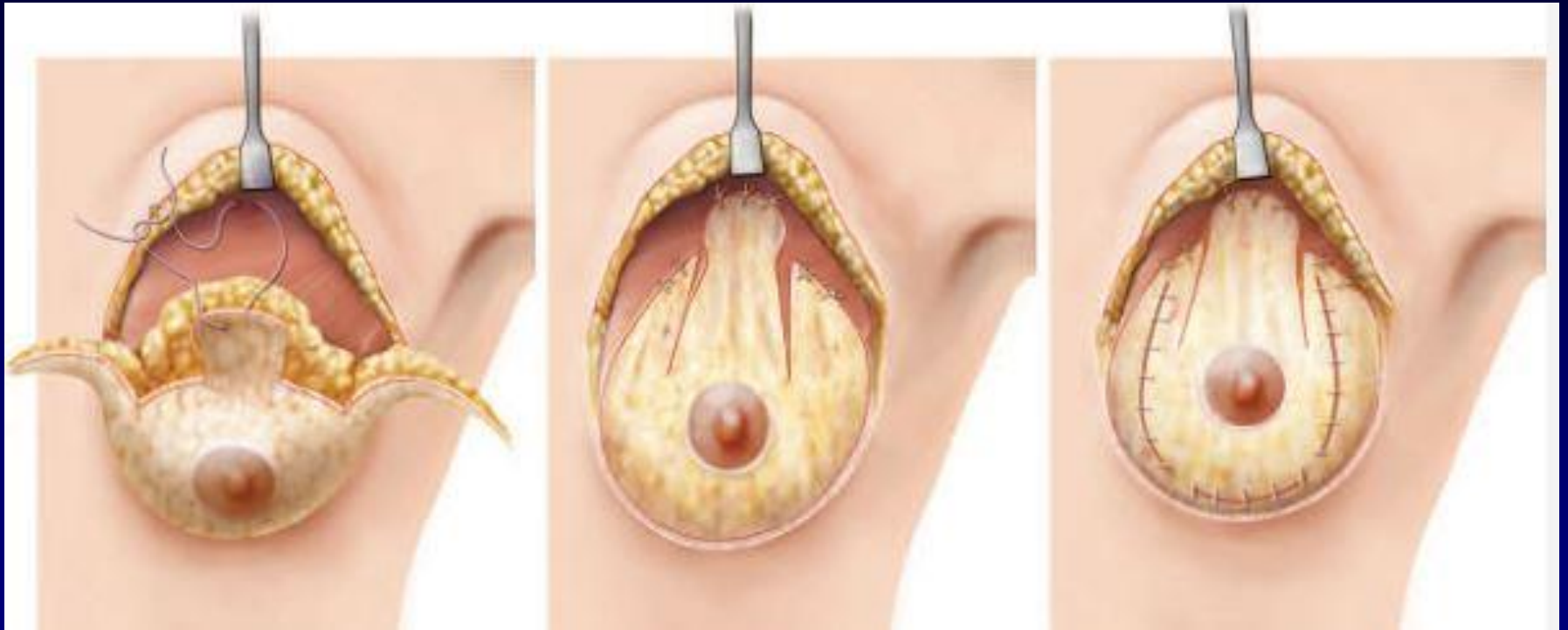



# Inverted -T mastopexy with superior & inferior flaps.



# Mastopexy following massive weight loss



# Complications

- General

bleeding, haematoma

infection

wound breakdown

# Complications

- Specific

1. Recurrence of ptosis
2. Scar –stretched, pleating
3. Areolar problems
  - shape –irreg, large, uneven
  - position –uneven, too high, too low
  - rd block suture –palpable, exposure, breakage
4. Deformity of breast
5. Nipple necrosis
6. Fat necrosis of flaps
7. Poor aesthetic result.







