

Disclaimer

- The copy in this file is protected by copyright of the author or authors. Consent was provided for the express purpose of educating attendees of the 2013 Registrars' Conference in Melbourne.
- You **MAY NOT COPY OR DISTRIBUTE** the
- contents or images in any form.
- You **MAY PRINT** the document for your own personal use as an educational resource

Eyelid Reconstruction

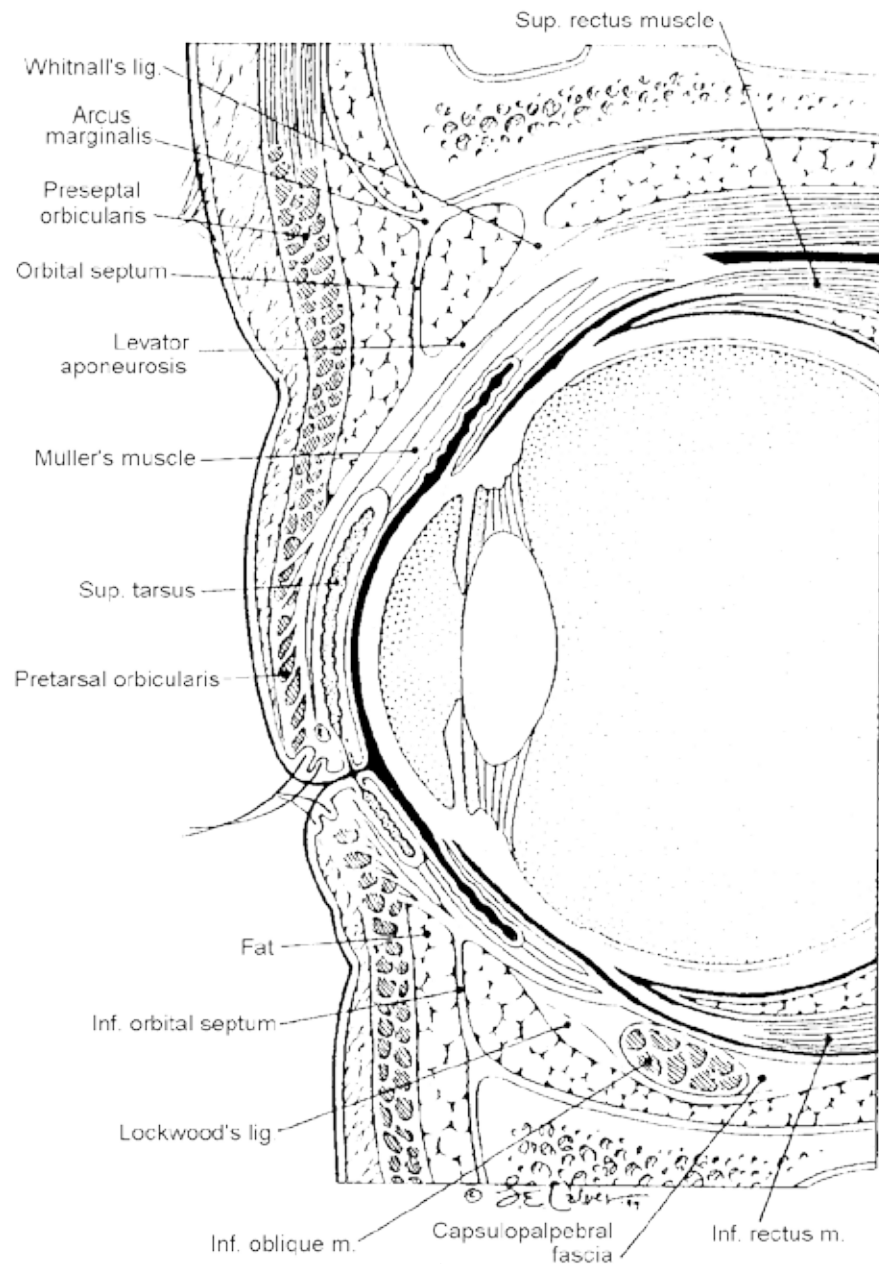
Gerard J Bayley

Plastic And Reconstructive Surgeon

Princess Alexandra Hospital

Goals of Eyelid Reconstruction

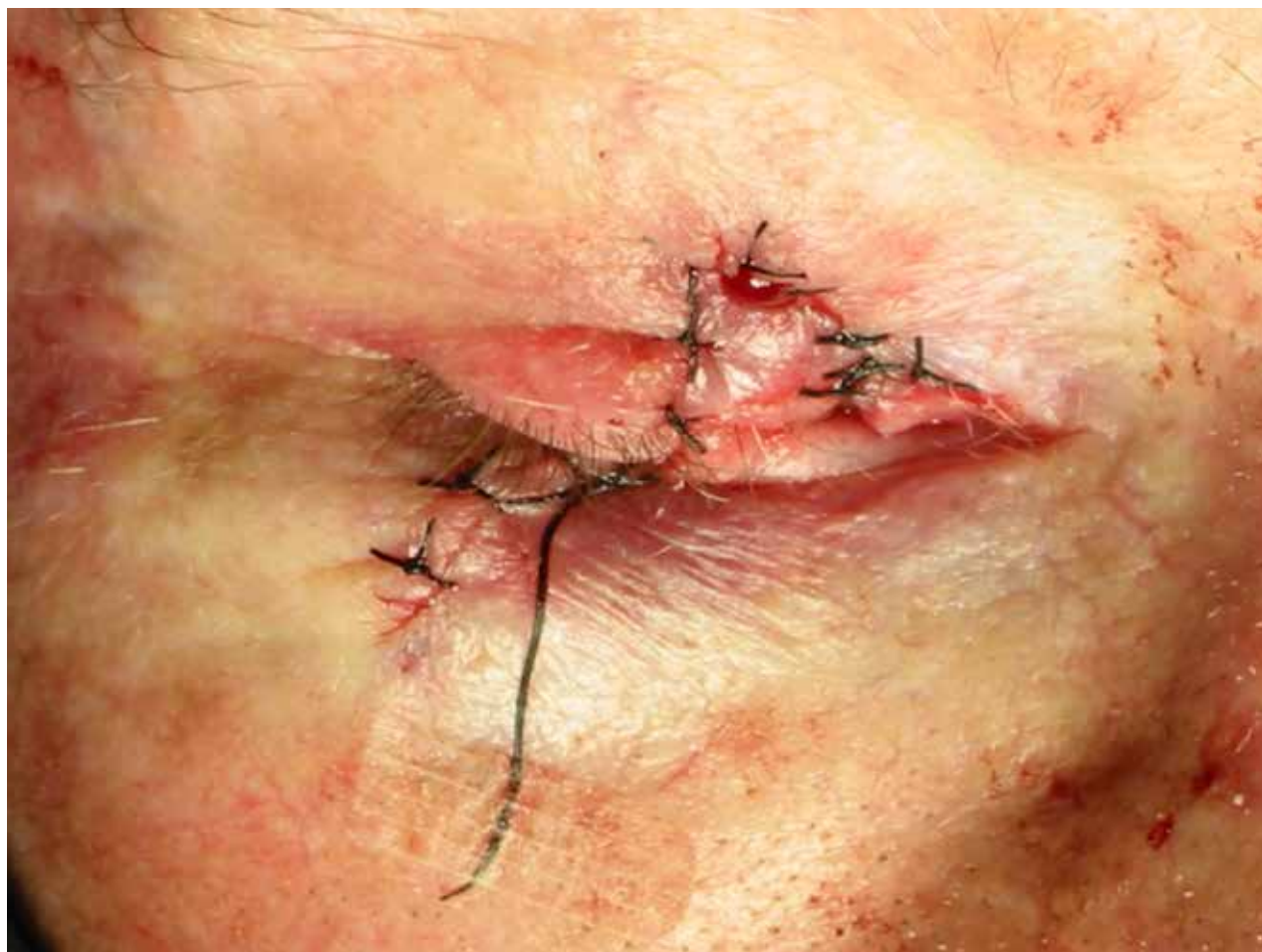1. to provide adequate eyelid function,
2. to afford globe protection,
3. to achieve acceptable aesthetic results.



Upper Eyelid

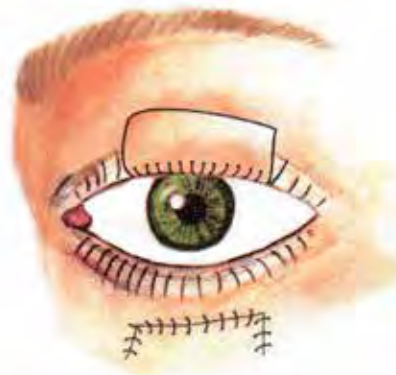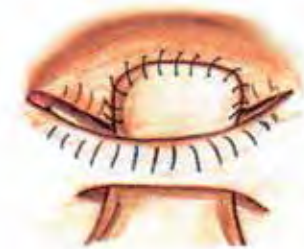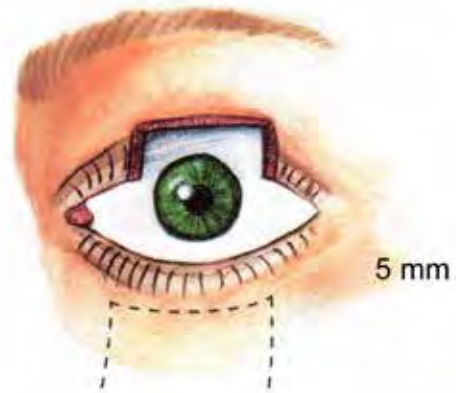
- Layers
 - Skin
 - Support (Tarsal plate, Septum, Levator, Obicularis)
 - Conjunctiva
- Lacrimal System

Abbe Flap Repair



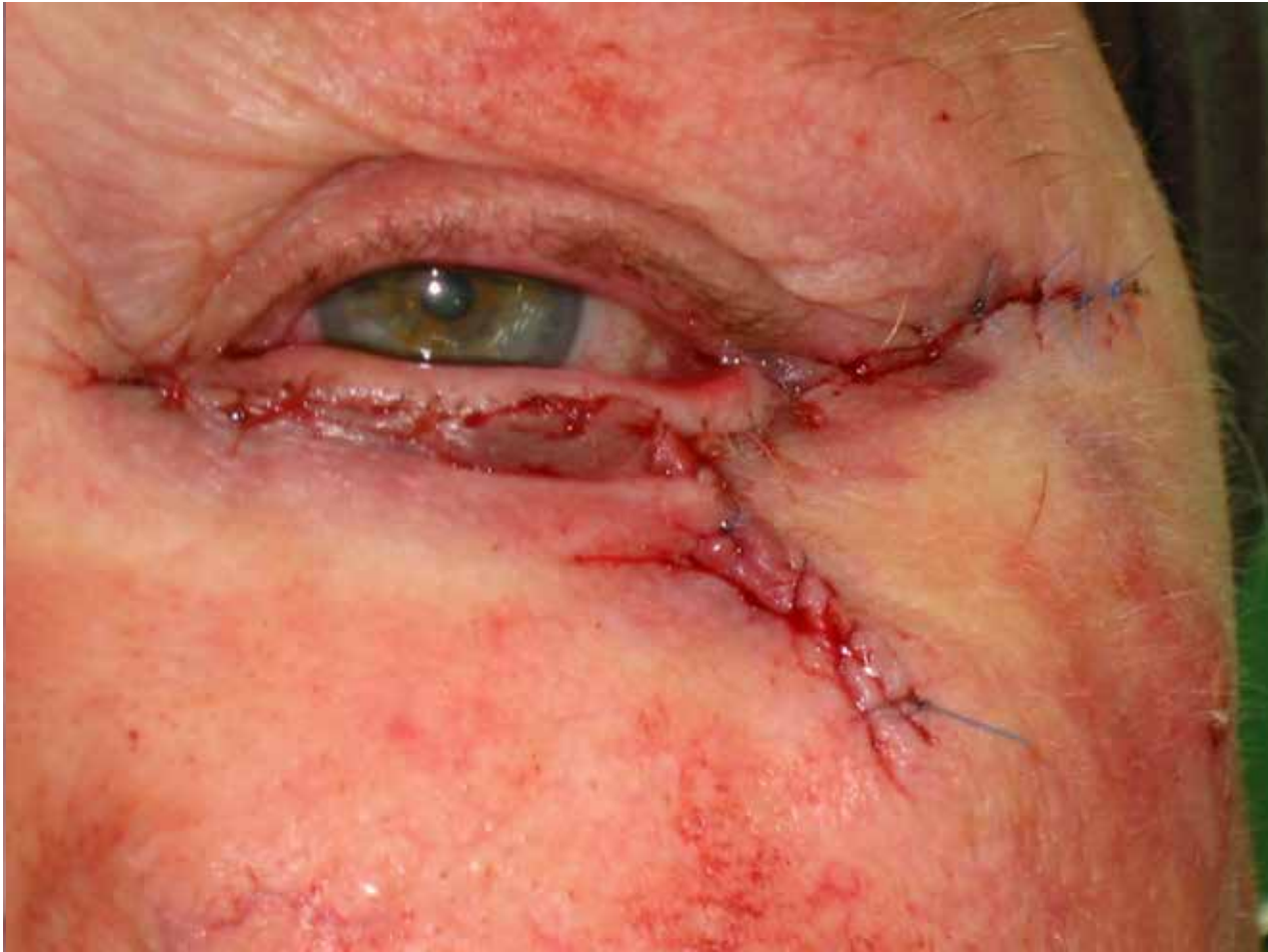Cutler Beard Flap

Cutler-Beard Flap

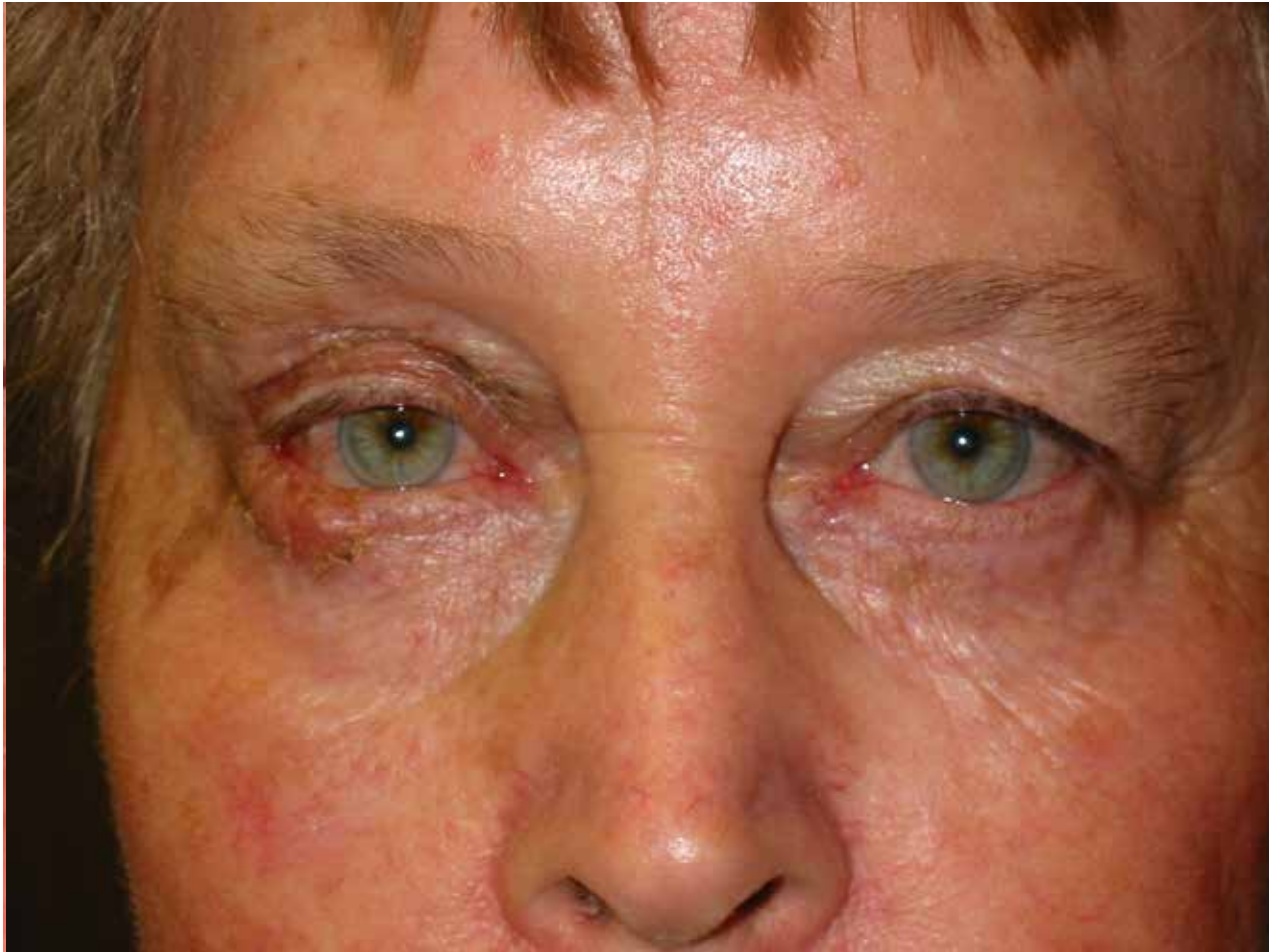

Lower Eyelid

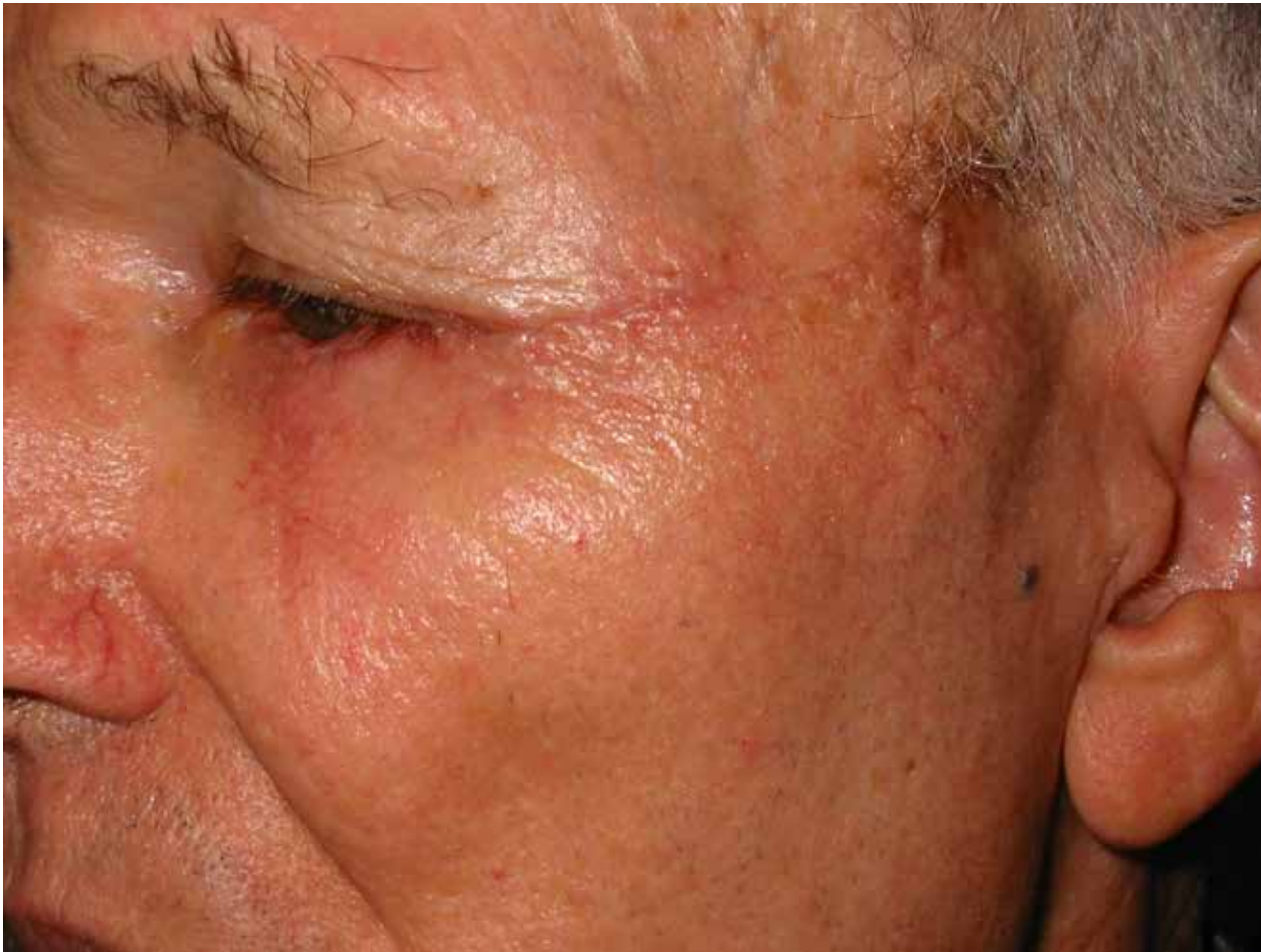Bilateral Advancement



Tripier



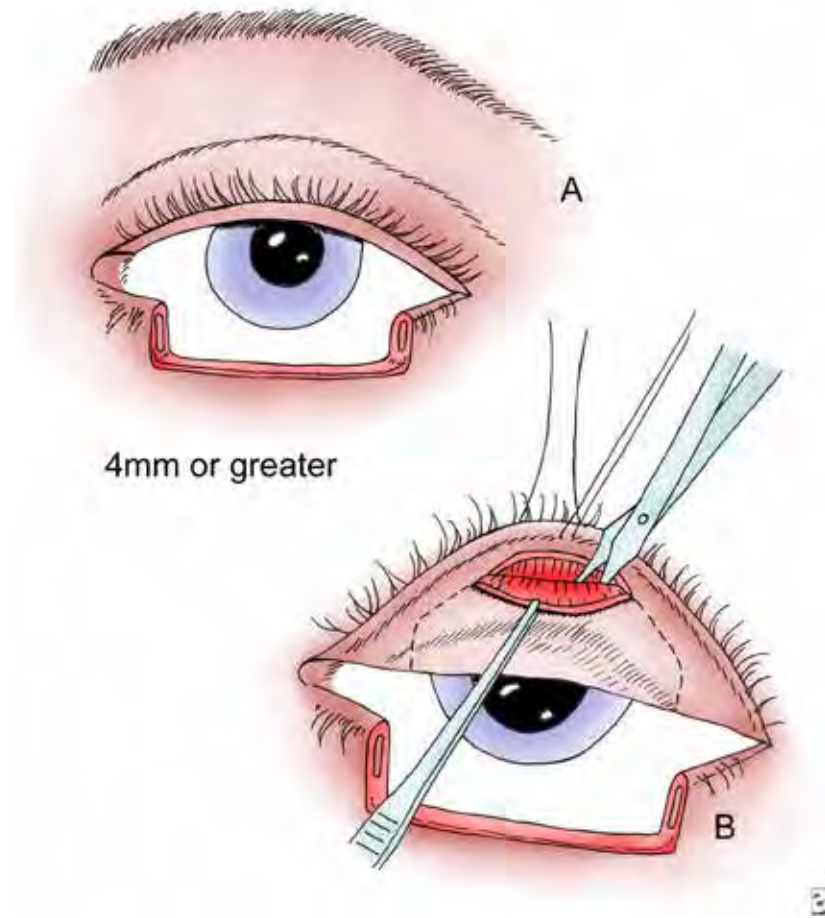
Mustarde Flap Repair



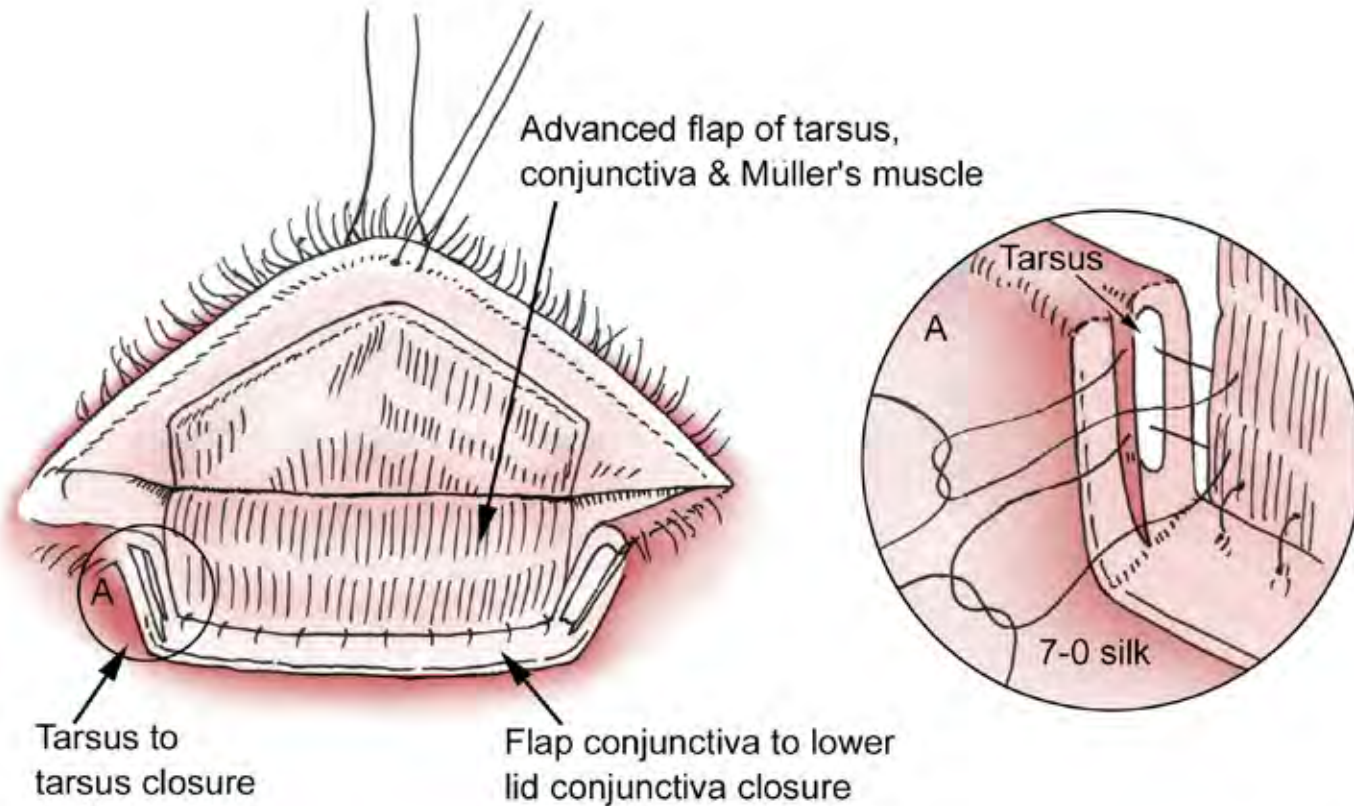
Hughes Flap

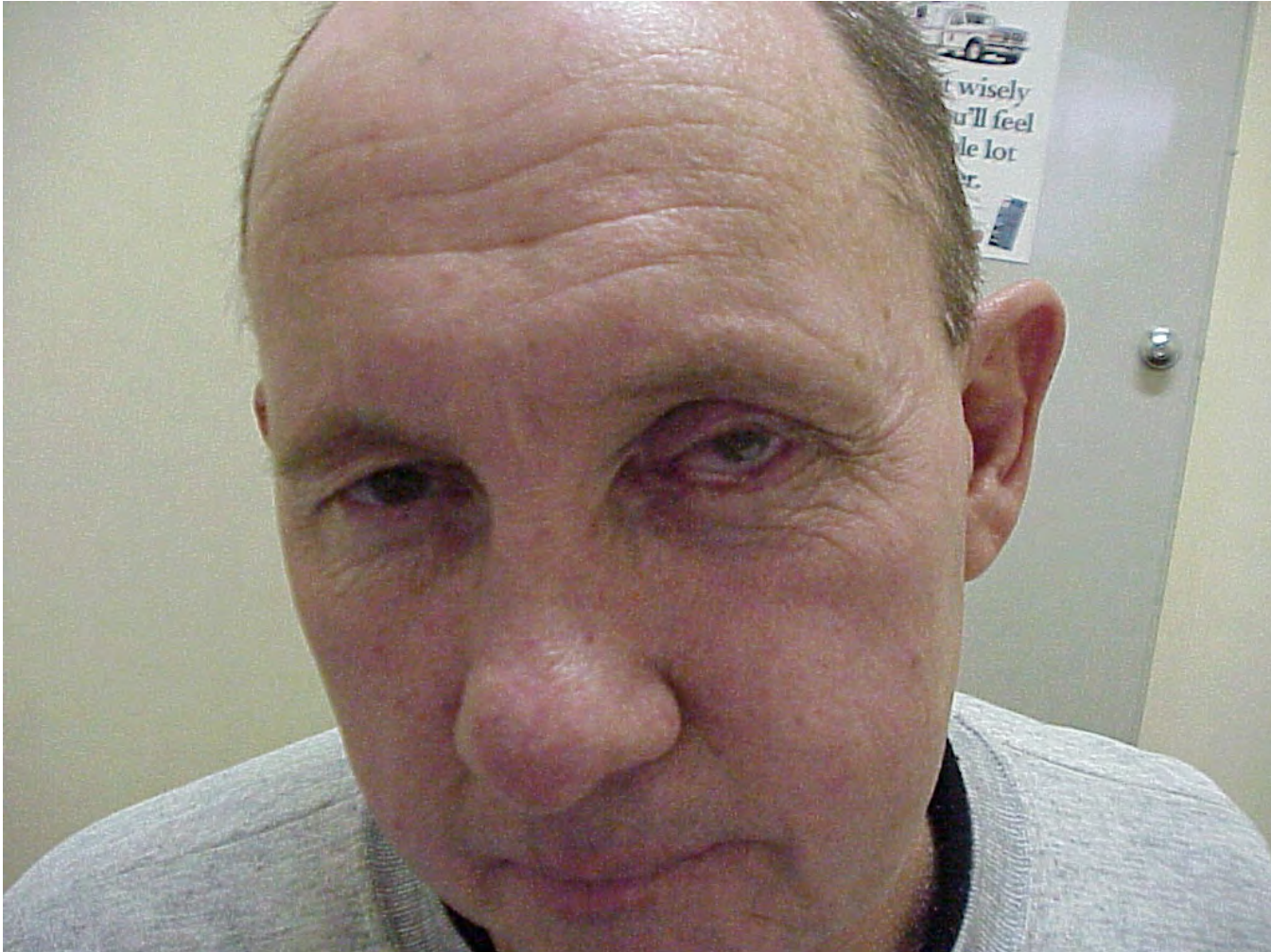

Hughes Flap



Hughes Flap





PRS Registrars Conference 2013

