

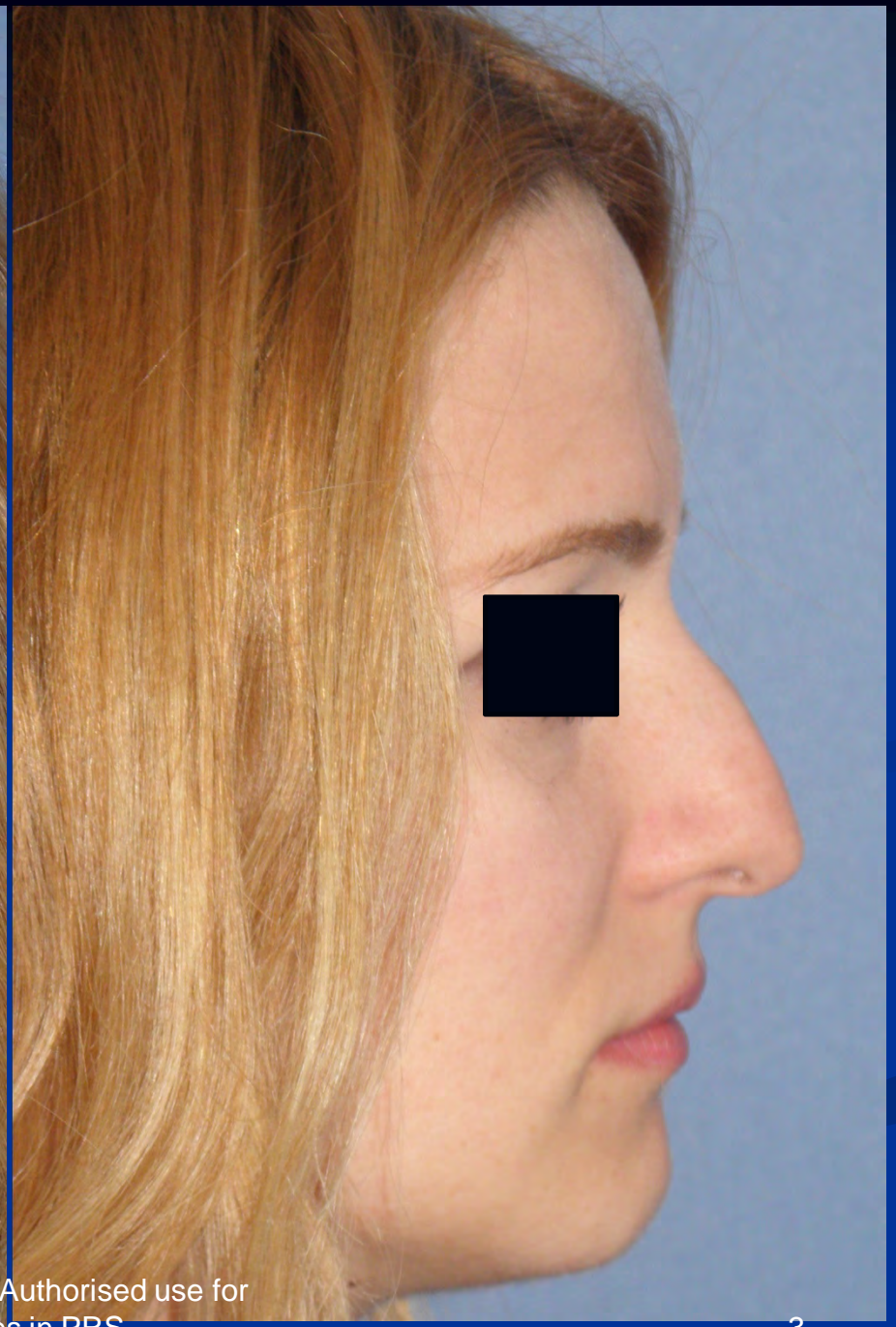
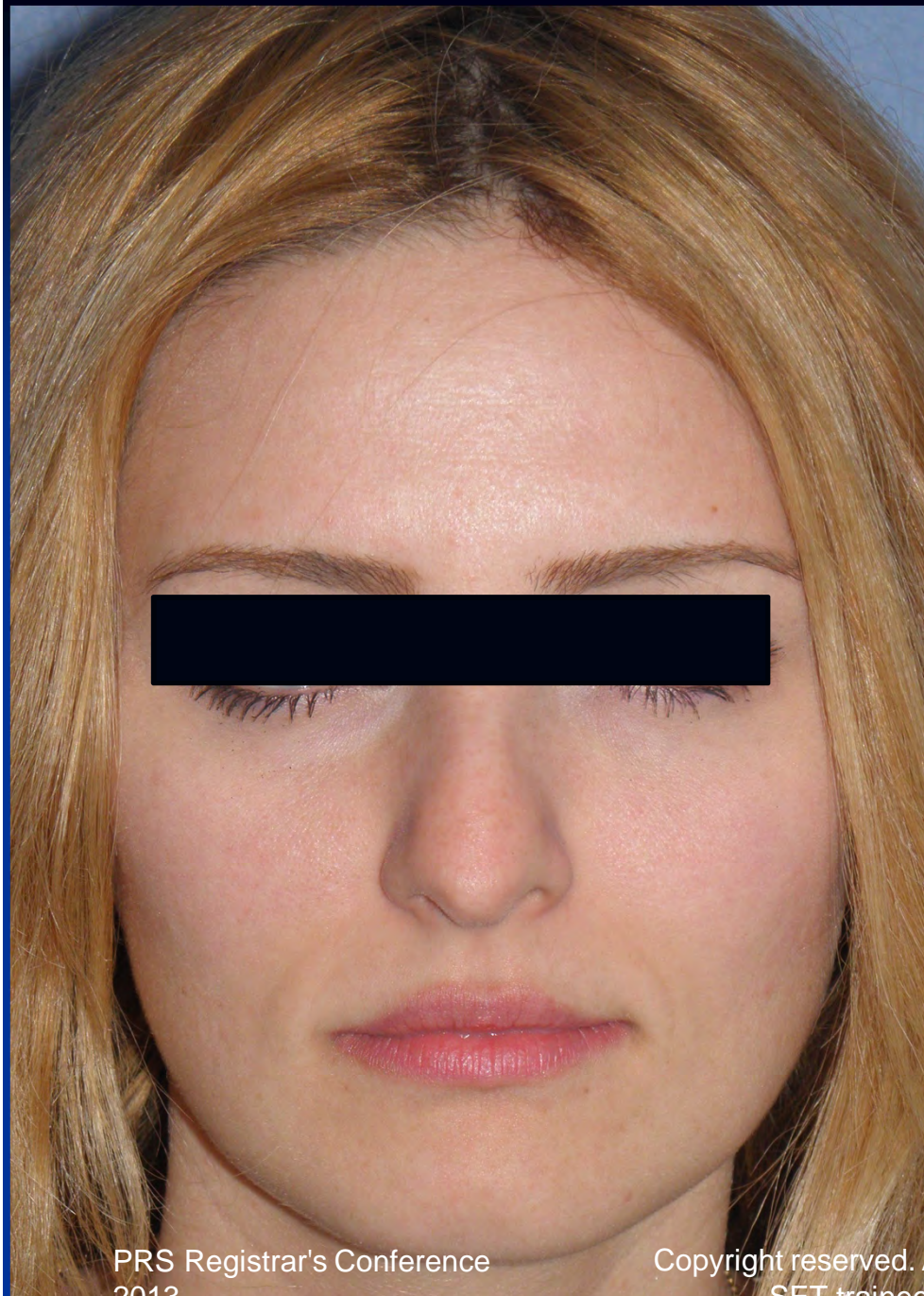# Disclaimer

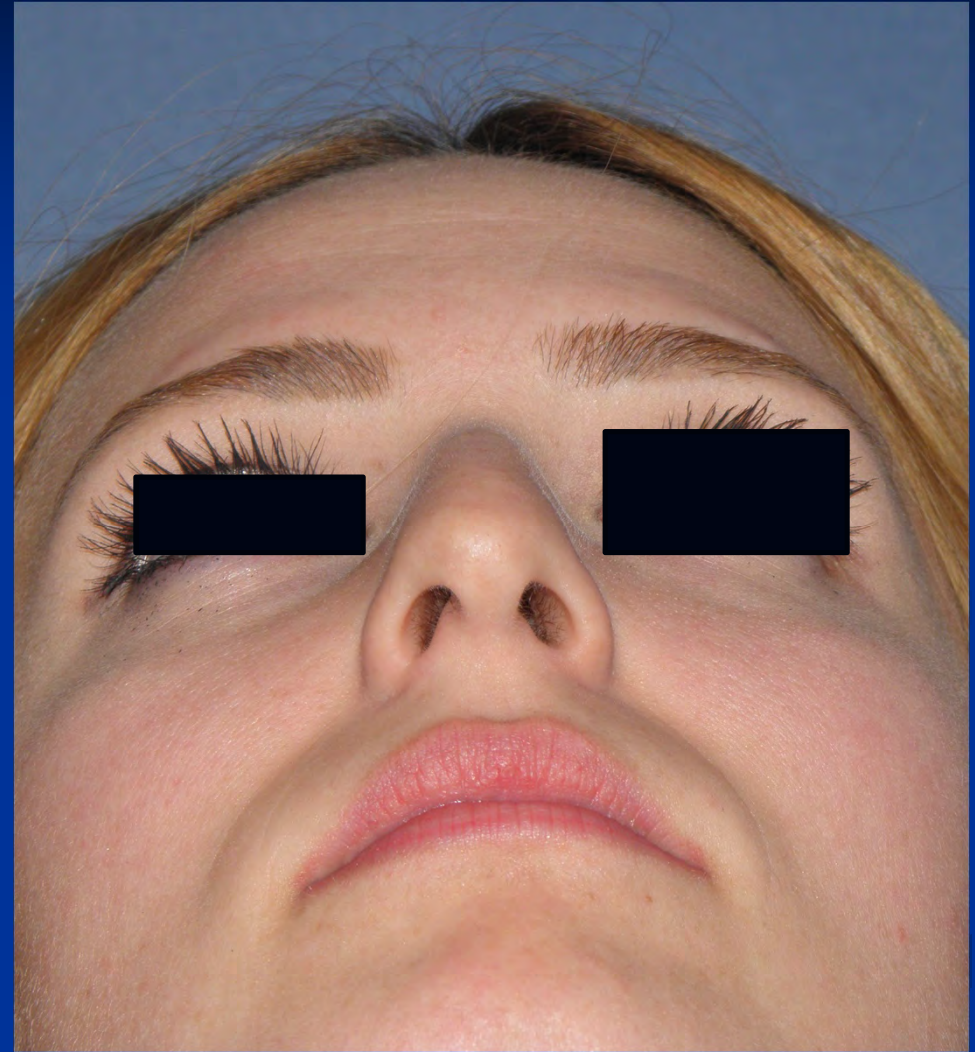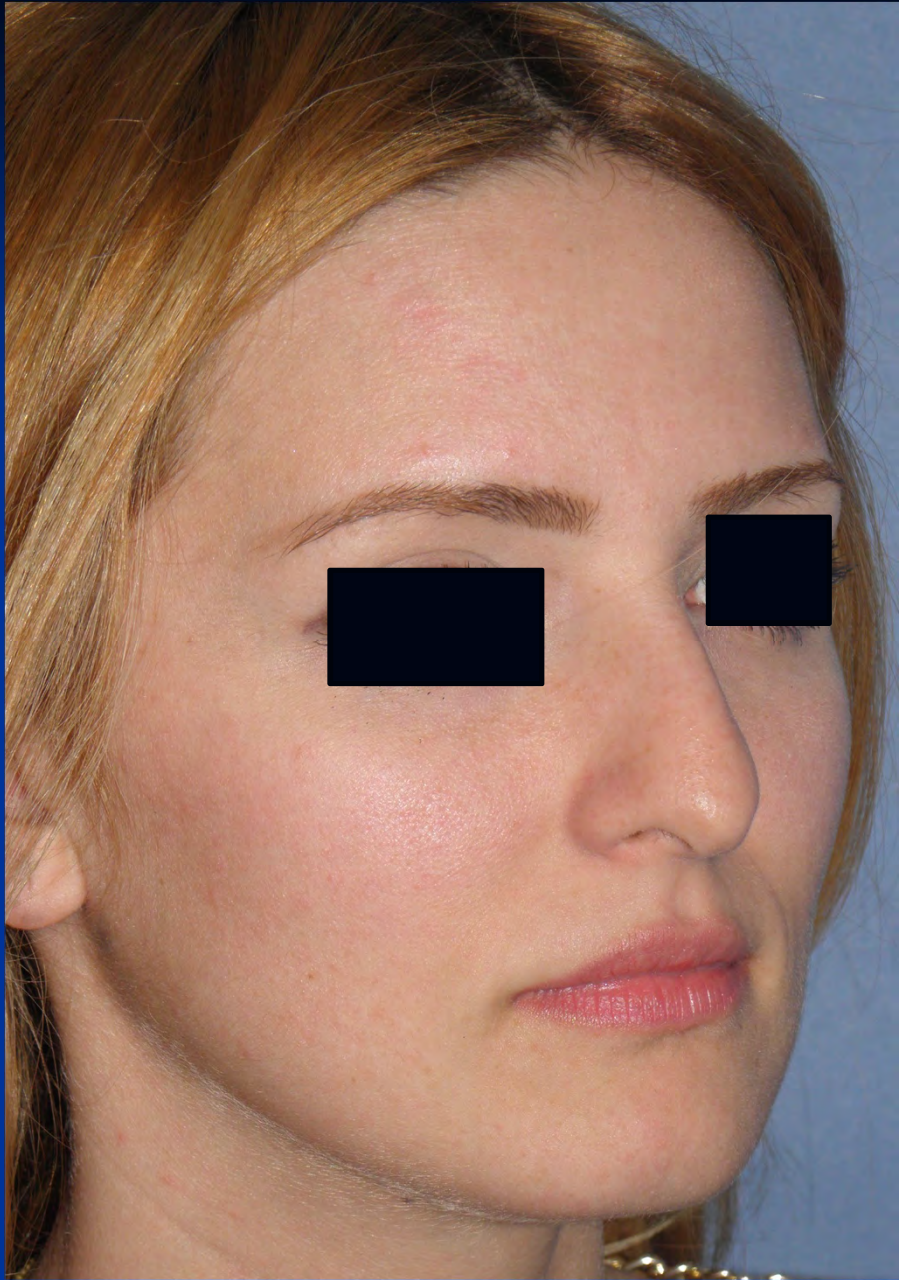
- The copy in this file is protected by copyright of the author or authors. Consent was provided for the express purpose of educating attendees of the 2013 Registrars' Conference in Melbourne.
- You **MAY NOT COPY OR DISTRIBUTE** the contents or images in any form.
- You **MAY PRINT** the document for your own personal use as an educational resource.

# OPEN RHINOPLASTY

**NAZIM CERKES MD.**

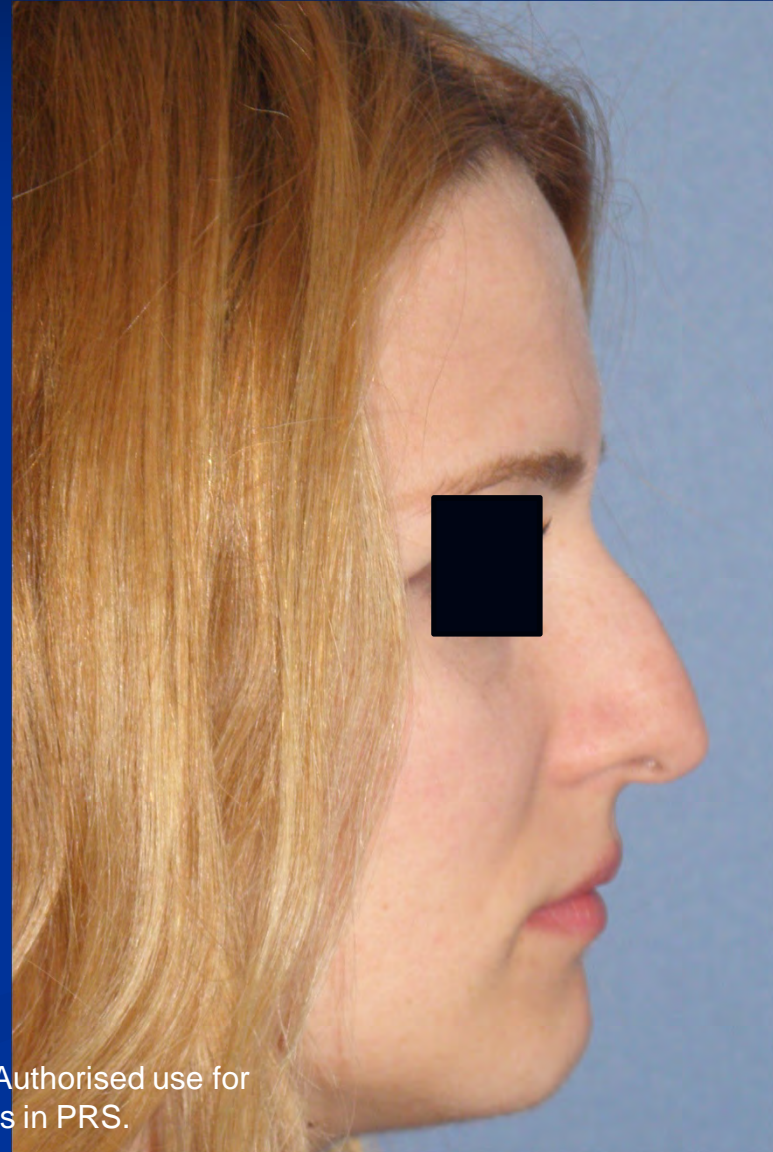
**Istanbul-TURKEY**

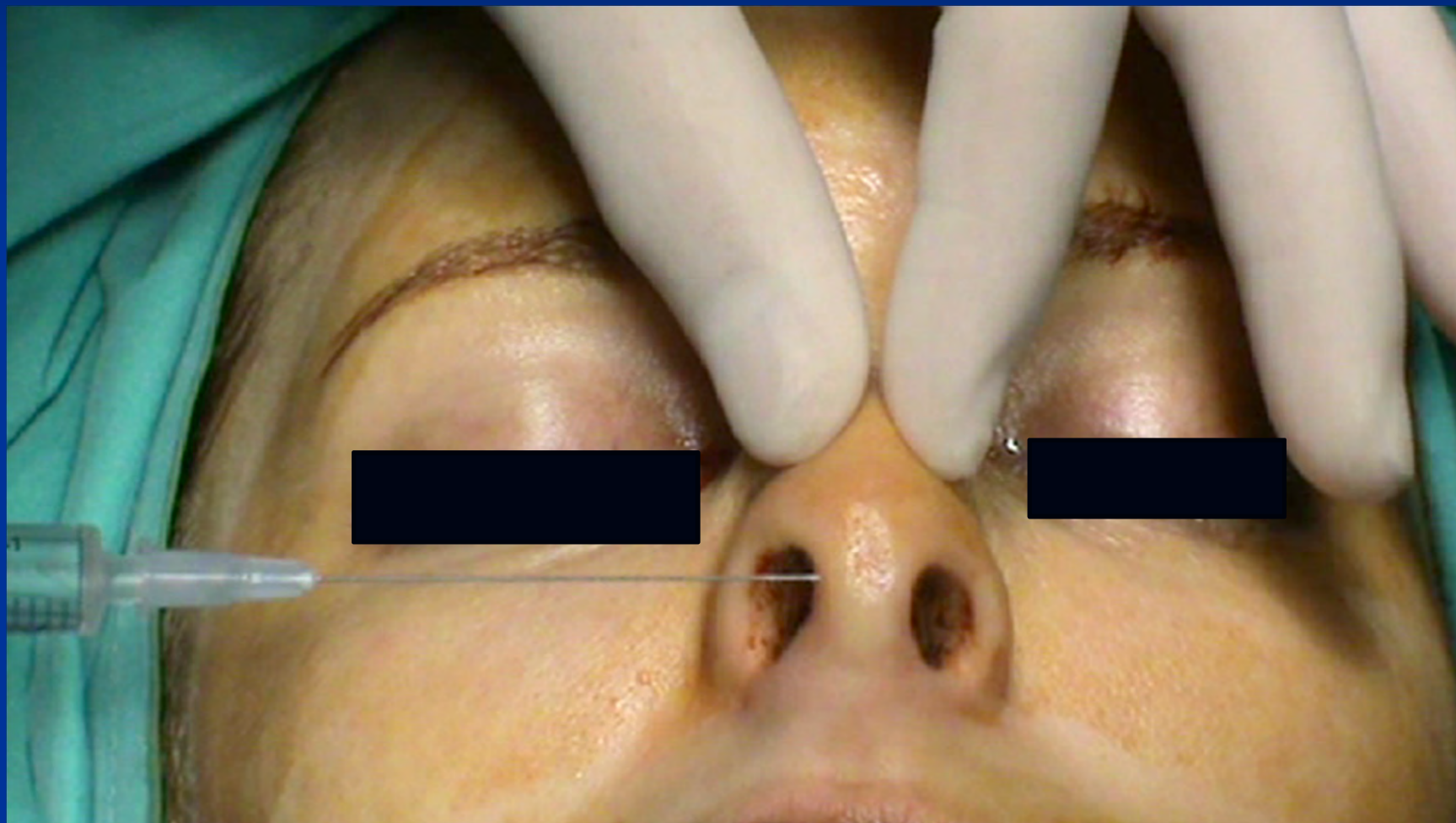



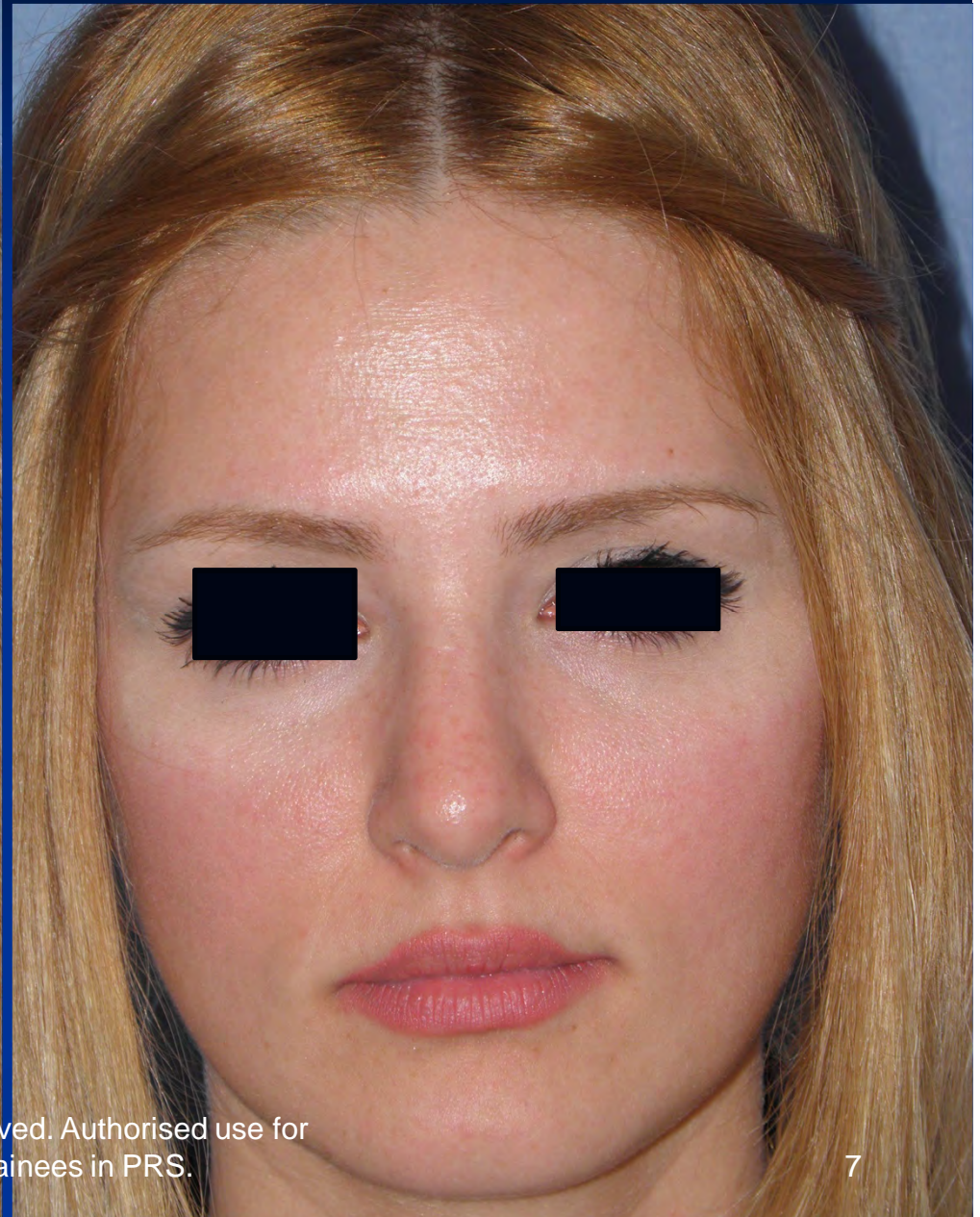
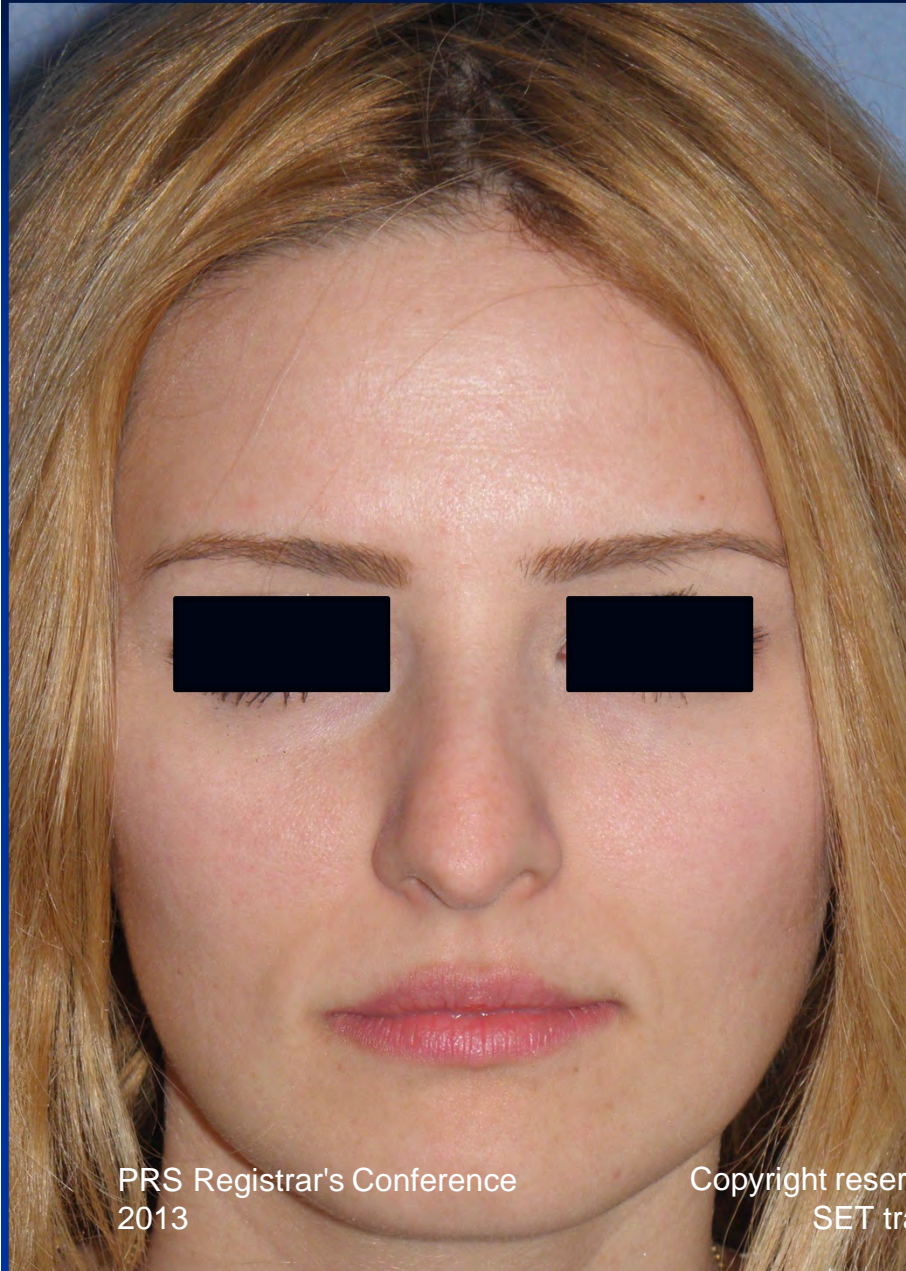# PREOPERATIVE ANALYSIS

- Irregular Dorsal Aesthetic Lines
- Bony and Cartilaginous Hump
- Low Tip Projection
- Acute Nasolabial Angle
- Pointed Nasal Tip
- Retracted Alae

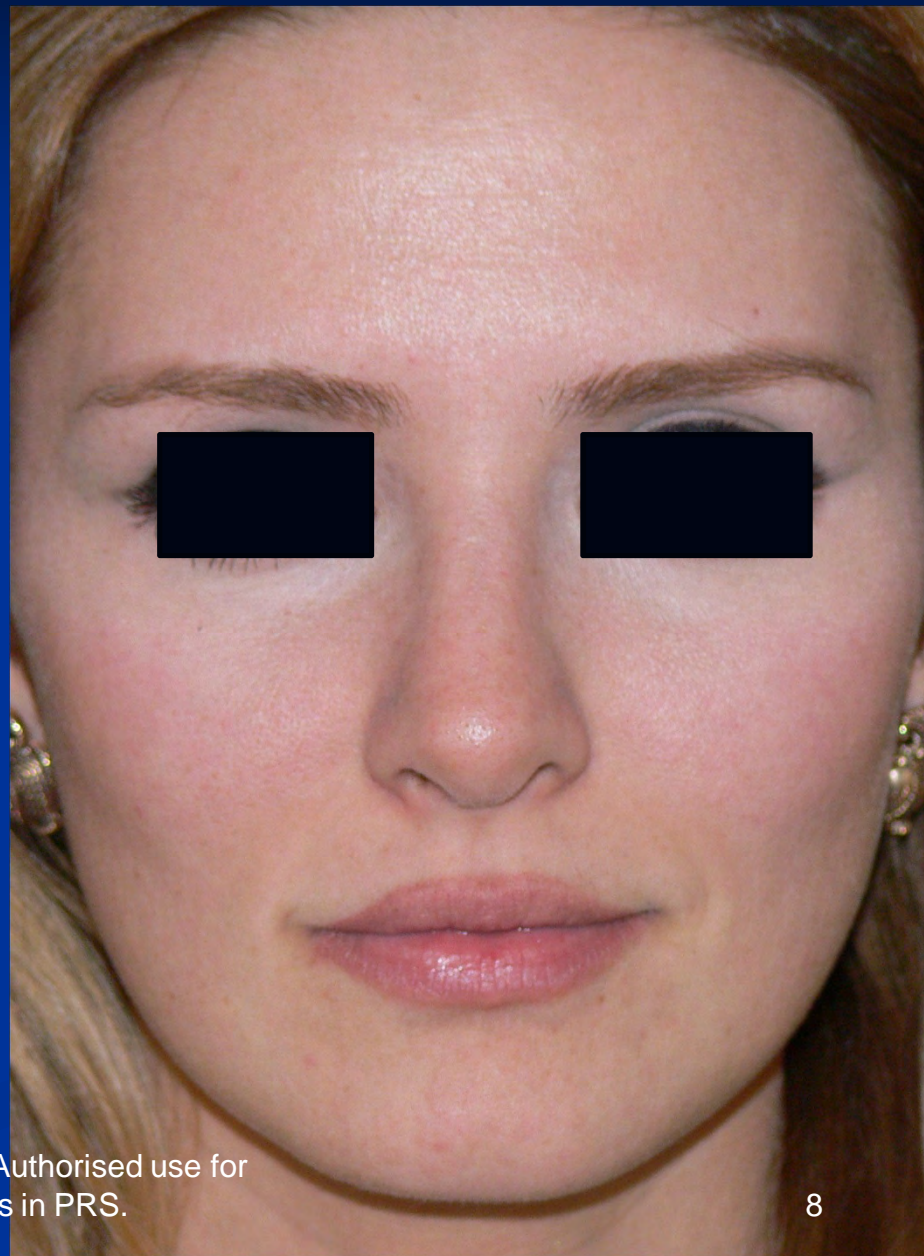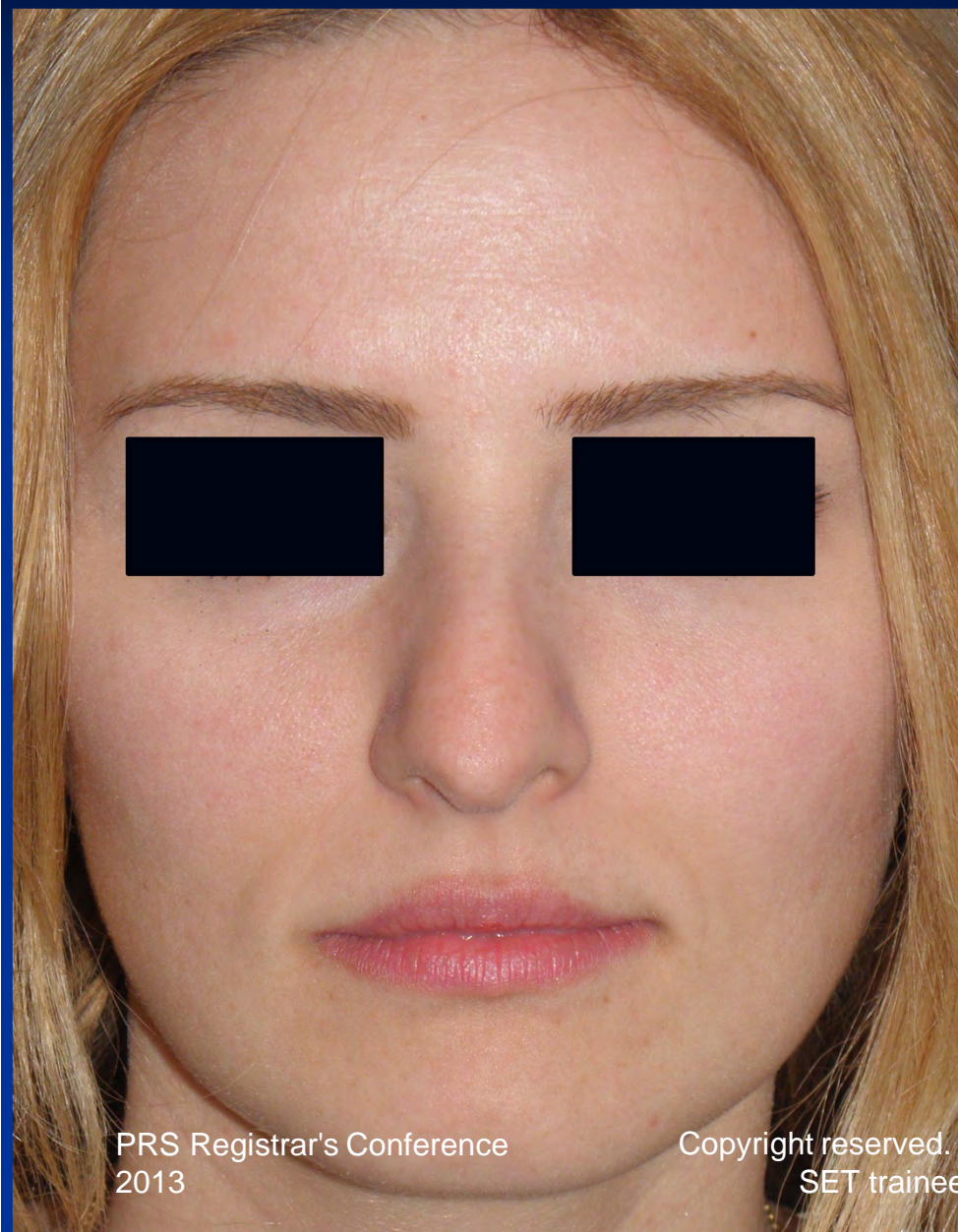




# POSTOP. 6 MONTHS

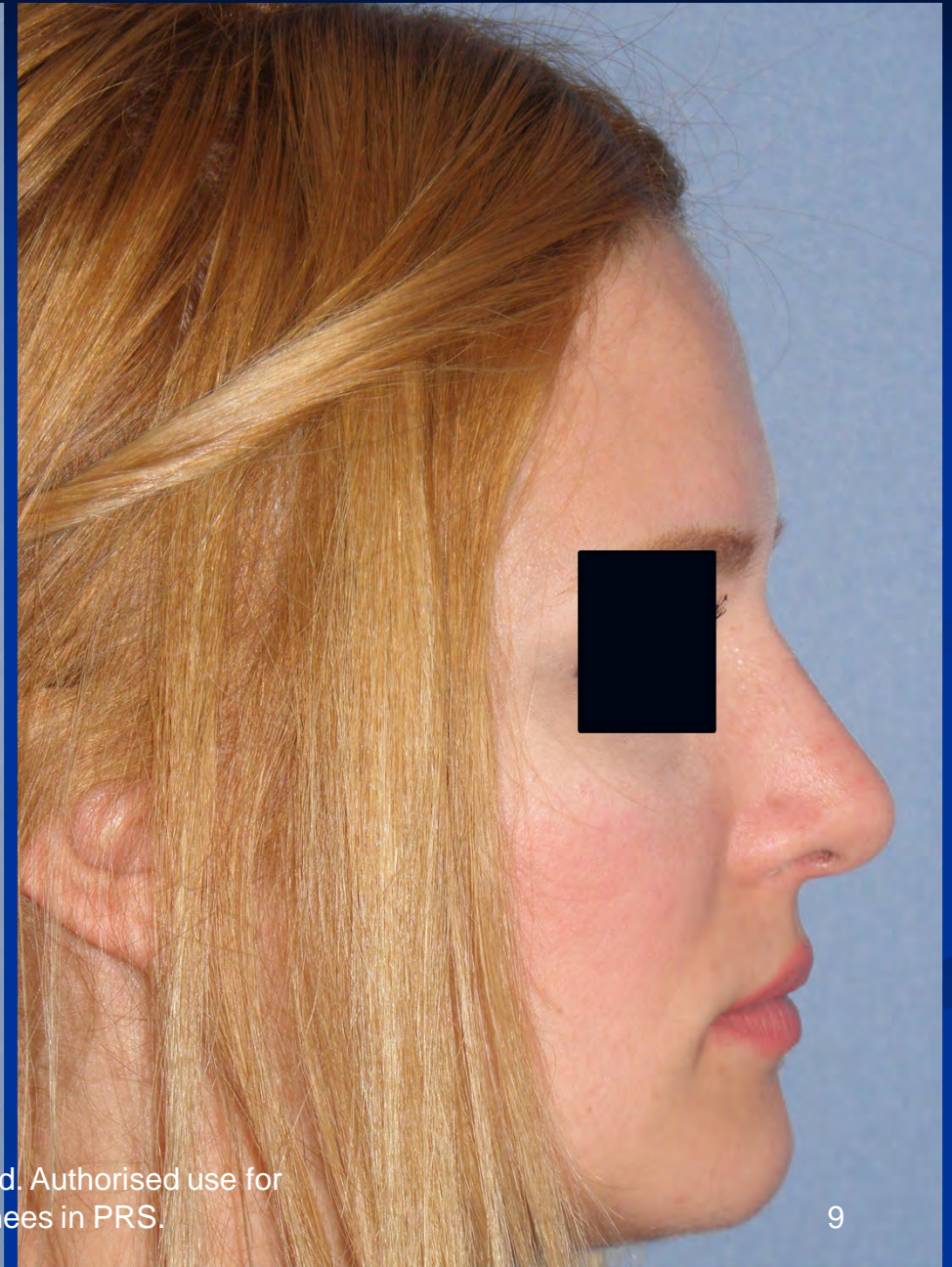
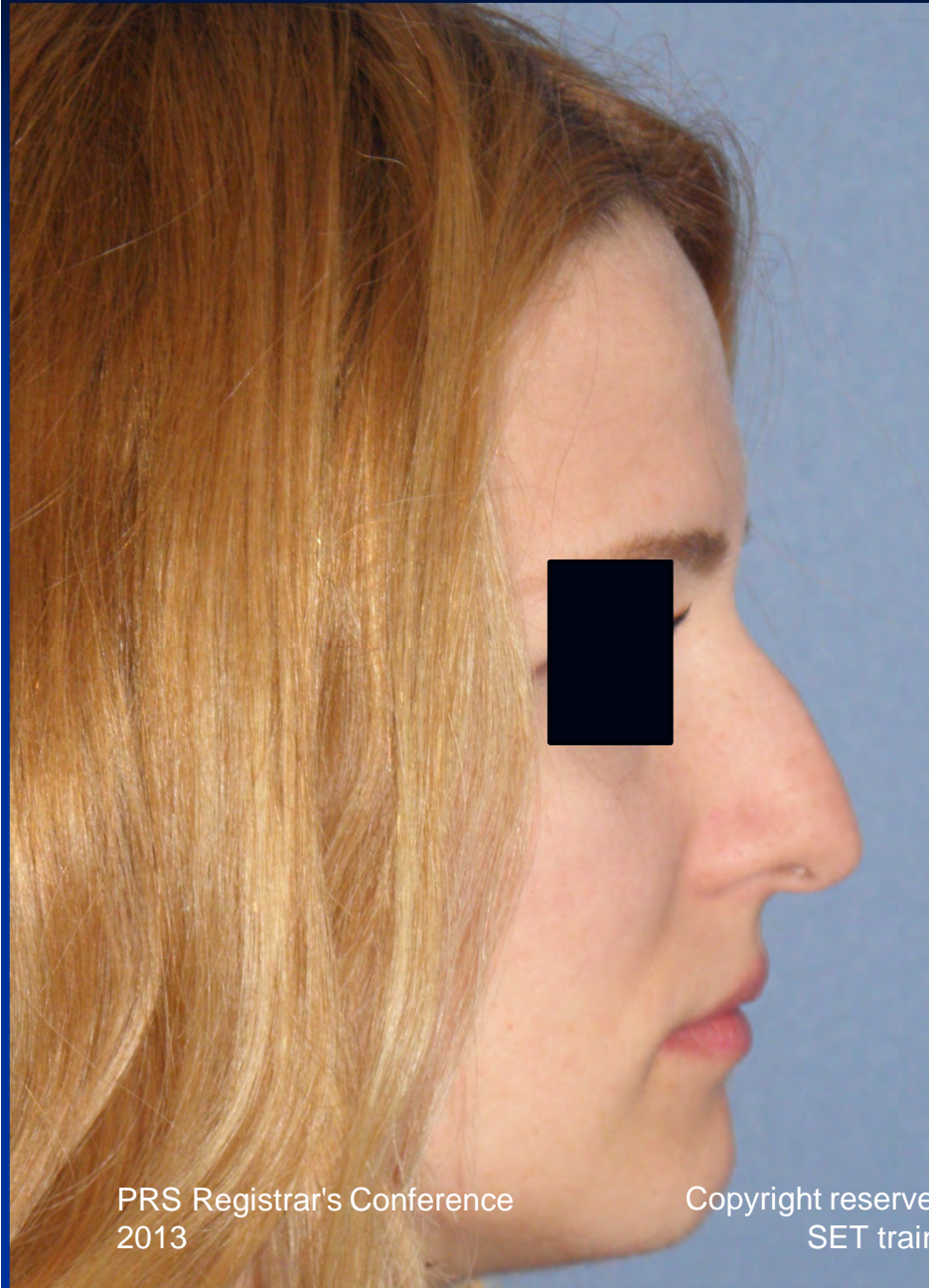
# POSTOP. 18 MONTHS

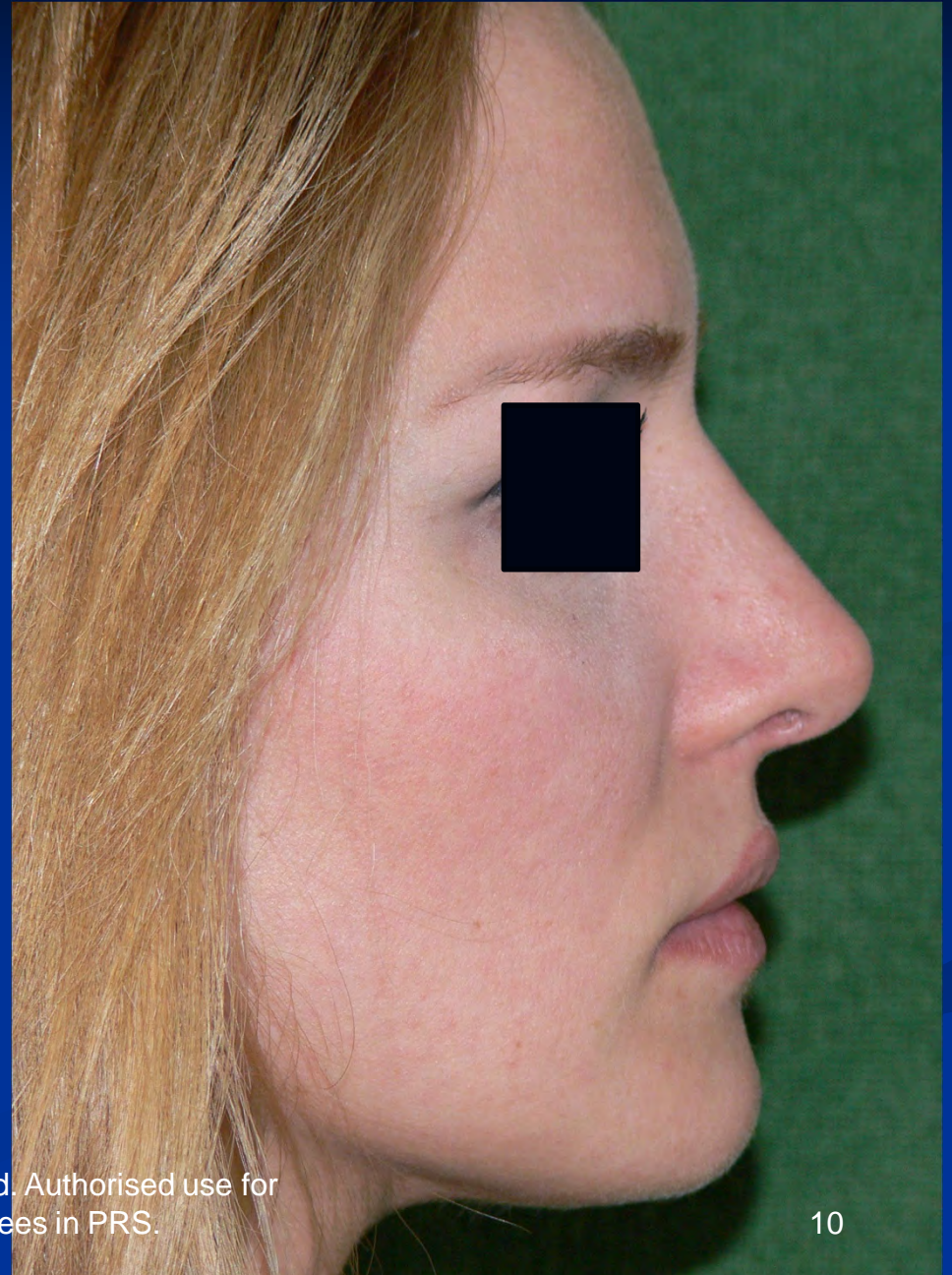
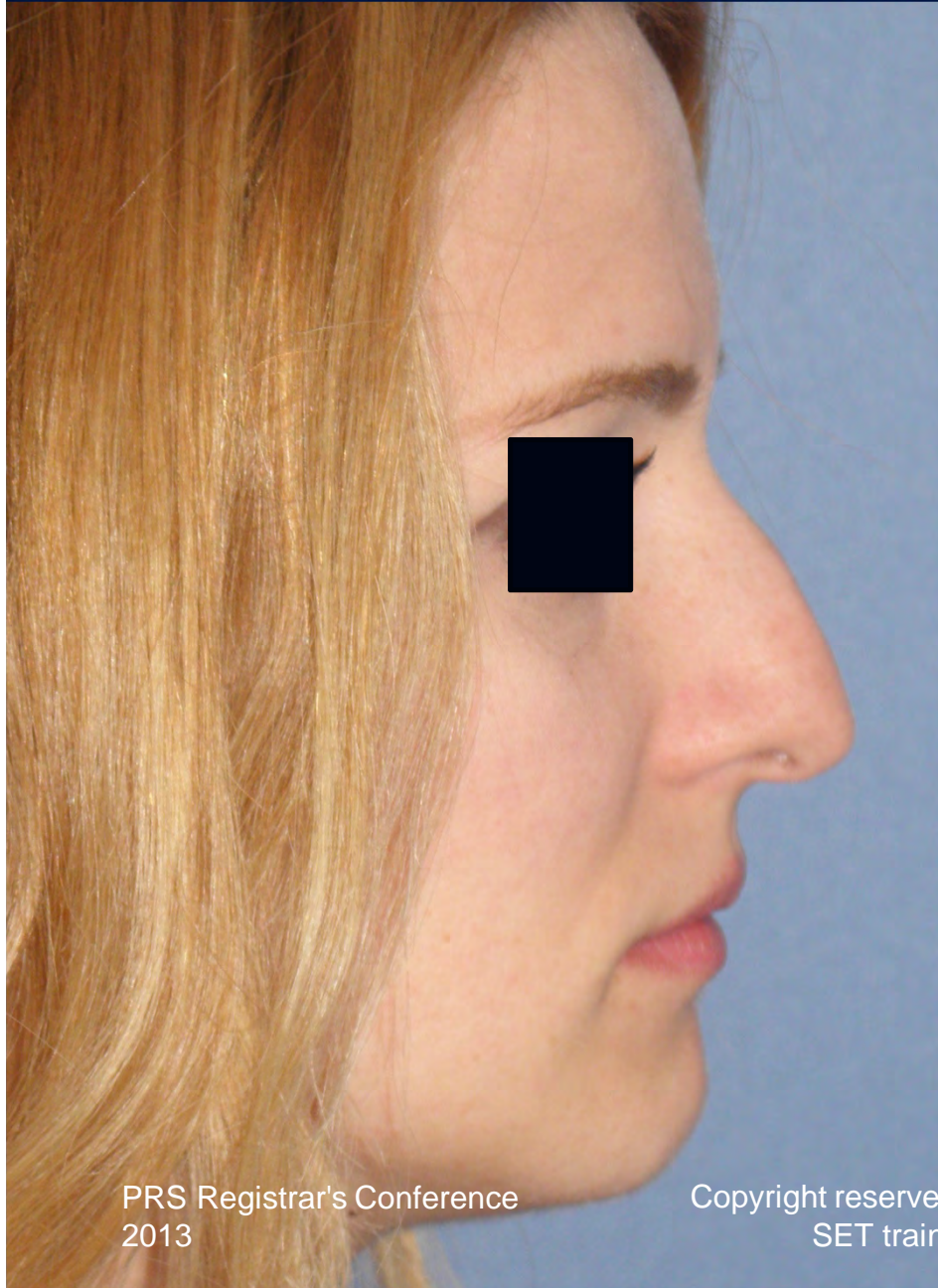




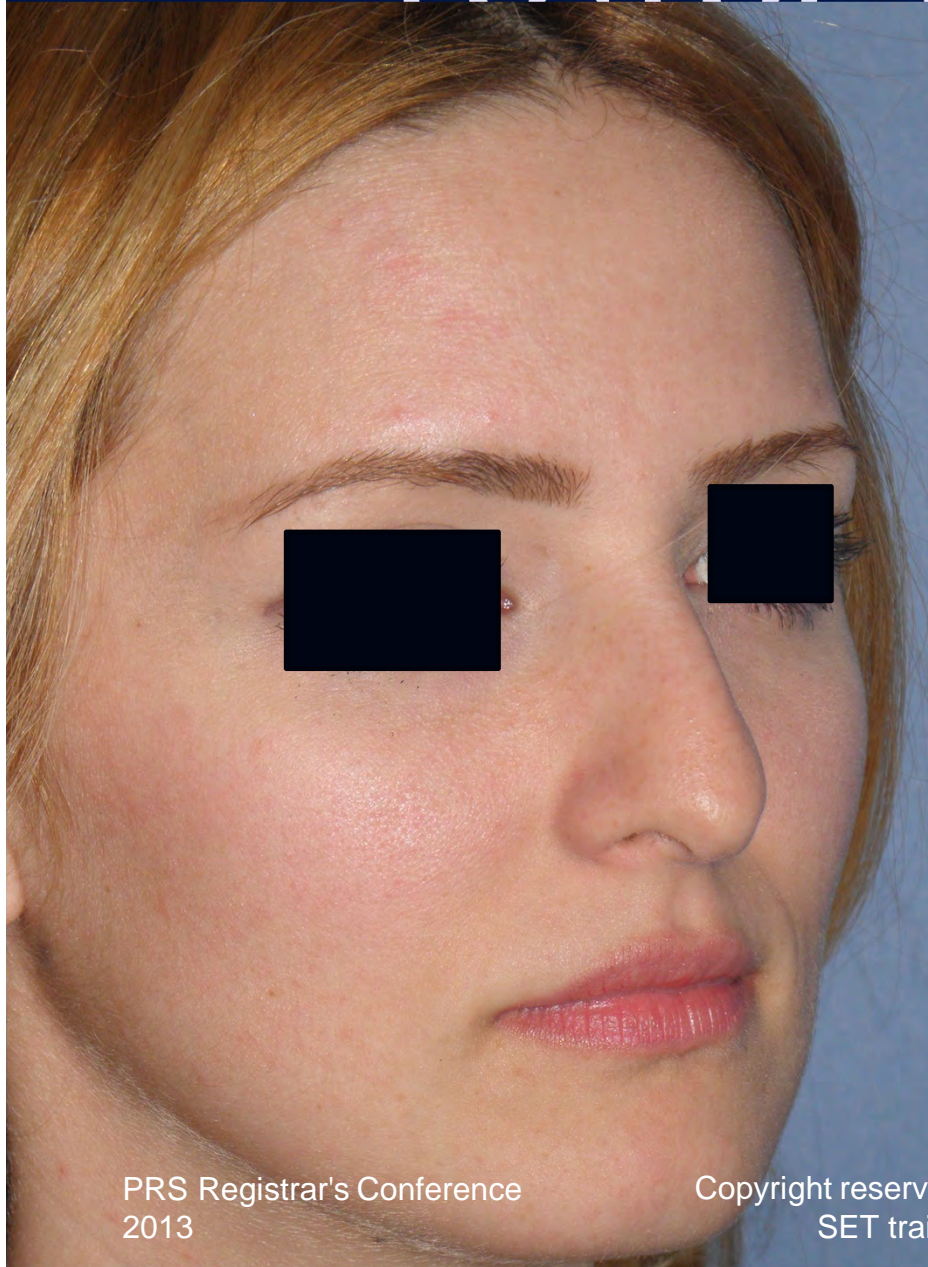# POSTOP. 6 MONTHS



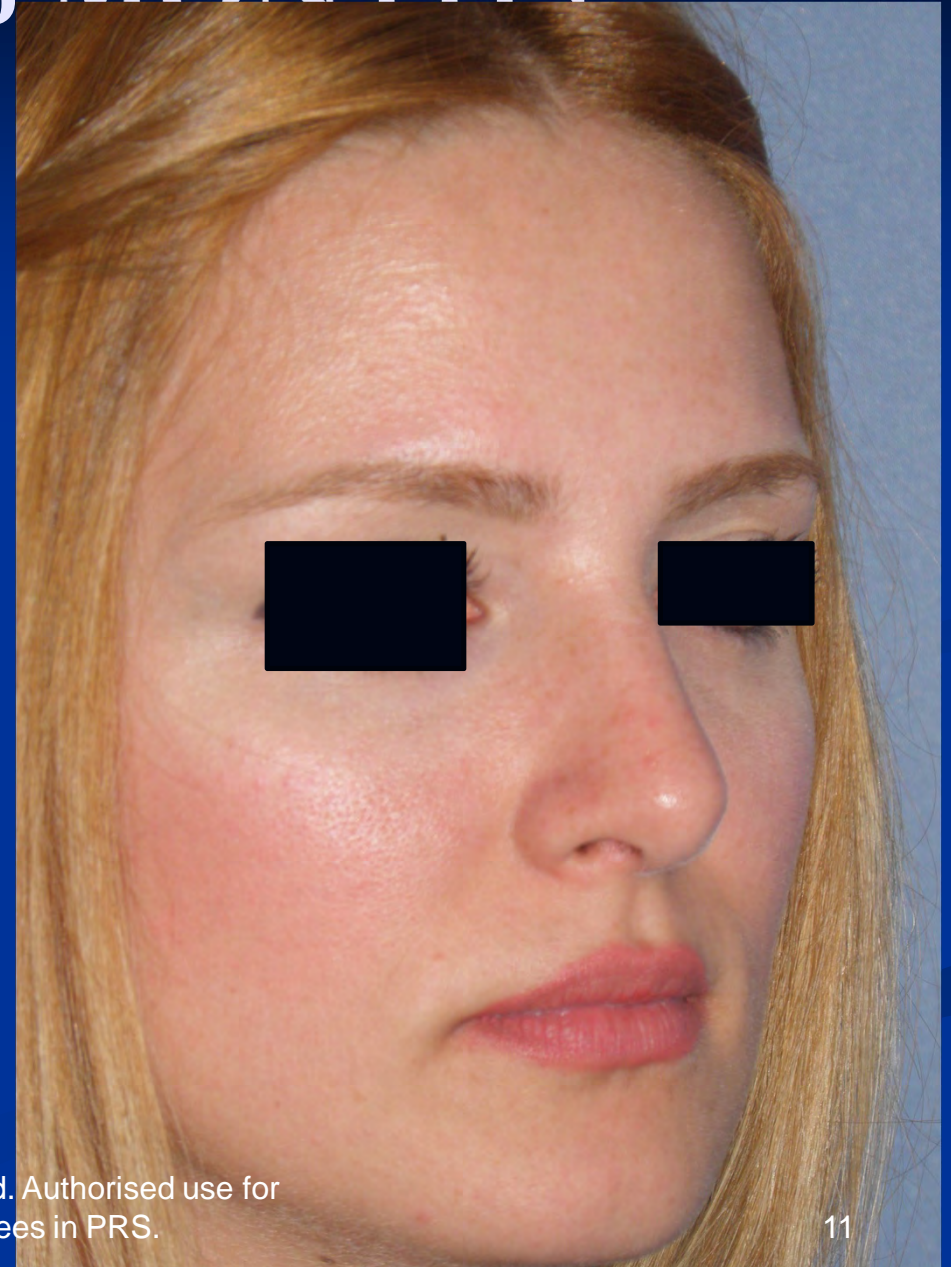# POSTOP. 18 MONTHS



# POSTOP 6 MONTHS

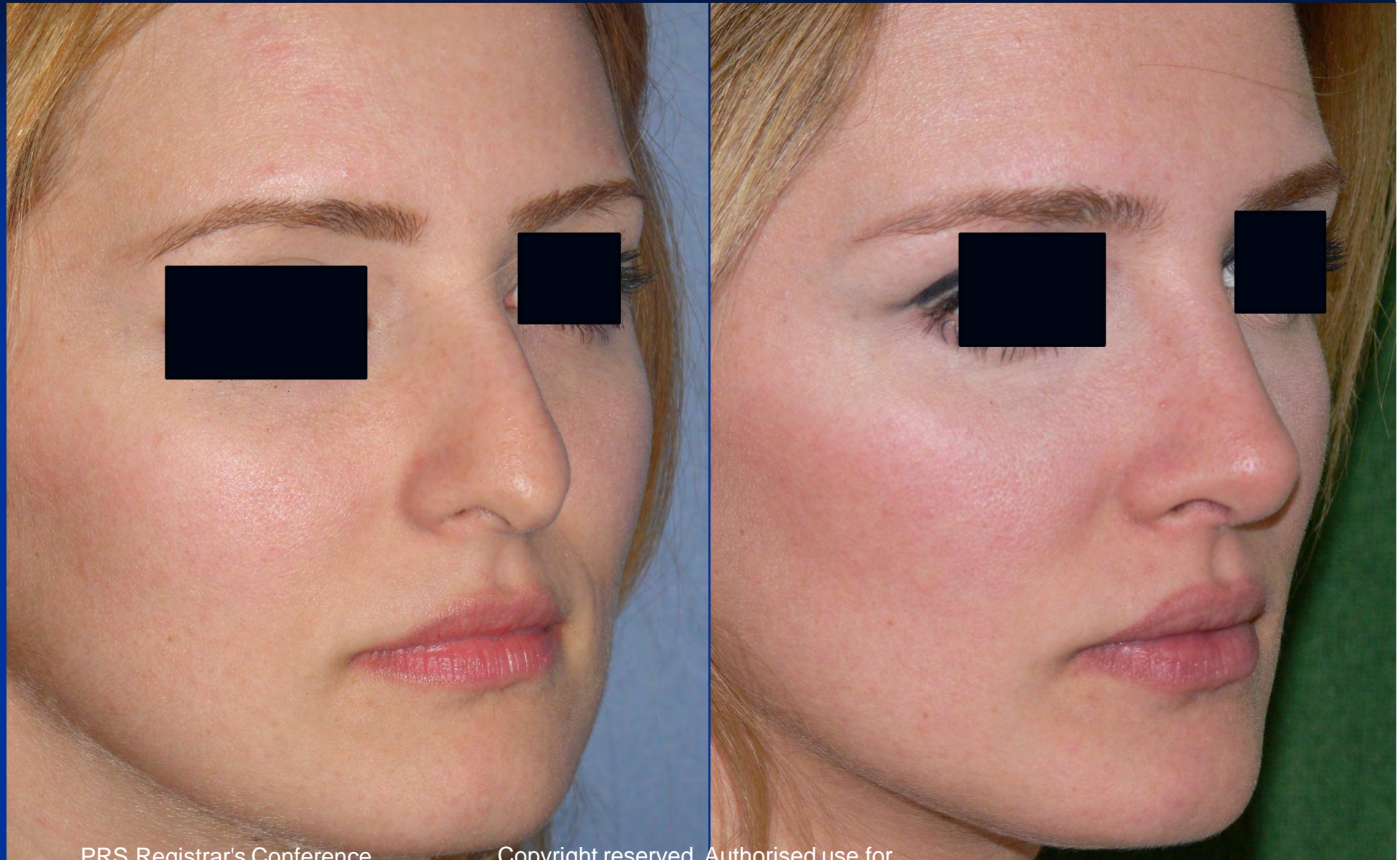

PRS Registrar's Conference  
2013

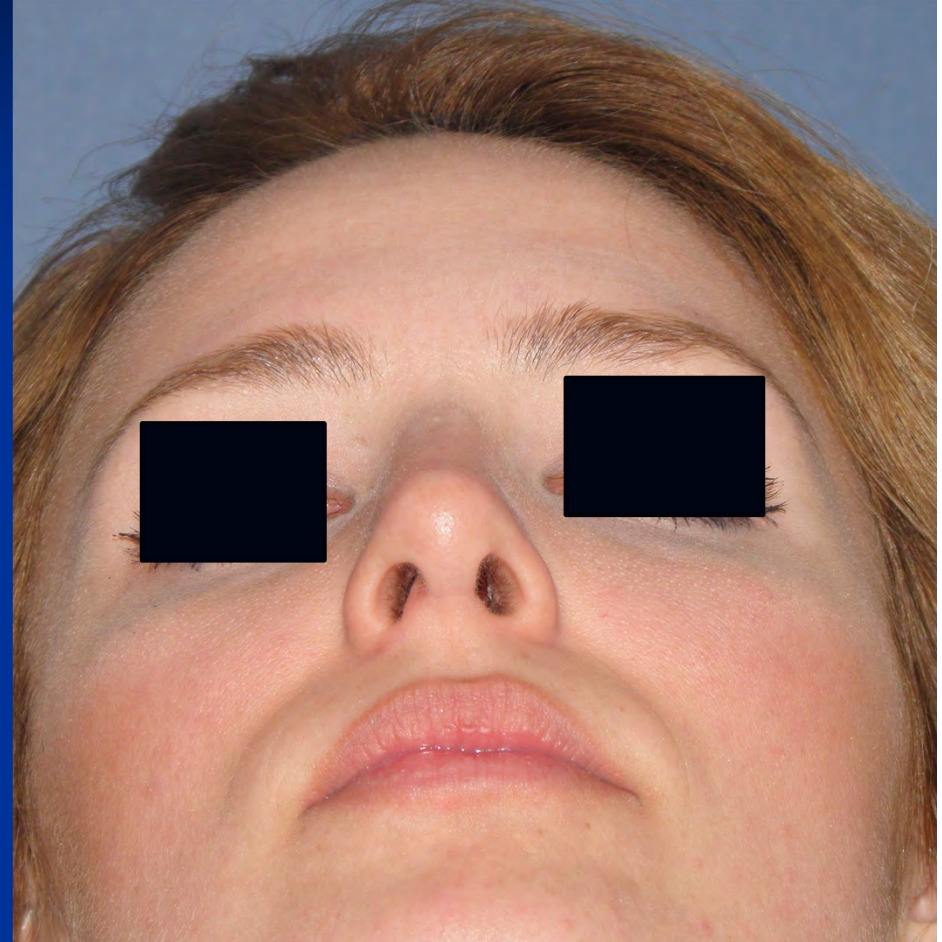
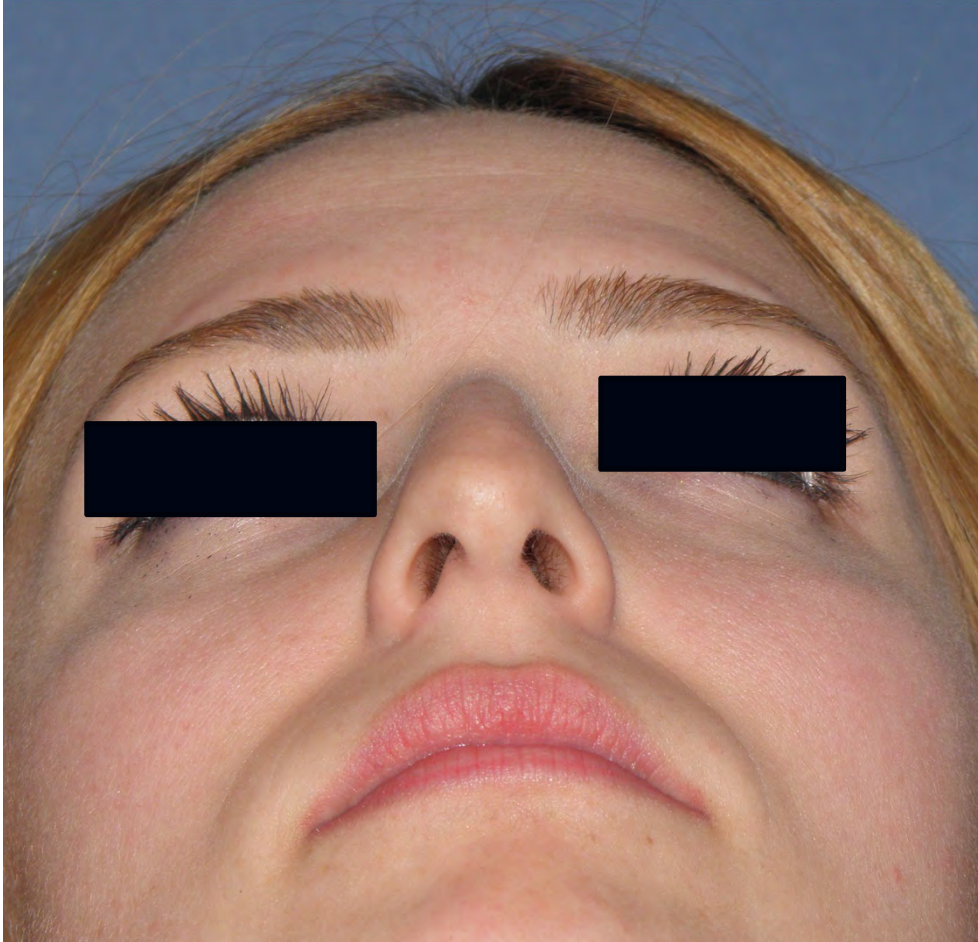
Copyright reserved. Authorised use for  
SET trainees in PRS.

# POSTOP. 18 MONTHS



# POSTOP. 18 MONTHS





PRS Registrar's Conference  
2013

Copyright reserved. Authorised use for  
SET trainees in PRS.

# THANK YOU...