



Australian Society
of Plastic Surgeons

ABDOMINOPLASTY

Hugh Bartholomeusz

Disclaimer

- The copy in this file is protected by the copyright of the author or authors. Consent was provided for the express purpose of educating attendees of the 2012 Registrar's Conference in Brisbane.
- You **MAY NOT** copy or distribute the contents or images in any form.
- You **MAY PRINT** the document for your own personal use as an educational resource.

History

1910	Kelly	Abdominal Contouring
1967	Pitanguy	Abdominal Lipectomy
1972	Regnault	W Technique
1978	Psillakis	External Oblique Plication
1988	Matarasso	Anatomical Contour Surgery
1995	Lockwood	High Lateral Tension



Patient Presentation

Excess Skin and Subcutaneous Tissue re Pregnancy

Weight Loss with or without Bariatric Surgery

Rectus Muscle Divarication without excess skin



Patient History

- Pregnancies
- Surgery and Scar formation
- Medical Co-morbidities
- Smoking
- Aesthetic Expectations
- Social Situation

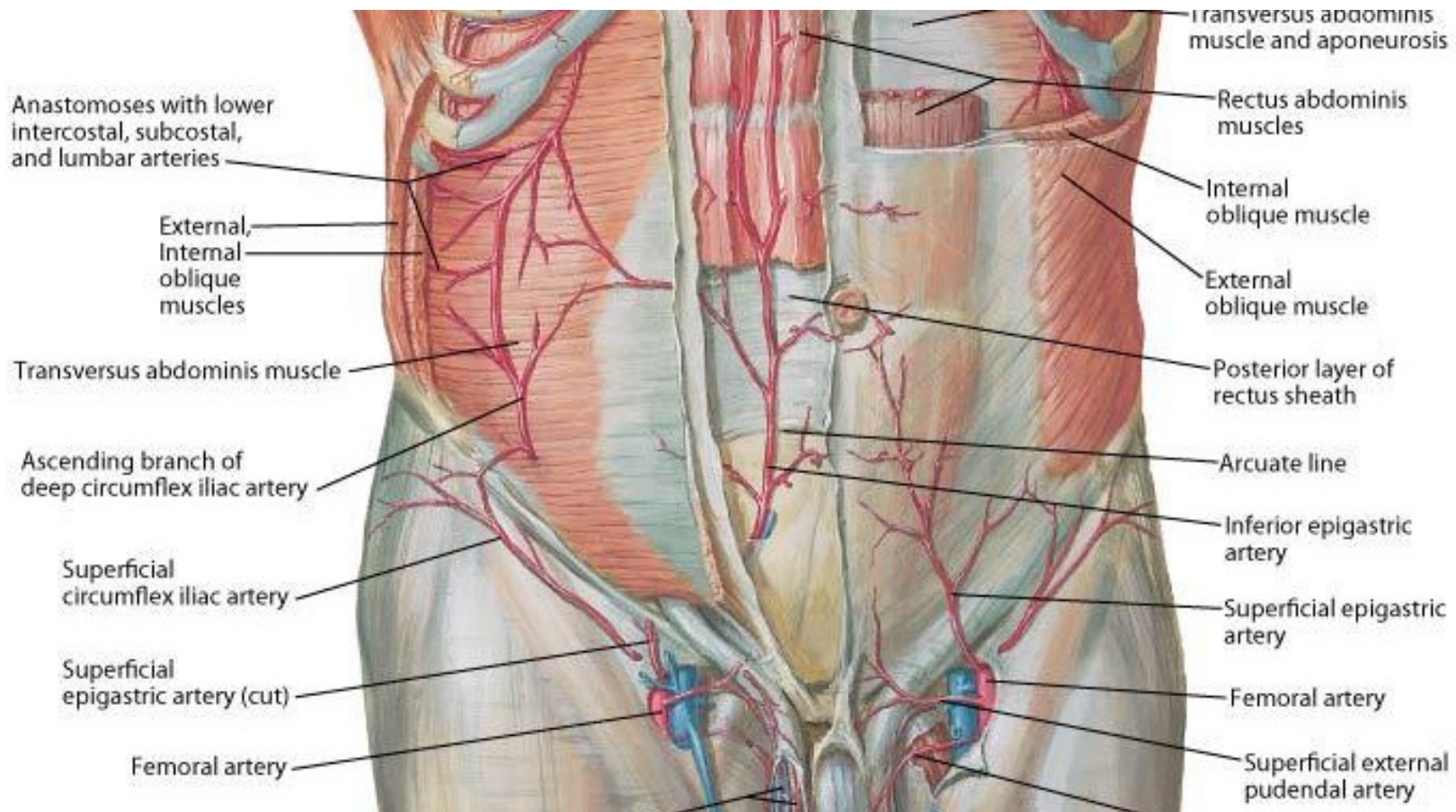


Examination and Tests

- Abdominal Contour especially scarring
- Rectus Divarication
- Skin Quality
- Blood Tests FBC / ELFTs
Coagulation Screen



Anatomy



Pre-Operative Planning

- Consultation
 - Documentation of Potential Complications
- Cooling Off Period and Second Consultation
- Nursing Pre-Op Consultation
- Photographs
- Incision Marking



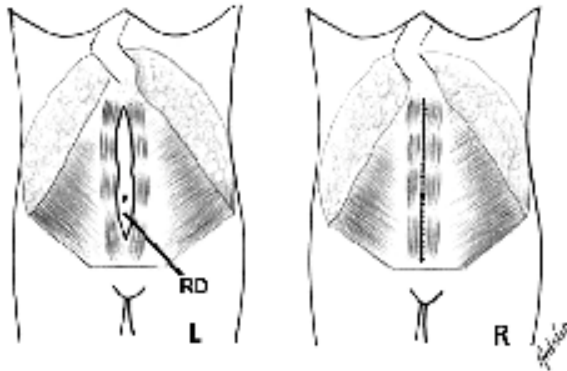
Operative Technique

- Standard Undermining/Rectus Plication
- Fleur-de-Lys
- Lockwood High Lateral Tension
- Supplementary Liposuction
- Incorporation into Body Lift

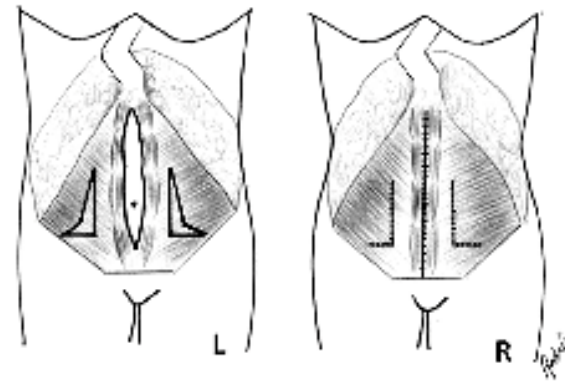


Muscle Deformities

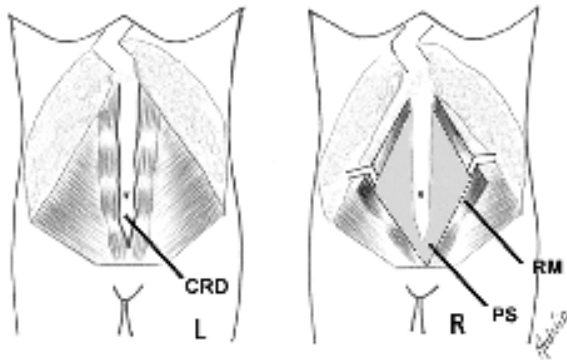
Type A



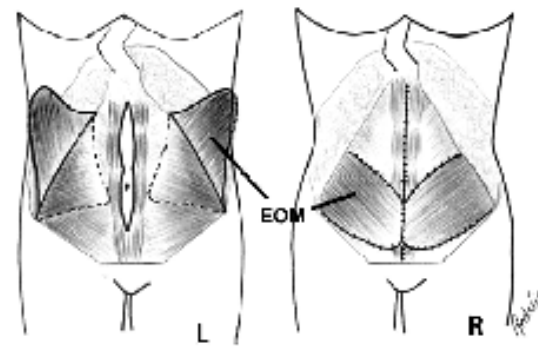
Type B



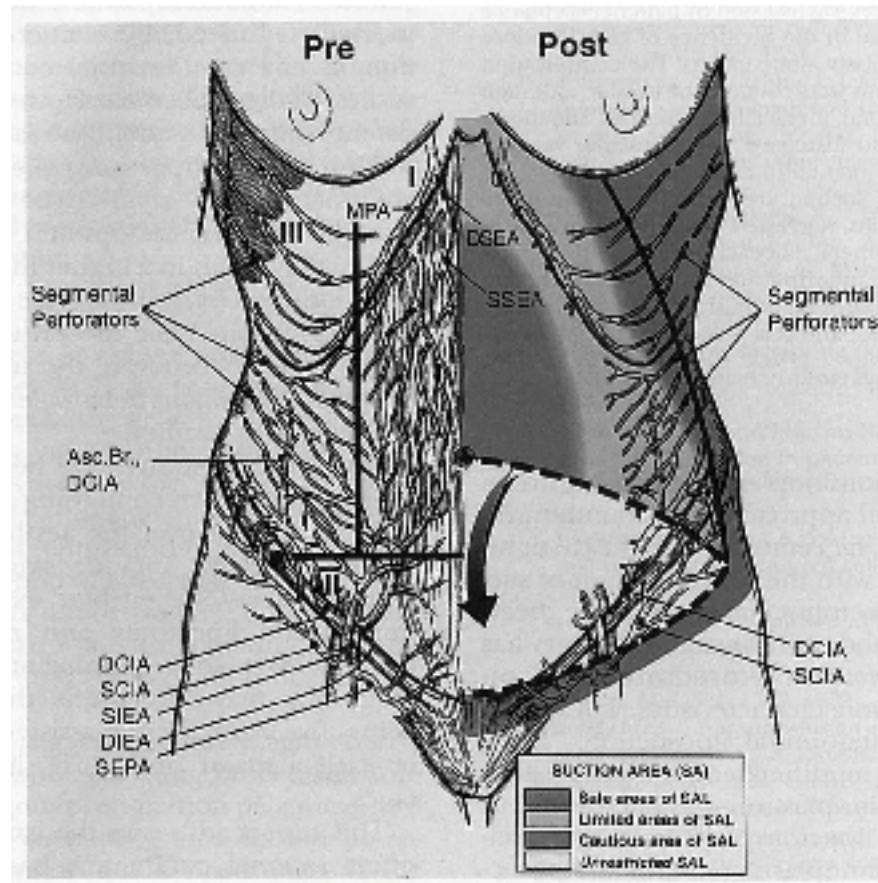
Type C




Type D



Liposuction



High Lateral Tension Abdominoplasty



Intra-Operative Considerations

- Positioning/ Table Break
- Warming Blanket
- Tumescence
- DVT Prophylaxis - TEDs / SCDs
- IV Antibiotics
- Dynastat
- Argon Coagulator
- Anti-Seroma Treatment - Tisseel / Artis
 - Quilting
- Suturing Technique
 - Rectus Plication
 - Wound Closure
- Drains
- Dressings

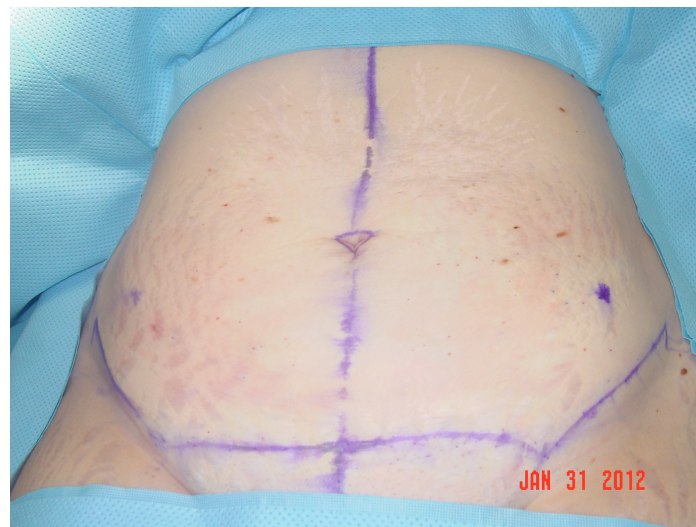
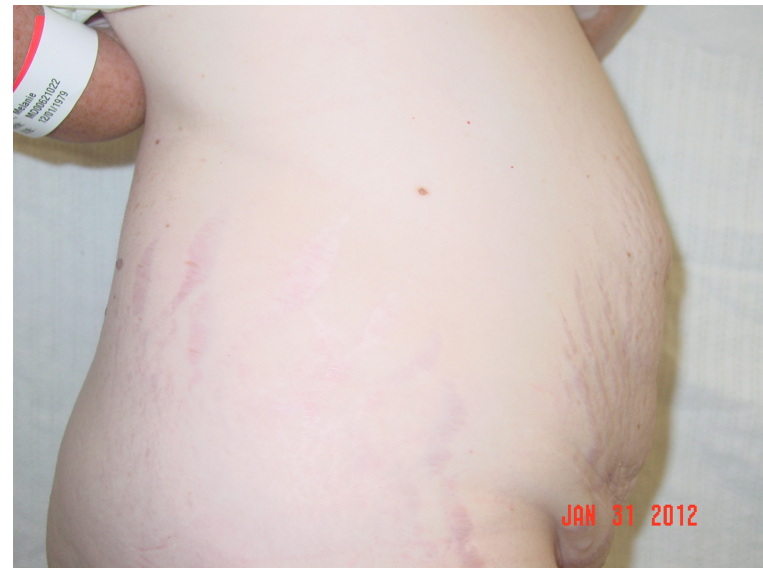
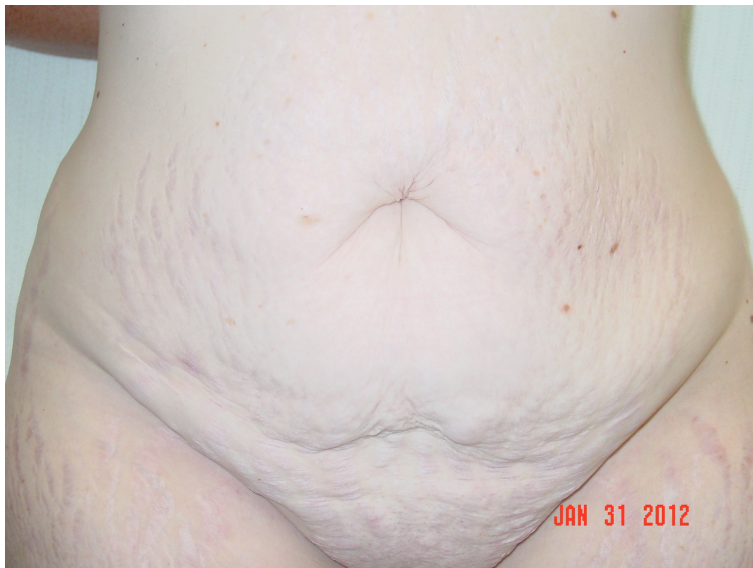Umbilicoplasty

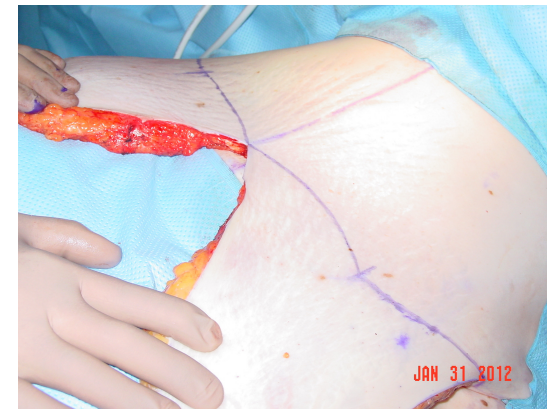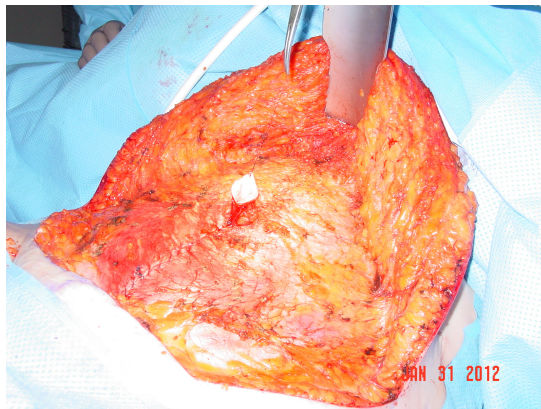
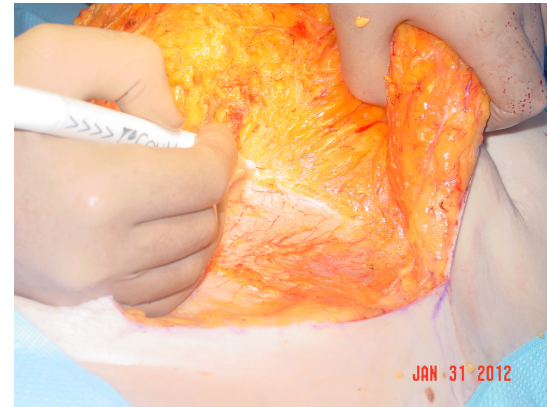
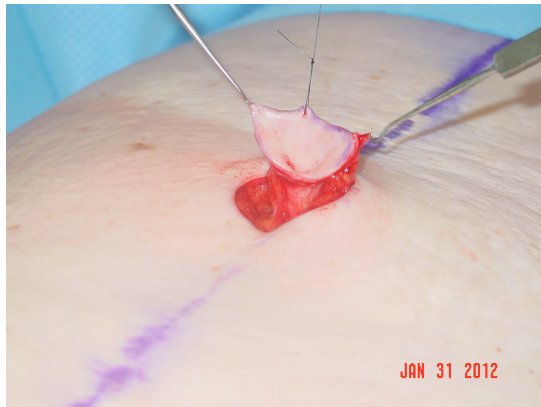- Position of Neo Umbilicus
- Reception Area Incision
- Re-fashioning Procedures



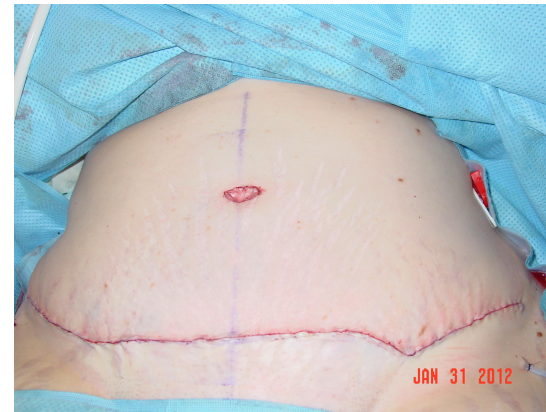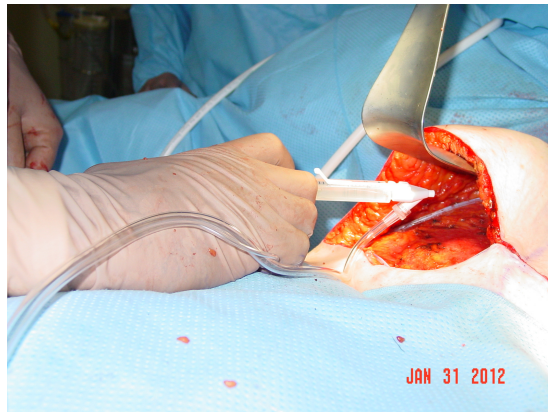
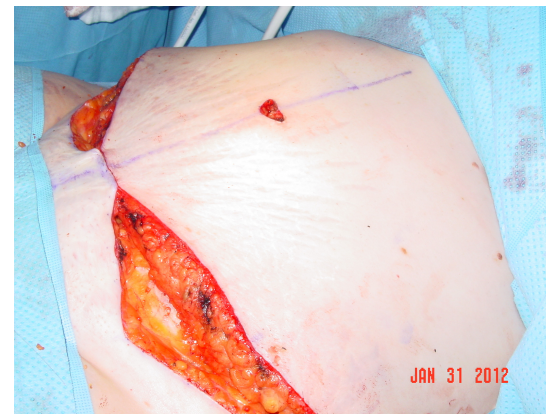
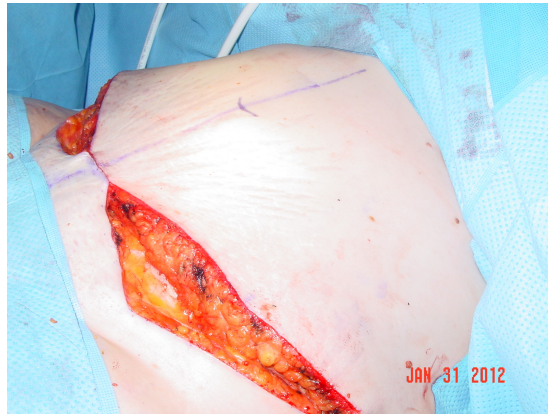Procedure



Procedure



Procedure



Post-Operative Care

- Inpatient/ Day Surgery
- Analgesia
- Anti-emetics
- Thromboprophylaxis - Mechanical
- Chemical
- Antibiotics
- Mobilization/Deep Breathing



Complications

- Immediate
 - DVT
 - Haematoma
 - Fat Embolus
- Early
 - Infection
 - Skin/Umbilical Necrosis
 - Seroma
- Late
 - Poor Scarring
 - Asymmetry
 - Numbness
 - Recurrent Rectus Diastases
 - Patient Dissatisfaction
(Mismatched Expectations)



RESOURCES

- Liposuction as an Adjunct to a Full Abdominoplasty

Matarasso PRS 95 (5) 1995

- High Lateral Tension Abdominoplasty with Superficial Fascial System Suspension

Lockwood PRS 96 (3) 1995

- An Aesthetic Classification of the Abdomen Based on the Myoaponeurotic Layer

Nahas PRS 108 (6) 2001

