

The contents of all presentations are password protected. The copy is protected by copyright of the Authors. Consent has been given for the express purpose of educating attendees of the March 2009 Registrars' Conference in Melbourne.

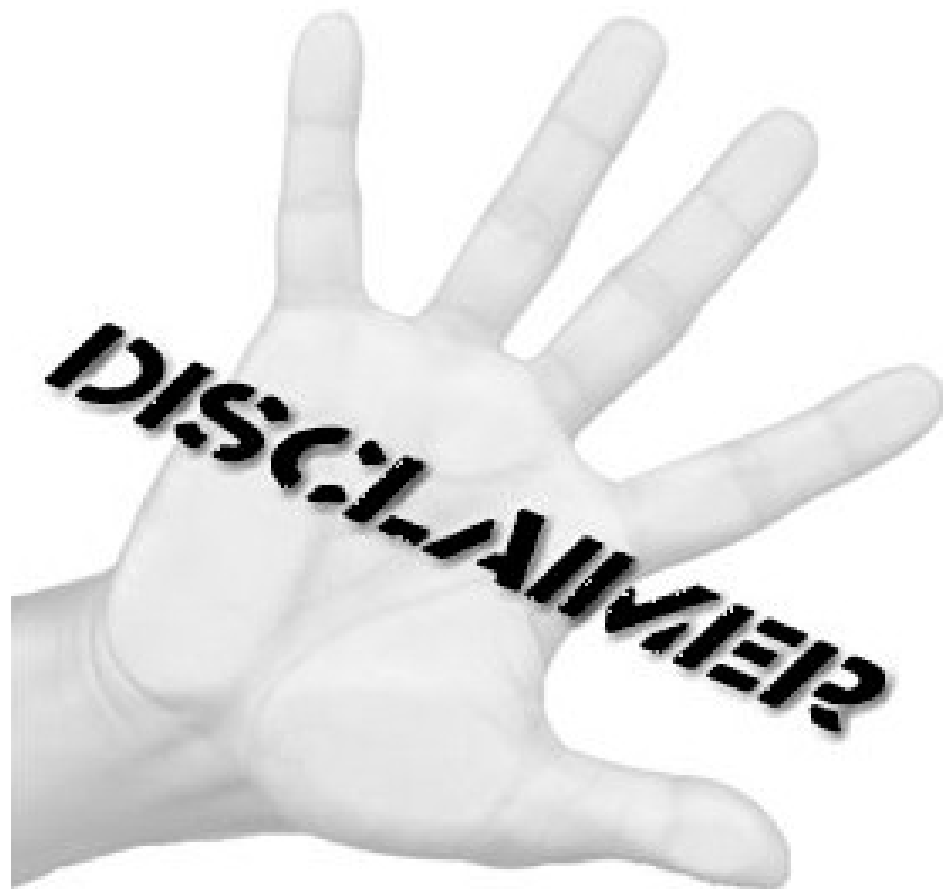You **MAY NOT COPY OR DISTRIBUTE** the contents or images in any form.

You **MAY PRINT** the document for your own personal use as an educational resource.

Implant and Technique Selection in Breast Augmentation



N Corduff FRACS

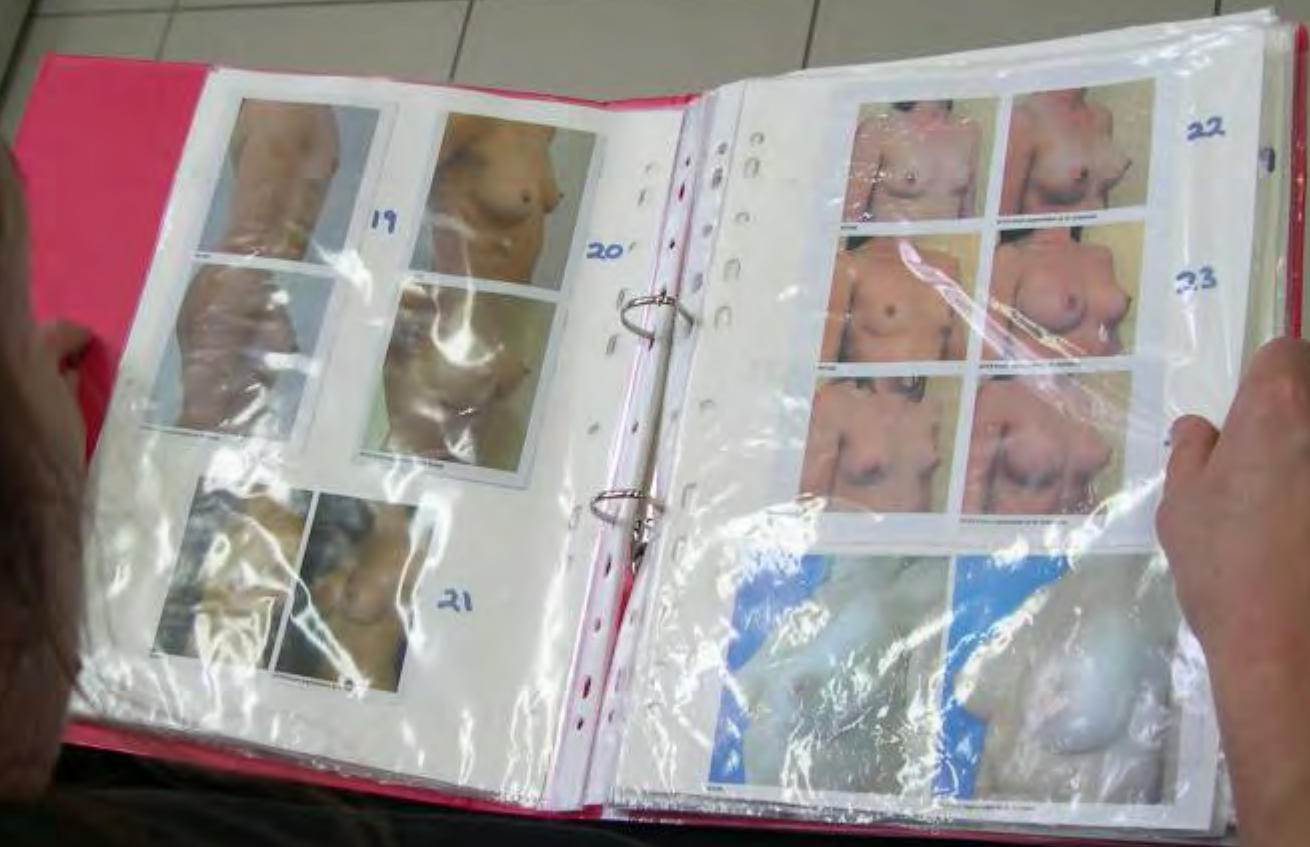

Breast Augmentation

The hardest part is deciding
technique selection and implant
selection

What does the patient want?





19

20

21

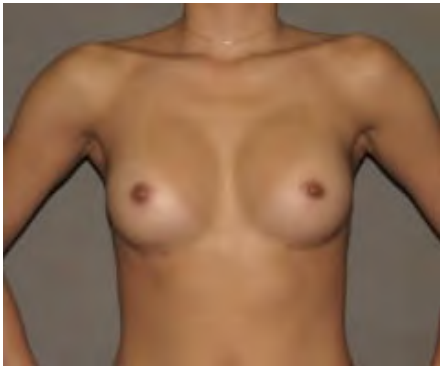
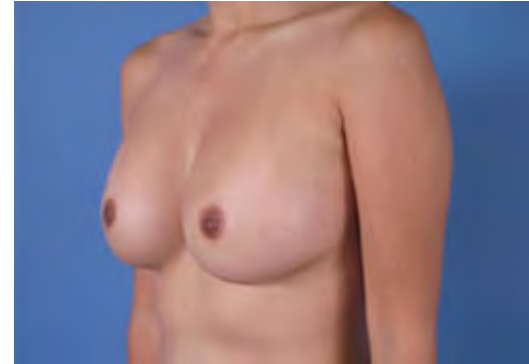22

23

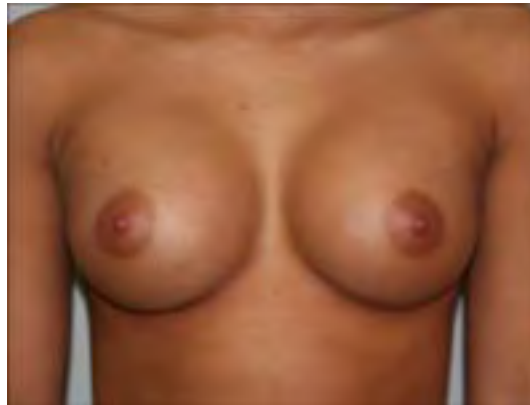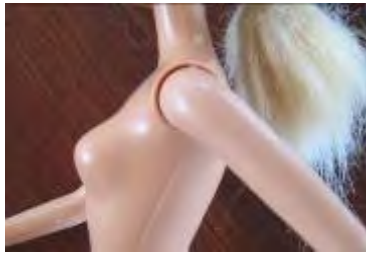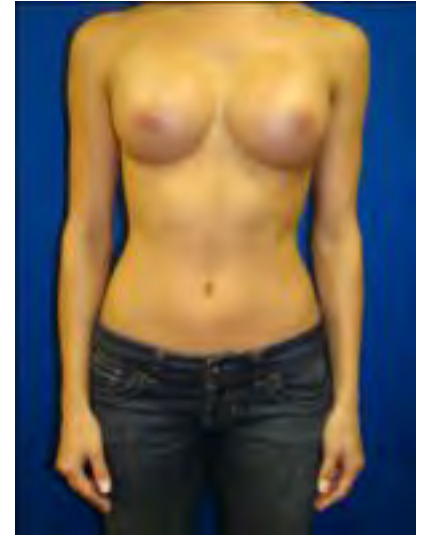Upper pole

- Slope
- Roundness
- Height to clavicle


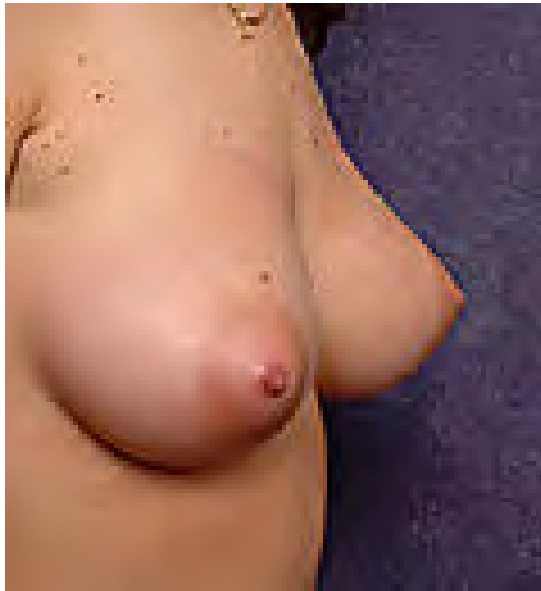
Texan Barbie



Round Upper Pole

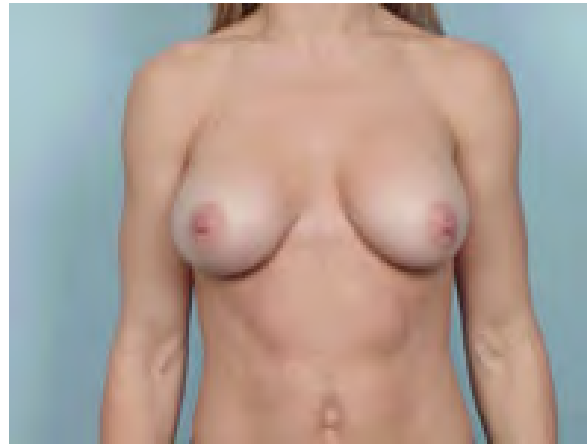
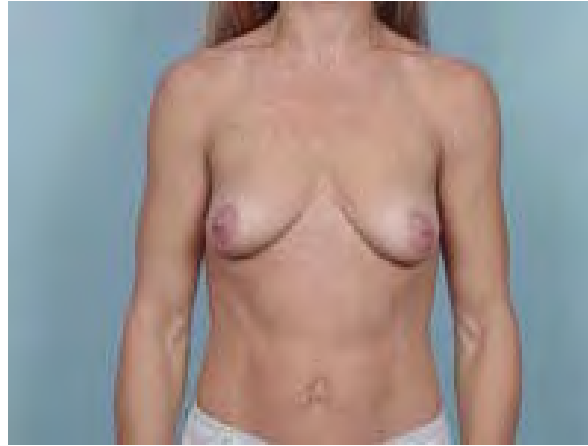
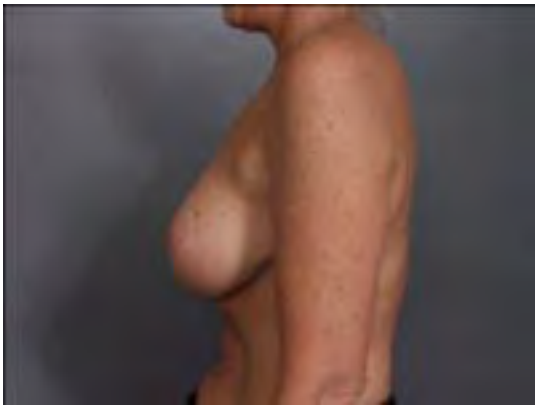
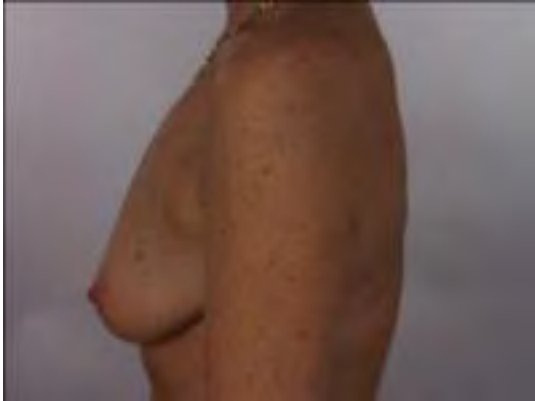French look



Lower Pole

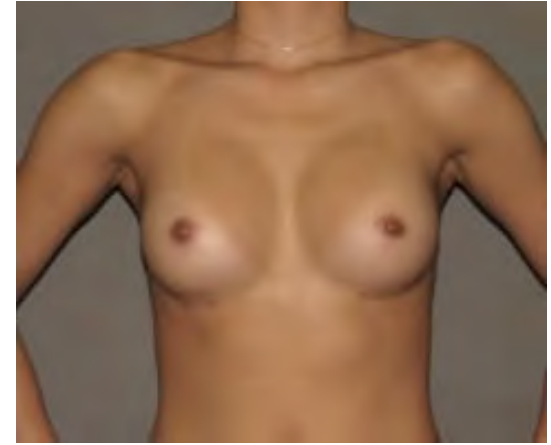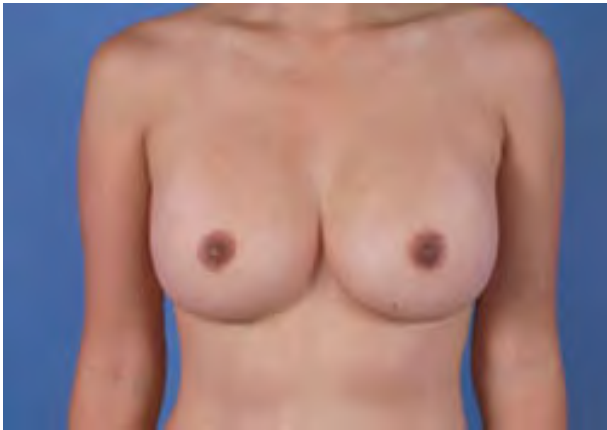- Ptosis



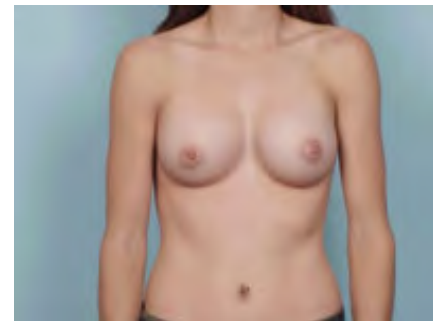
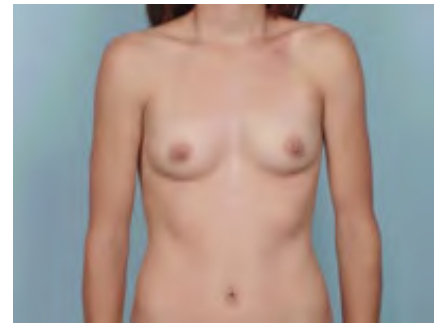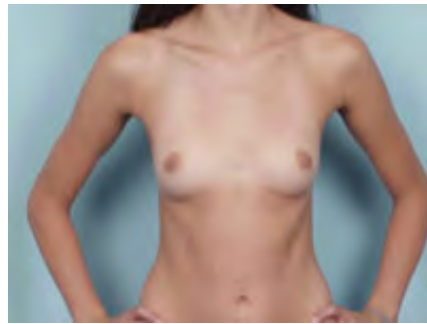Nipple position




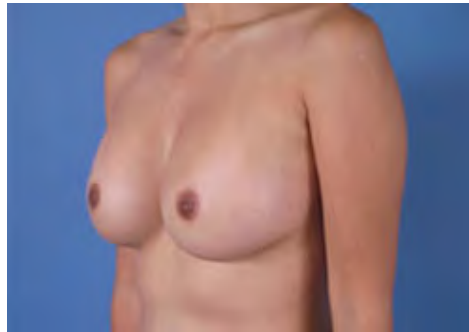
Cleavage



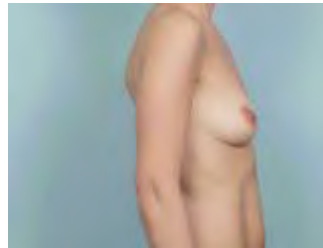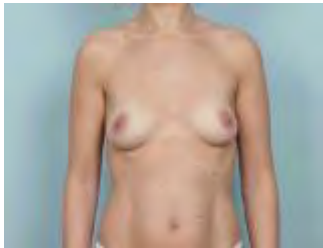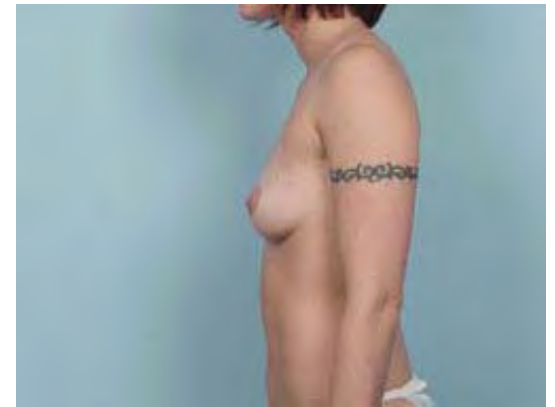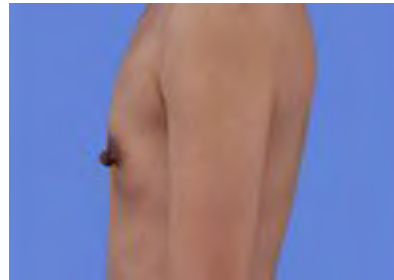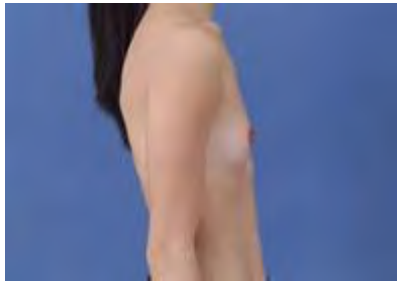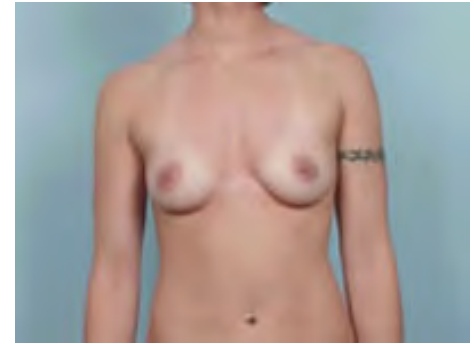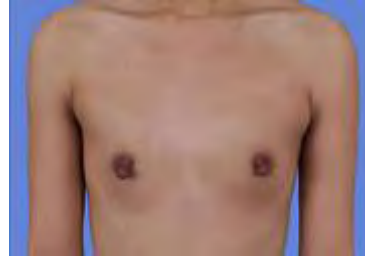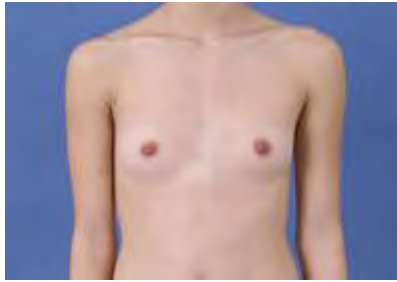Lateral width



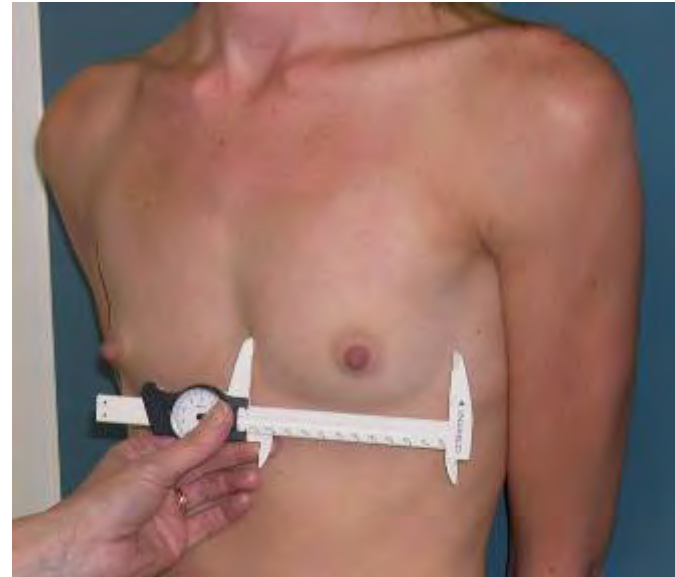
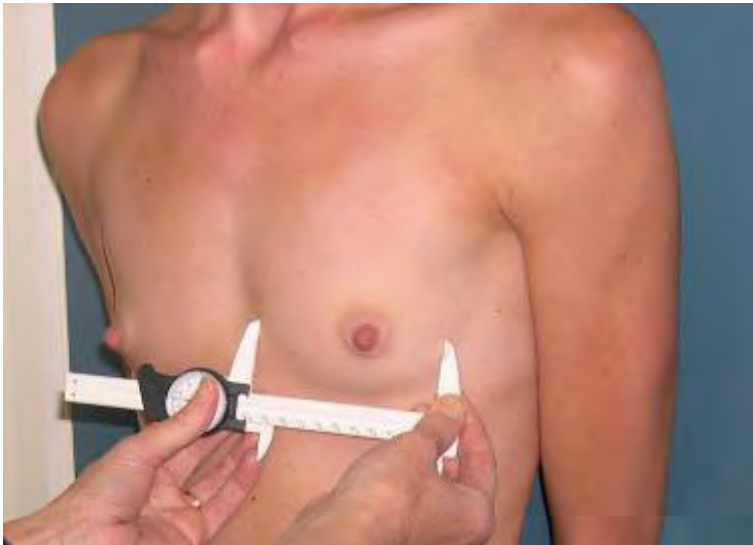Projection



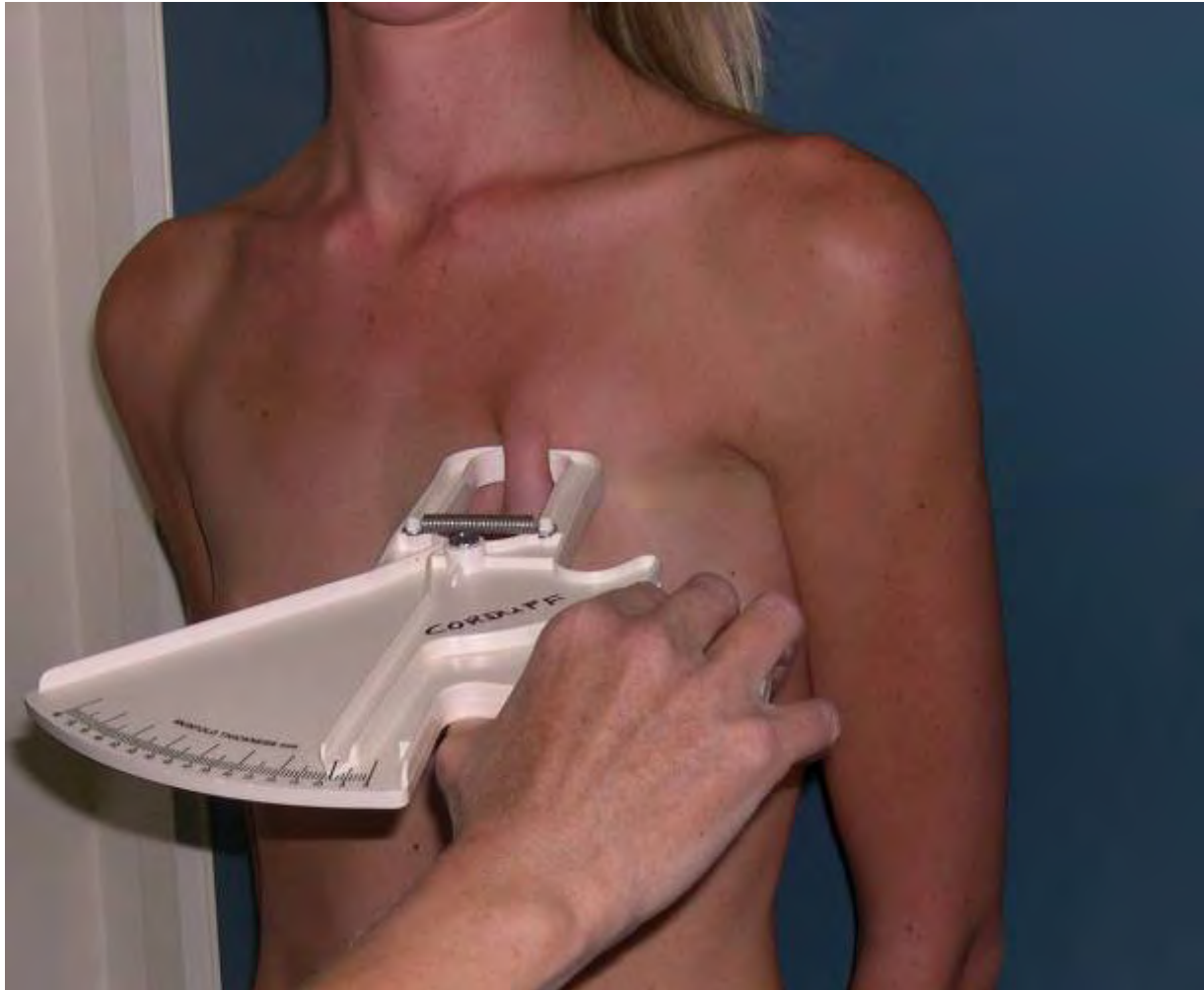What has the patient got?



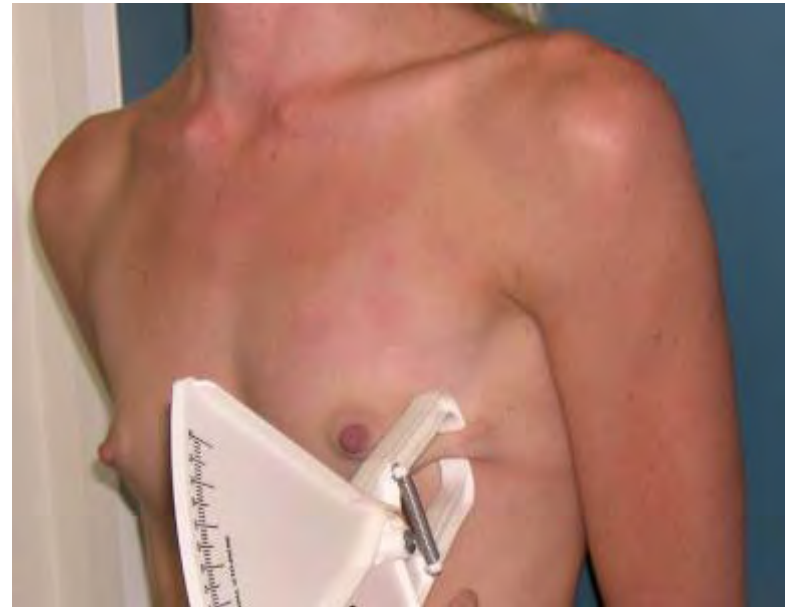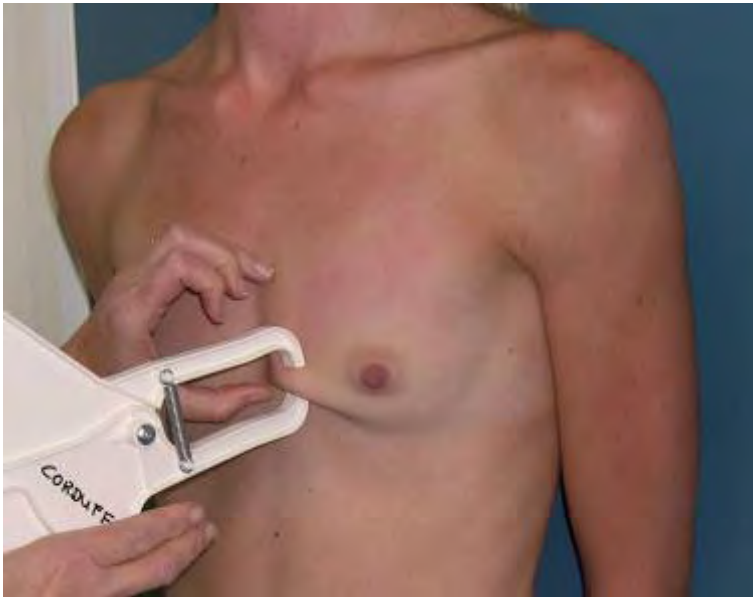
Base width



Upper pole coverage

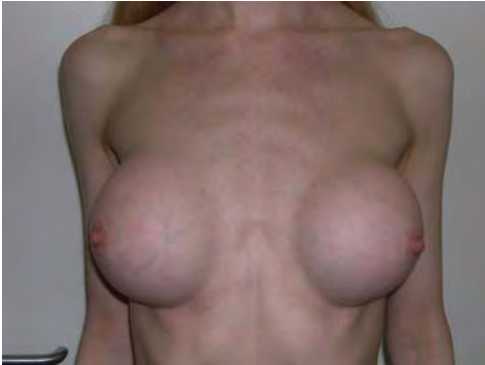
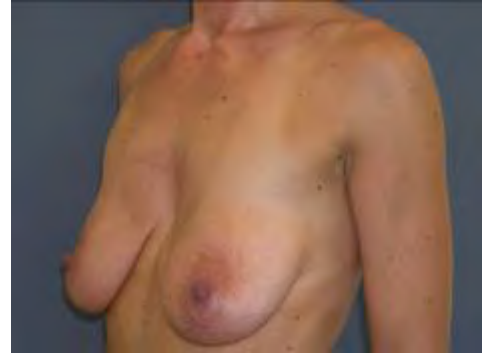
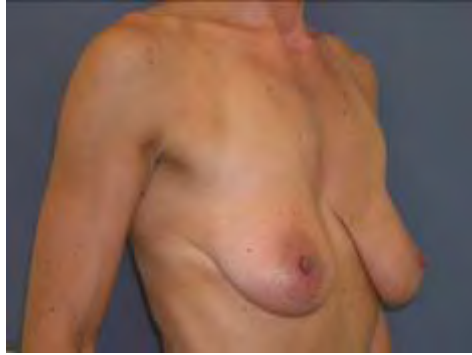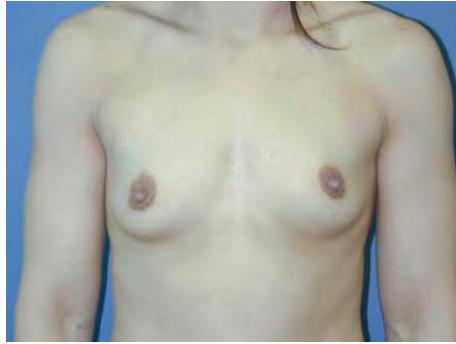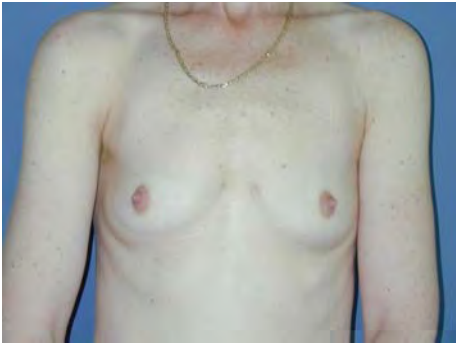Lower pole coverage

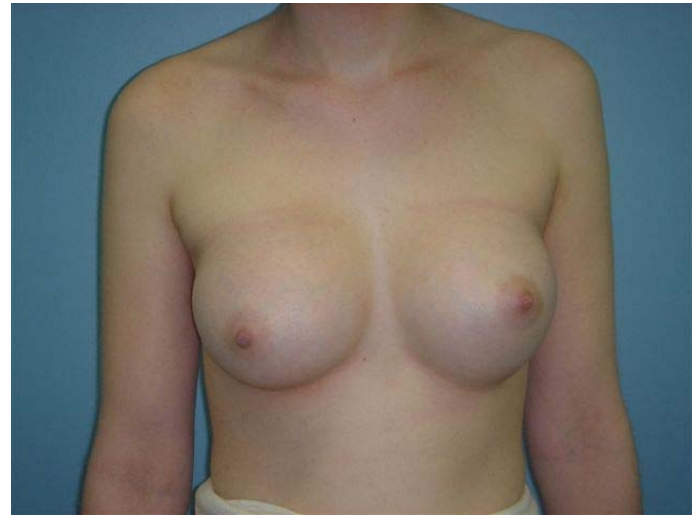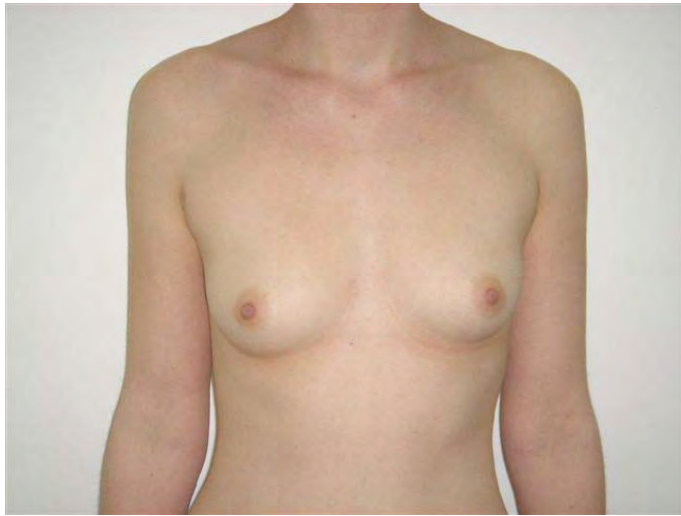


Chest wall

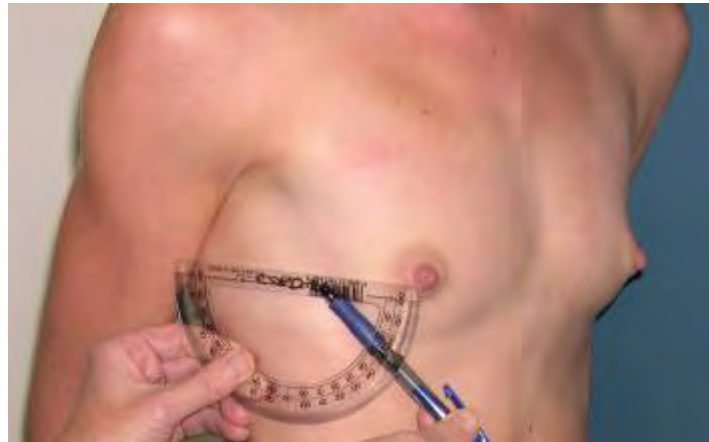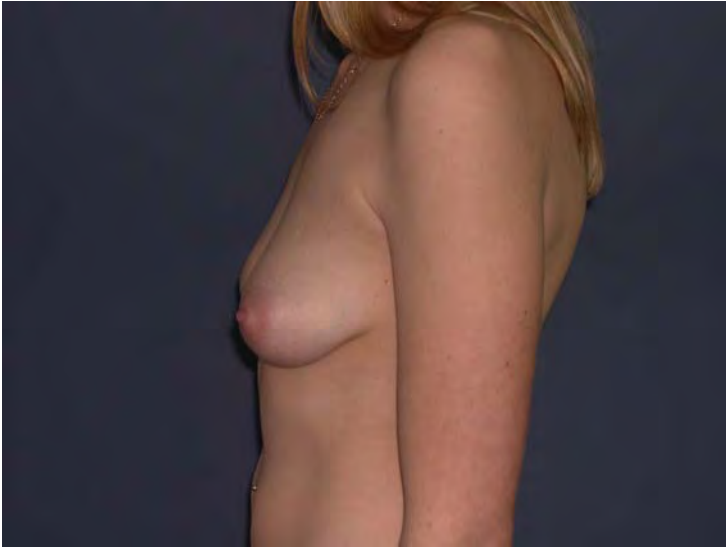- Scoliosis
- Prominent ribs
- IMF positions
- Shoulder heights



Nipple position



Glandular ptosis



Pectoralis activity



s1060705 www.fotosearch.com

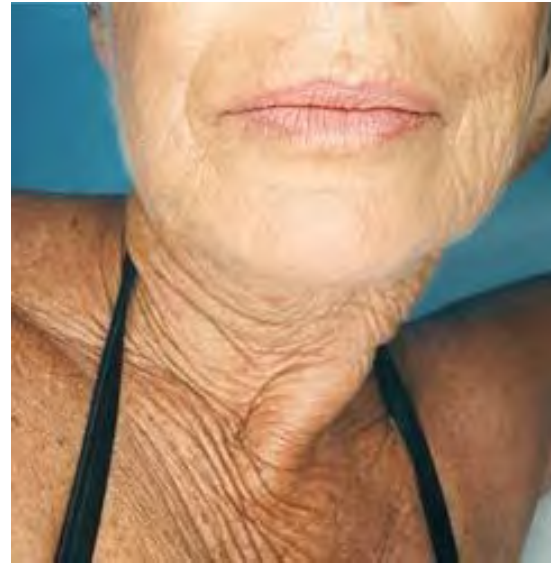


s1048953 www.fotosearch.com

Smoking



Skin quality



Other factors

- Expectations
- Other influences: partner, family, ethnicity
- Occupational requirements



Add volume

?where: implant selection

?how: technique selection



Negotiation

Compromise


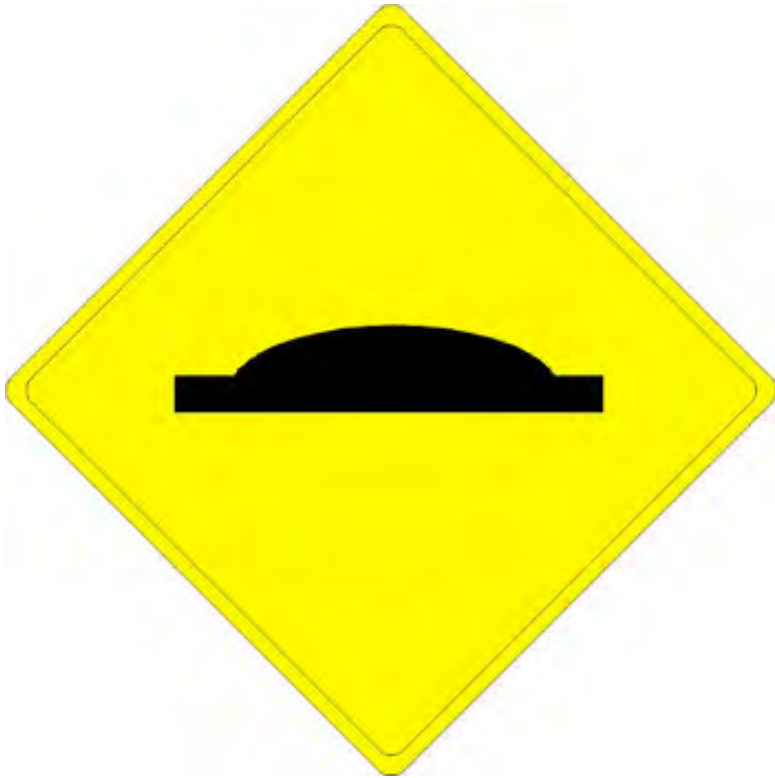




The Easy One

- Good symmetry
- Good coverage
- Good breast relationships

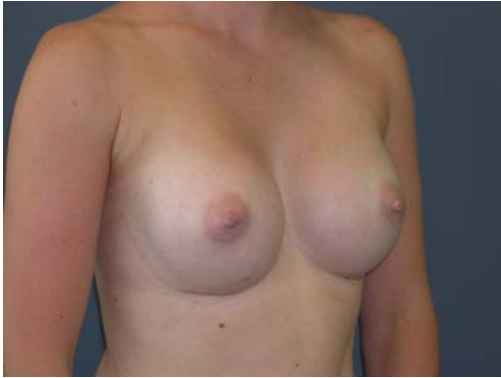
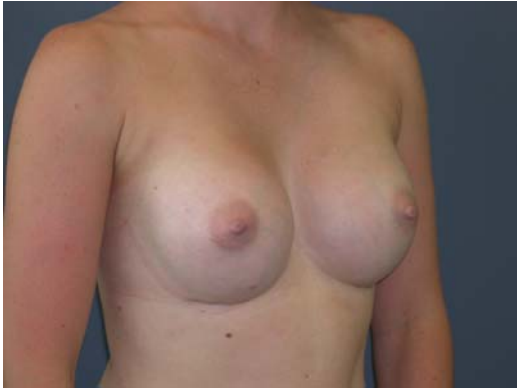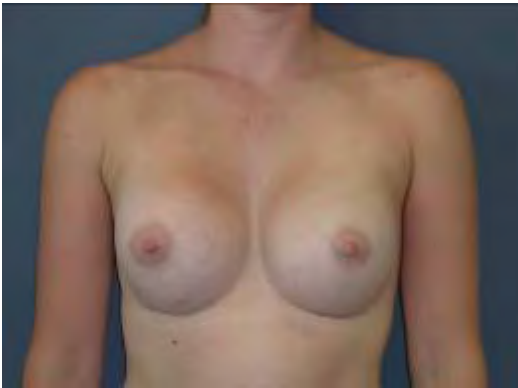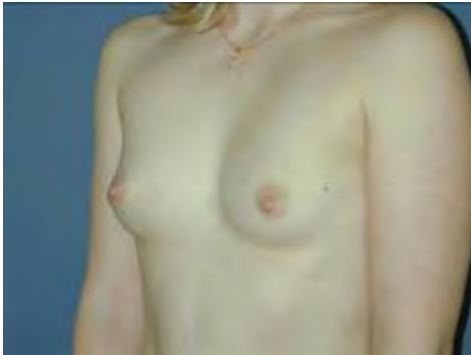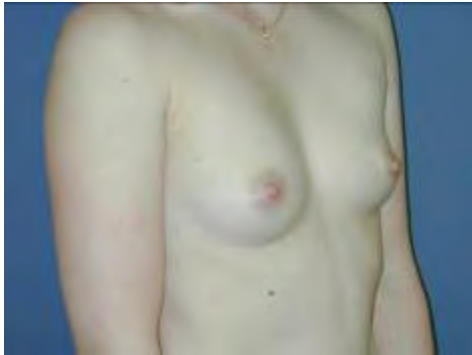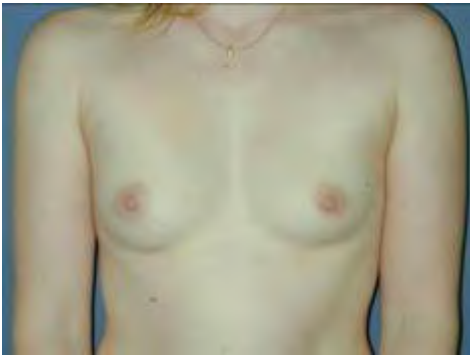Avoiding the speed hump



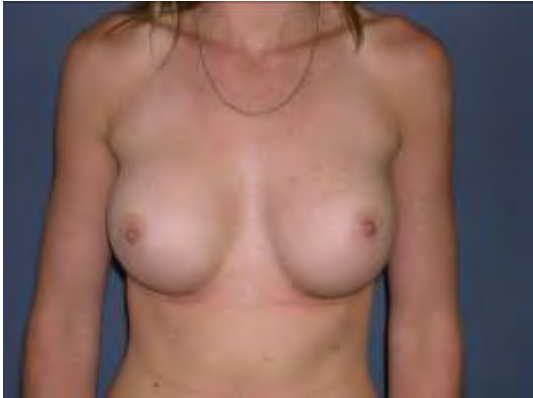
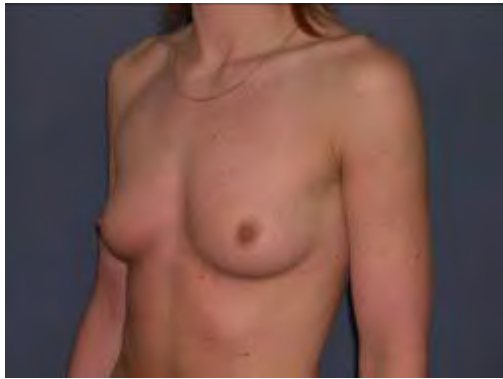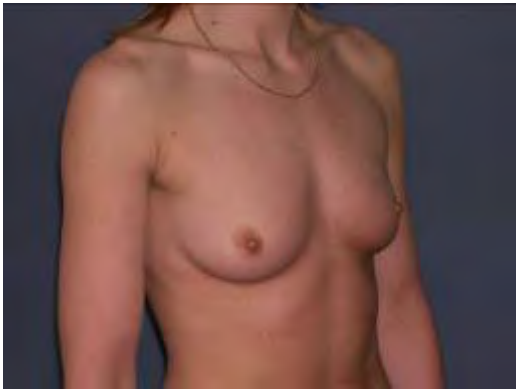
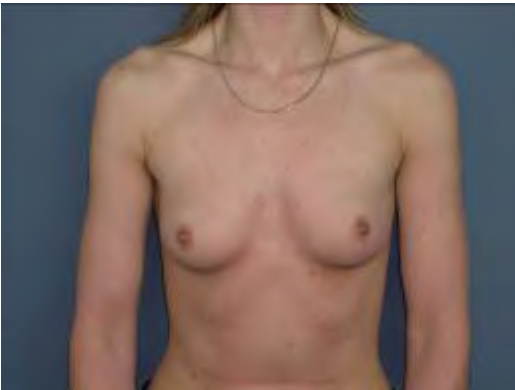The Easy One

- Good coverage, not too much projection:
 - Round pre-pectoral mod profile textured gel
- Less coverage:
 - subpectoral smooth gel
- Round upper pole
 - Subpectoral smooth HP gel
- Full projection, sloped upper pole
 - Anatomical pre or subpectoral (coverage)

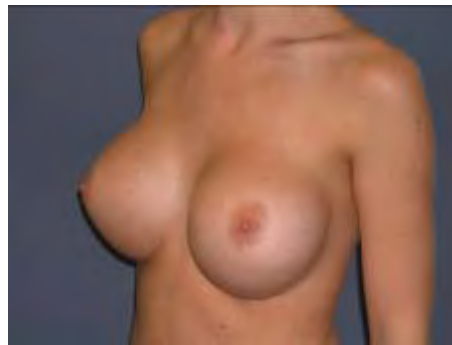
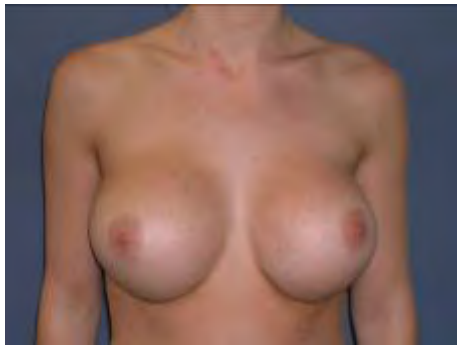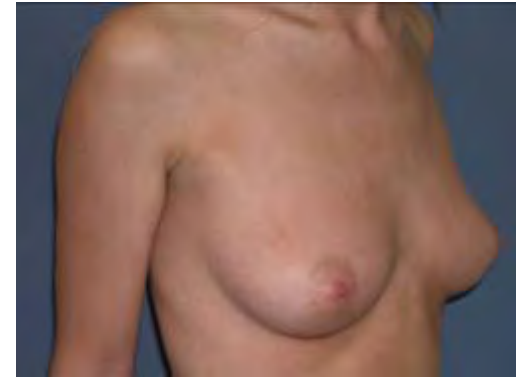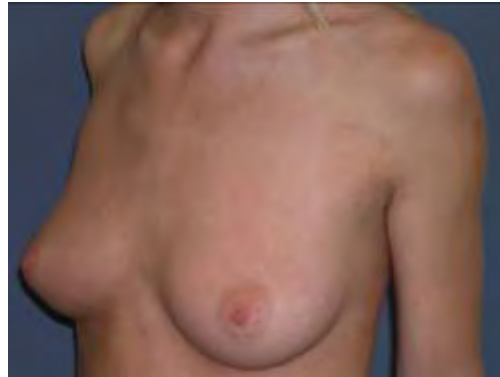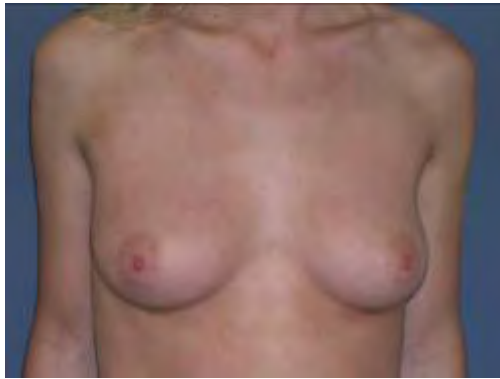round pre-pectoral moderate profile textured gel



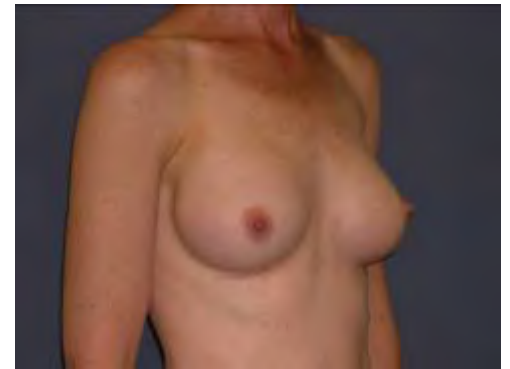
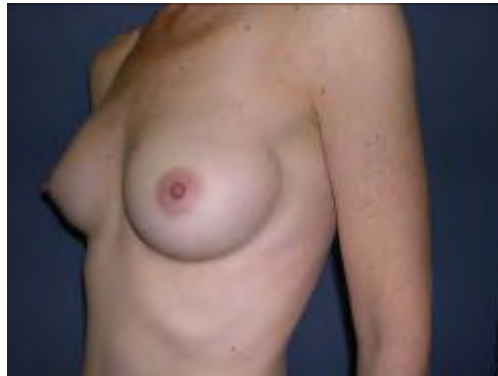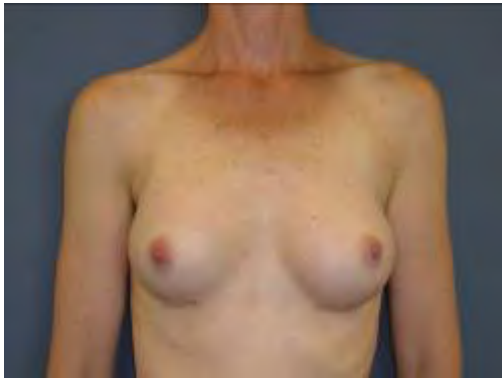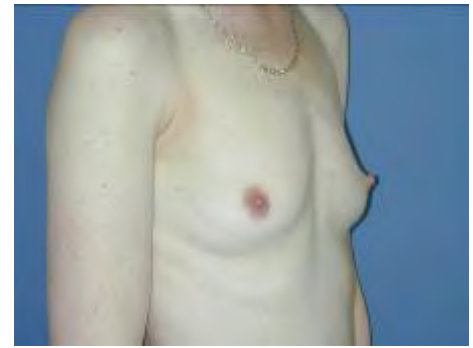
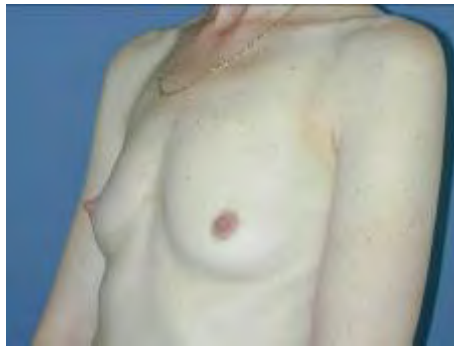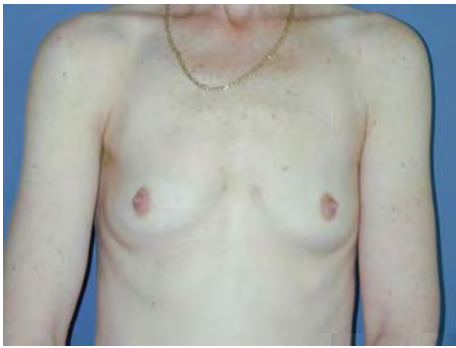round subpectoral moderate profile smooth gel



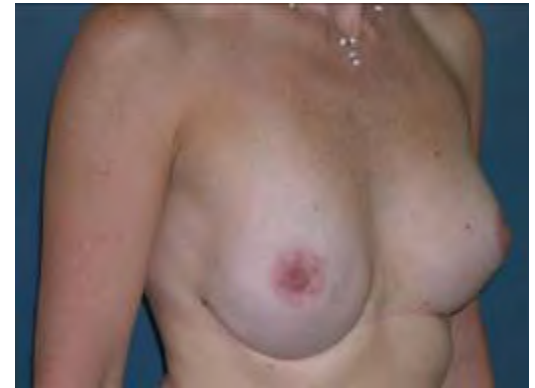
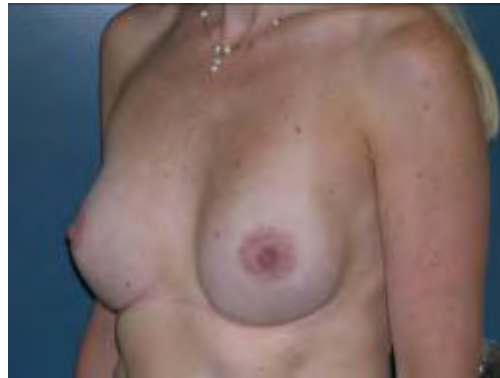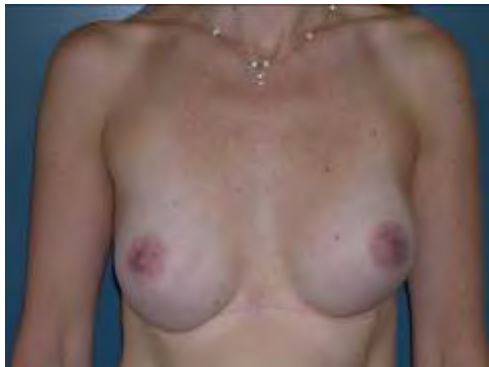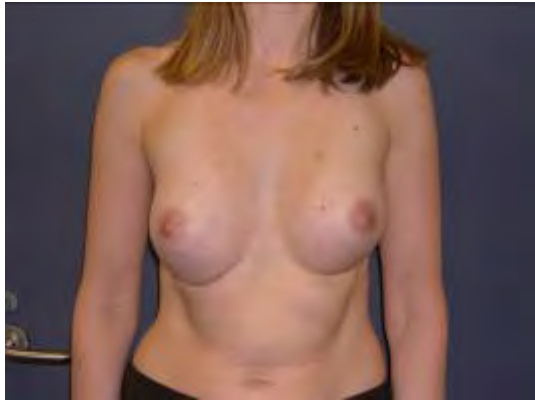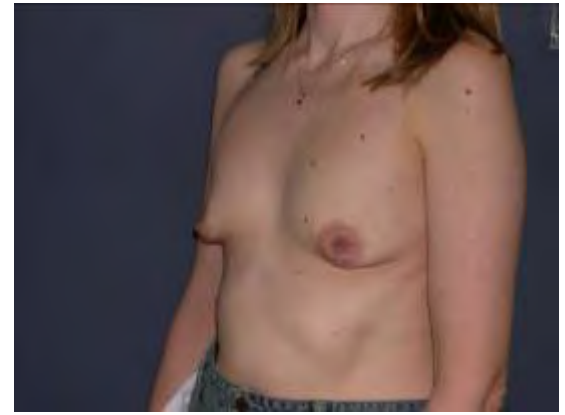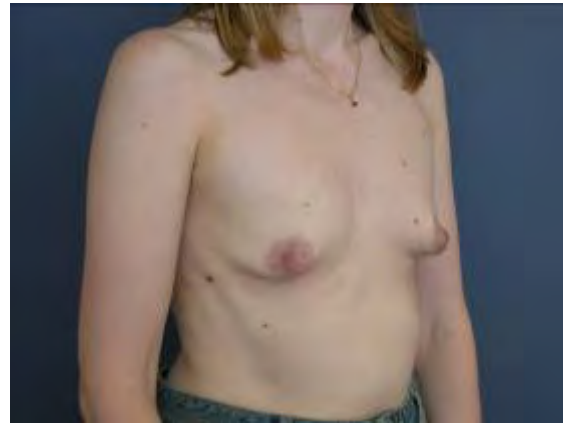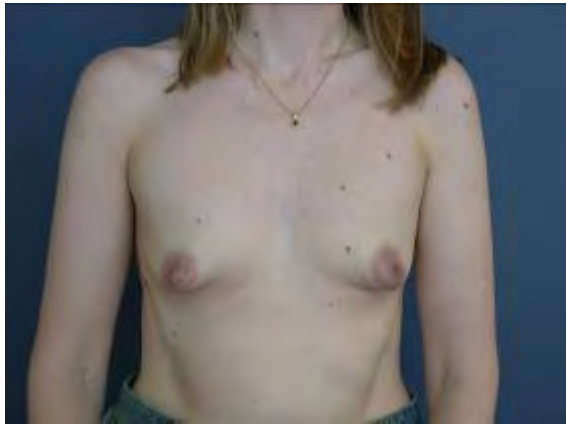round subpectoral high profile gel



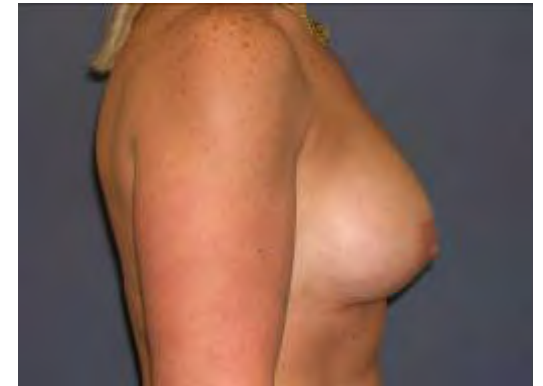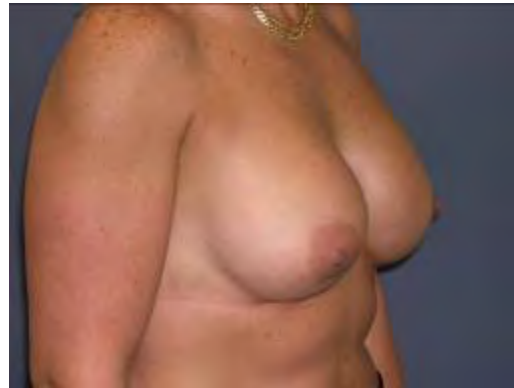
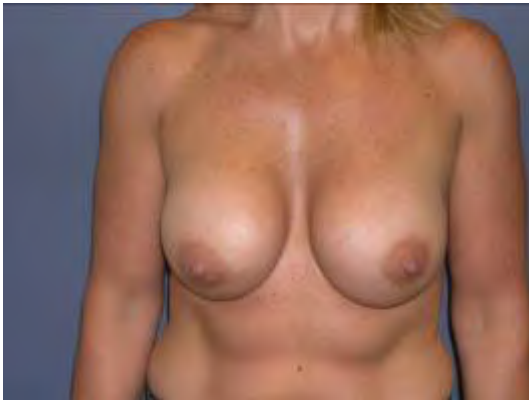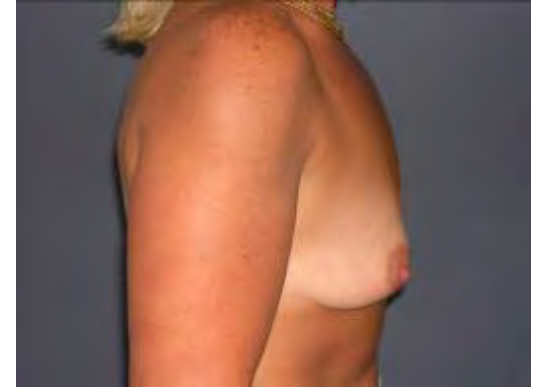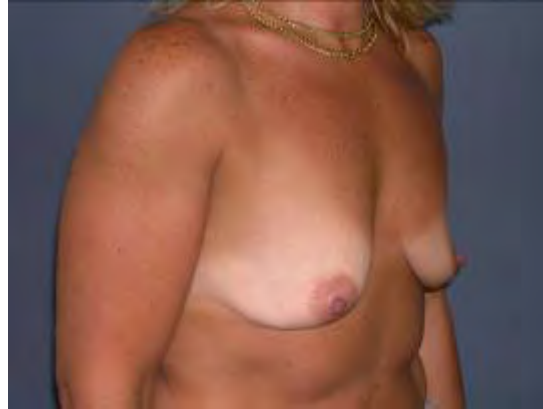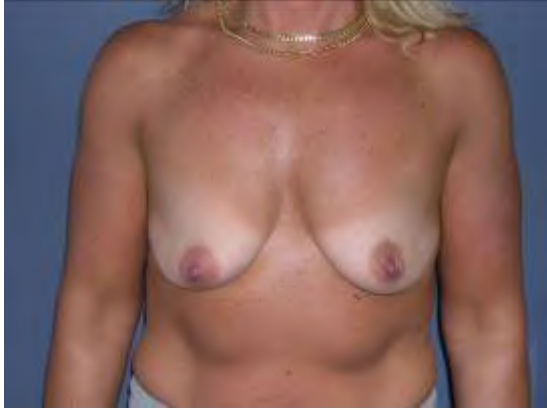High profile anatomical subpectoral



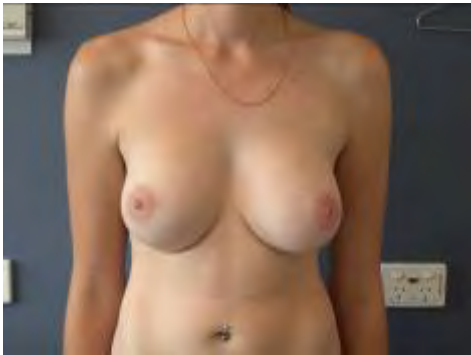
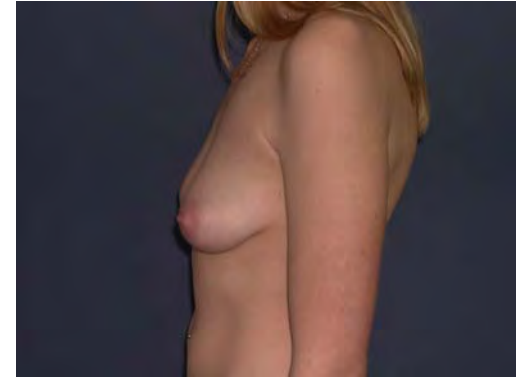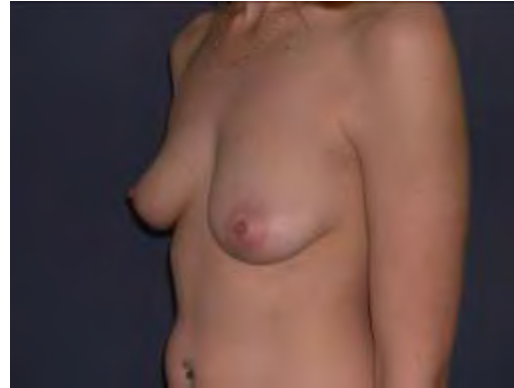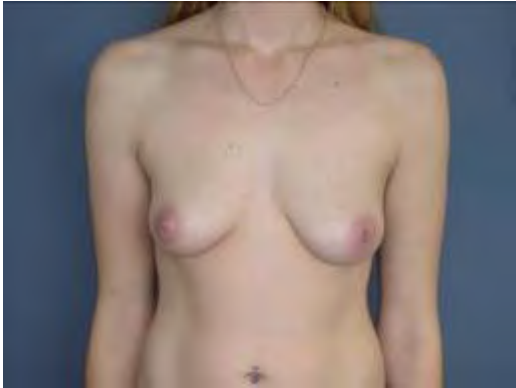Tight IMF



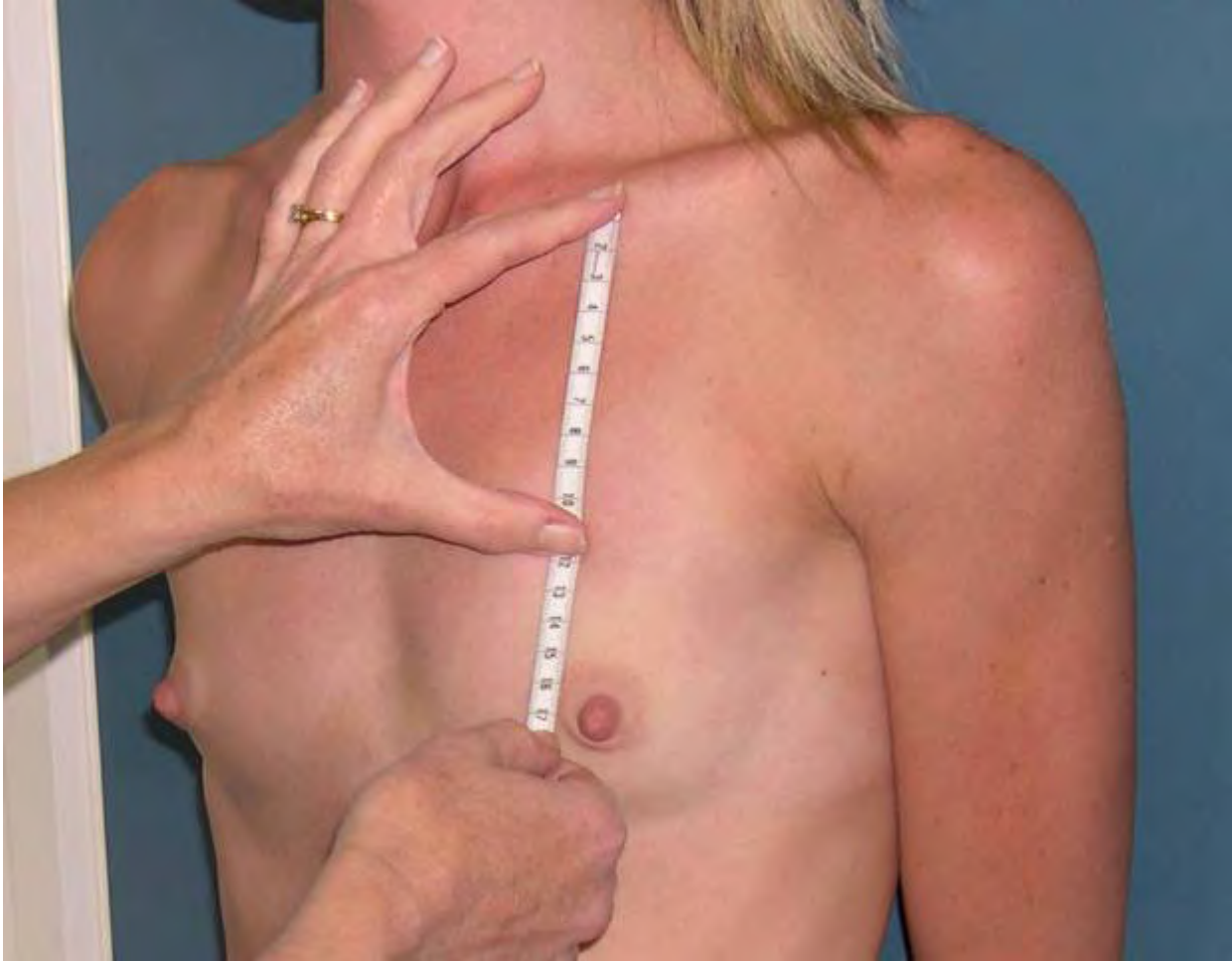?cheat or mastopexy



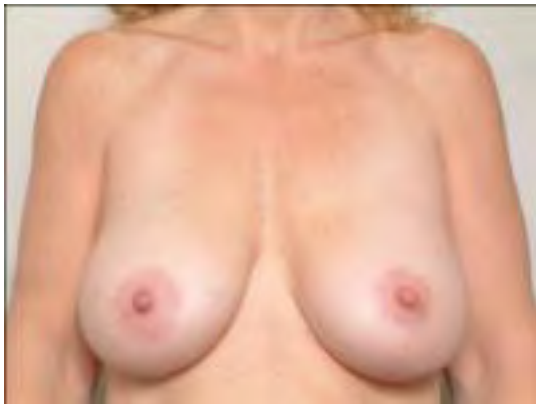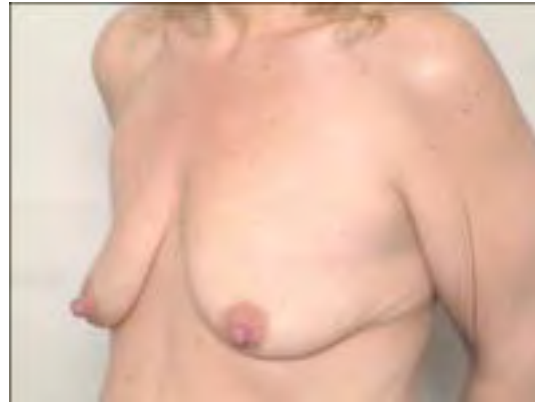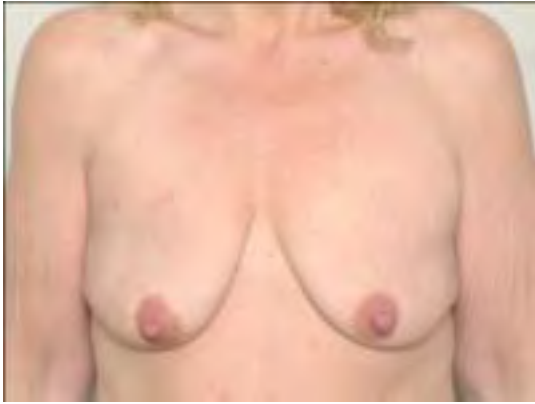?cheat or mastopexy

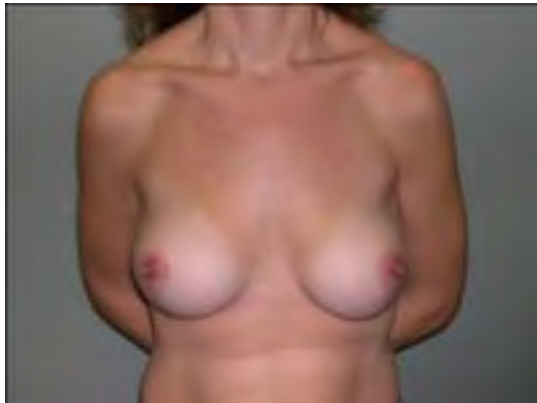
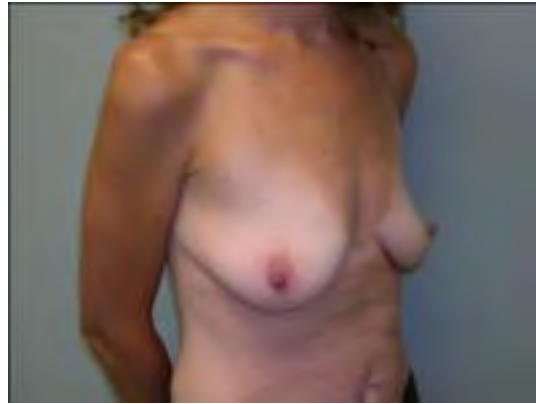
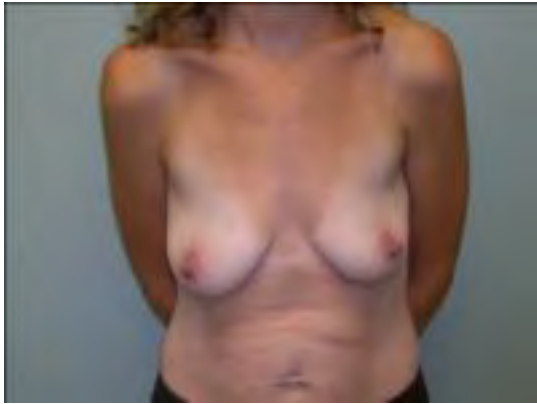?cheat or mastopexy



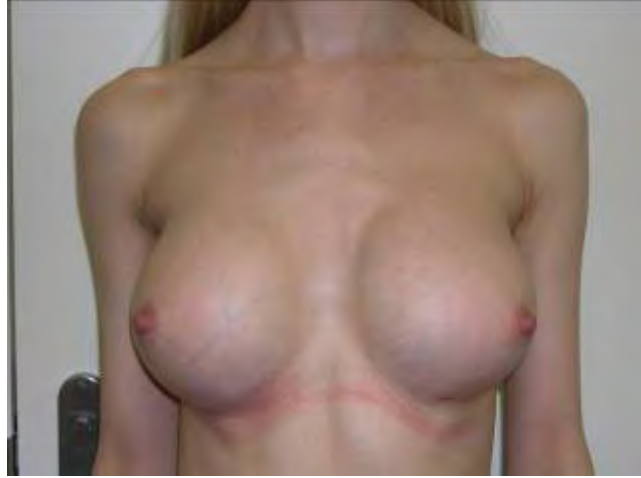
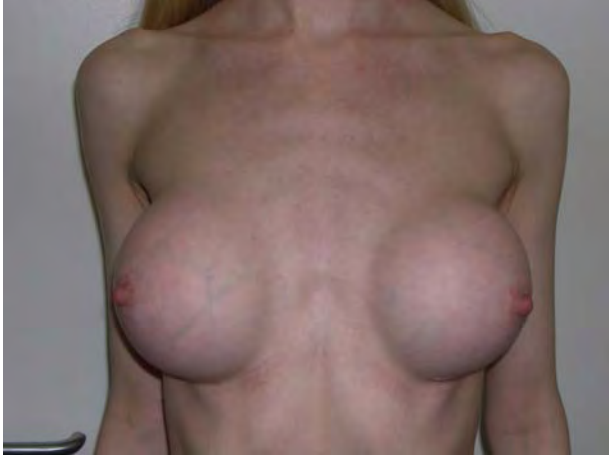?cheat or mastopexy





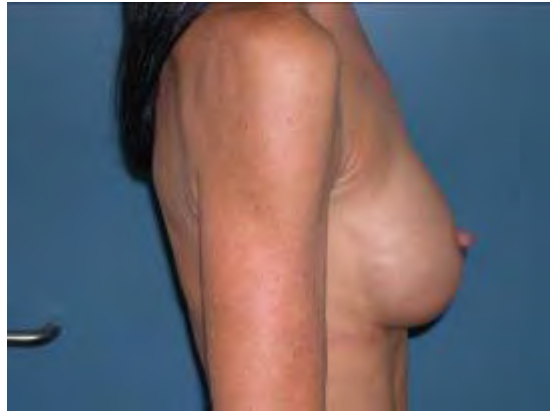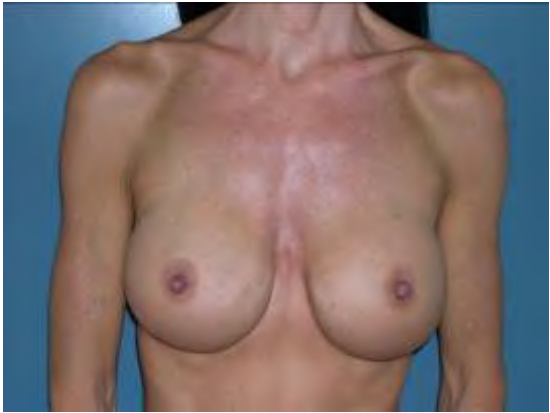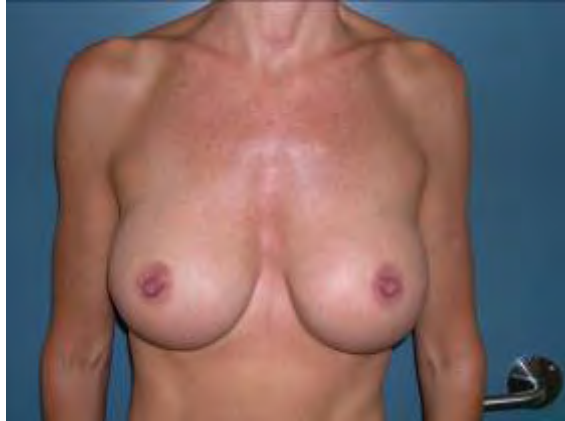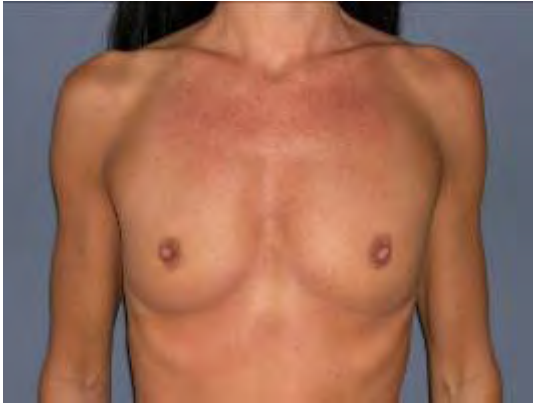Pigeon chest

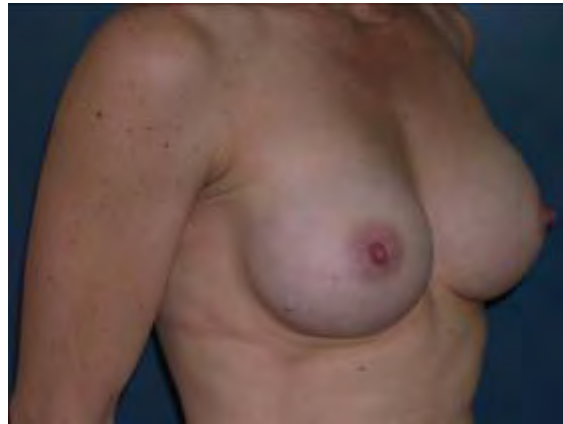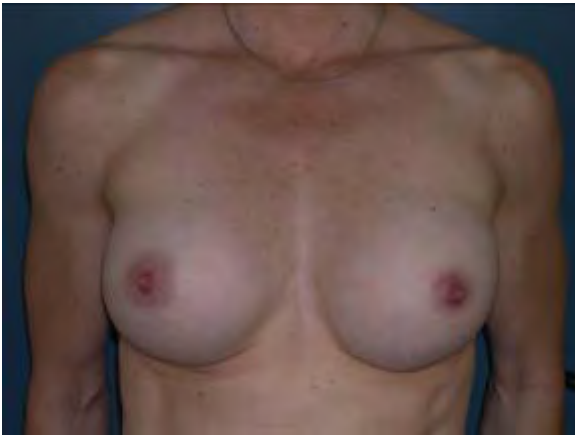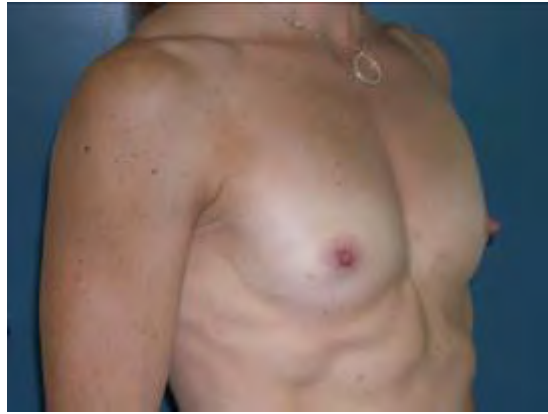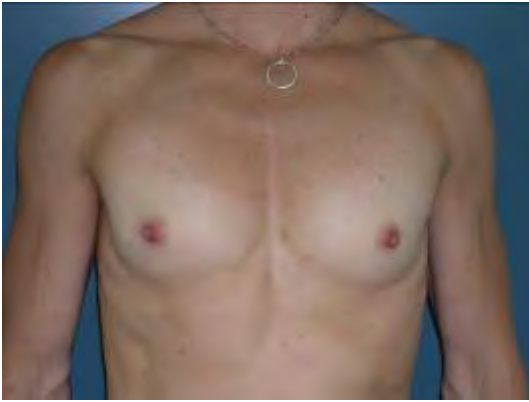Angled anatomical implants

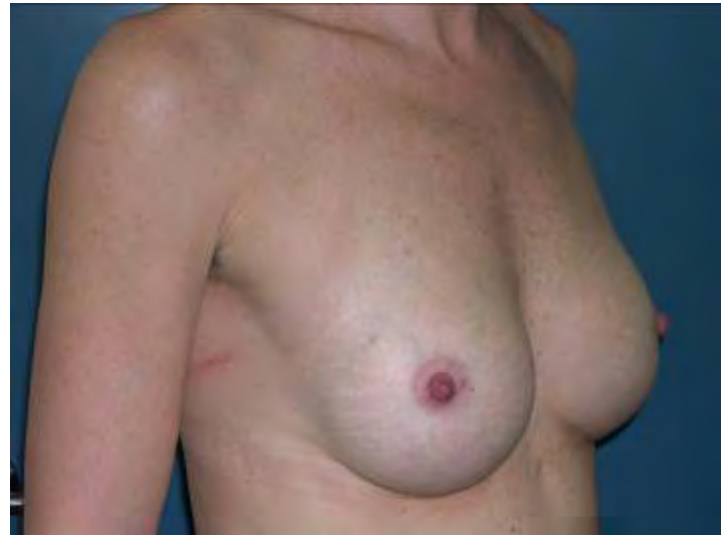
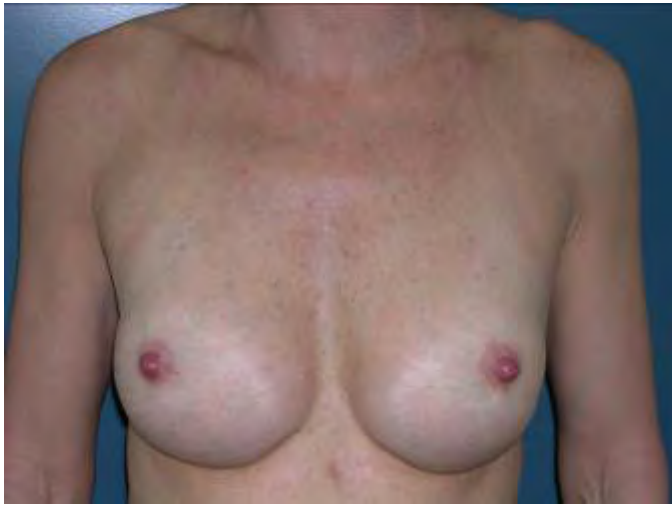
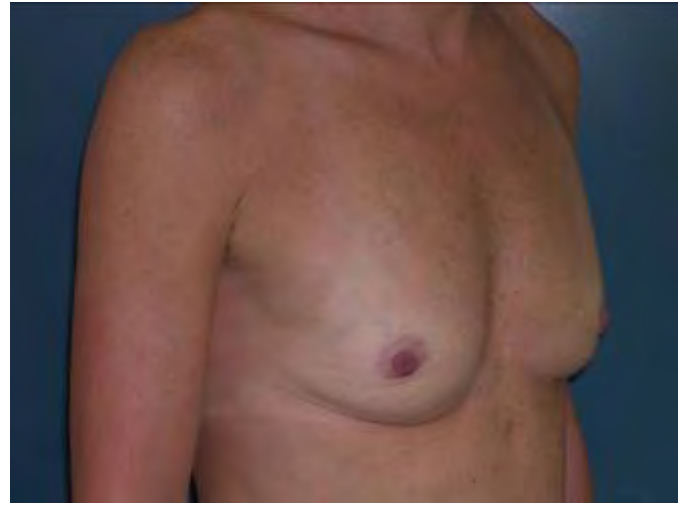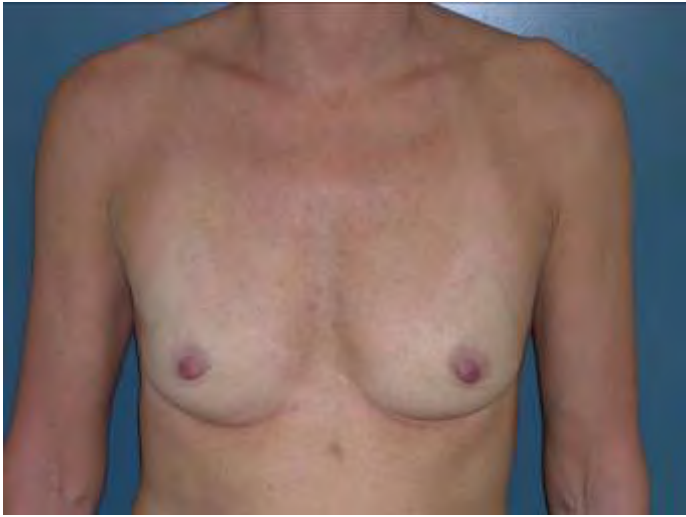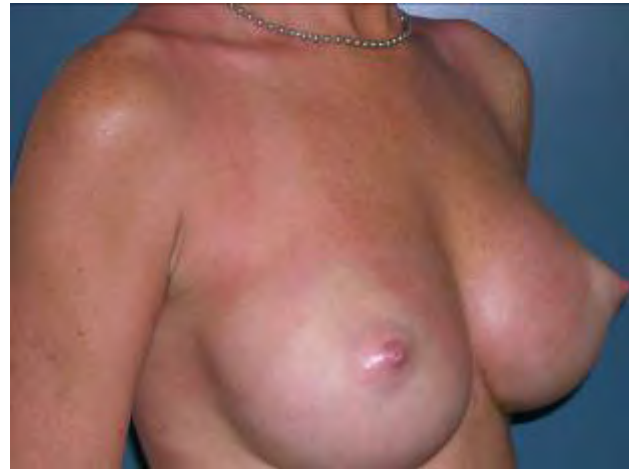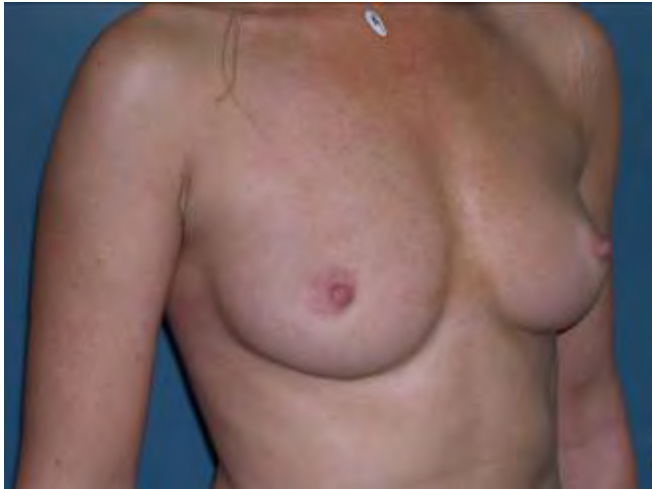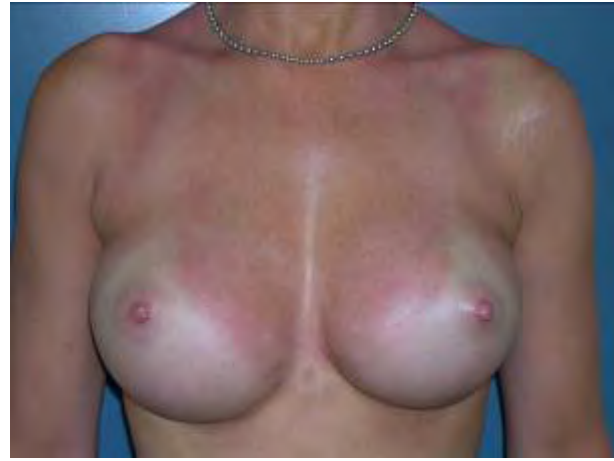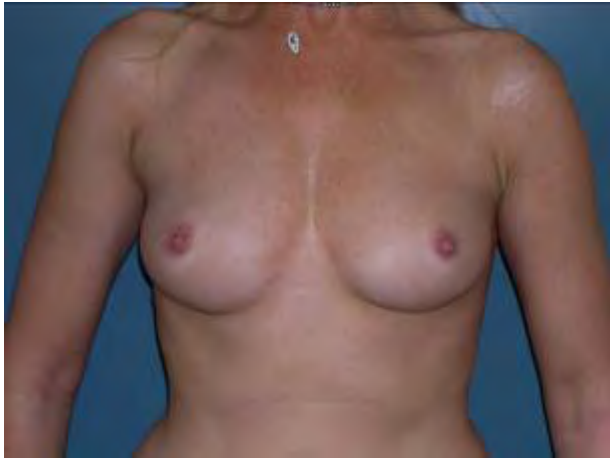The Gym Junkie

On a hiding to nothing!



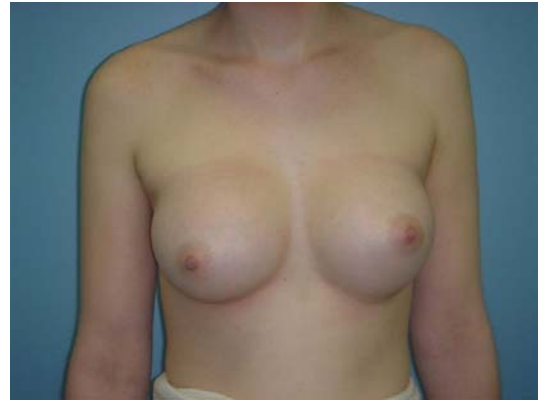
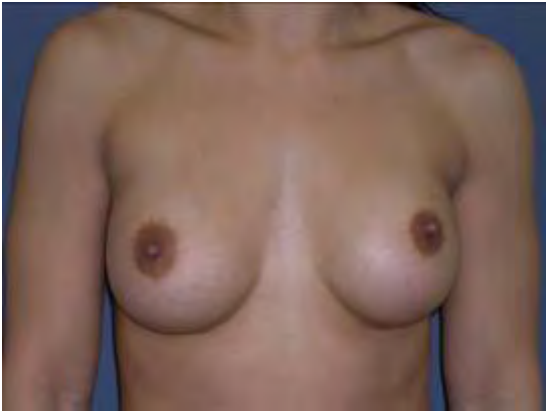
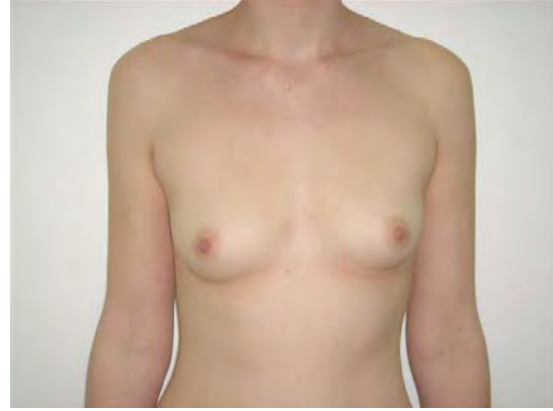
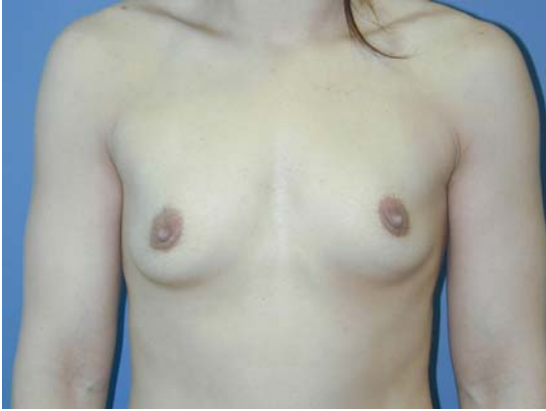


Chest wall asymmetries

An uninformed patient becomes
an unhappy patient



Take time with consultations

- What the patient wants
- What you need to add to get there
- Assess if this is possible
- Negotiate
- Compromise
- Warn of consequences of their decision; short term and long term