

The contents of this file are password protected. The copy is protected by copyright of the Author. Consent has been given for the express purpose of educating attendees of the March 2009 registrars' conference in Melbourne.

You **MAY NOT COPY OR DISTRIBUTE** the contents or images in any form.

You **MAY PRINT** the document for your own personal use as an educational resource.



---

# Pathology of Melanocytic Lesions

Andrew Ryan



# **Make sure you don't fall asleep (for too long)**

---

- There will be a little test at the end

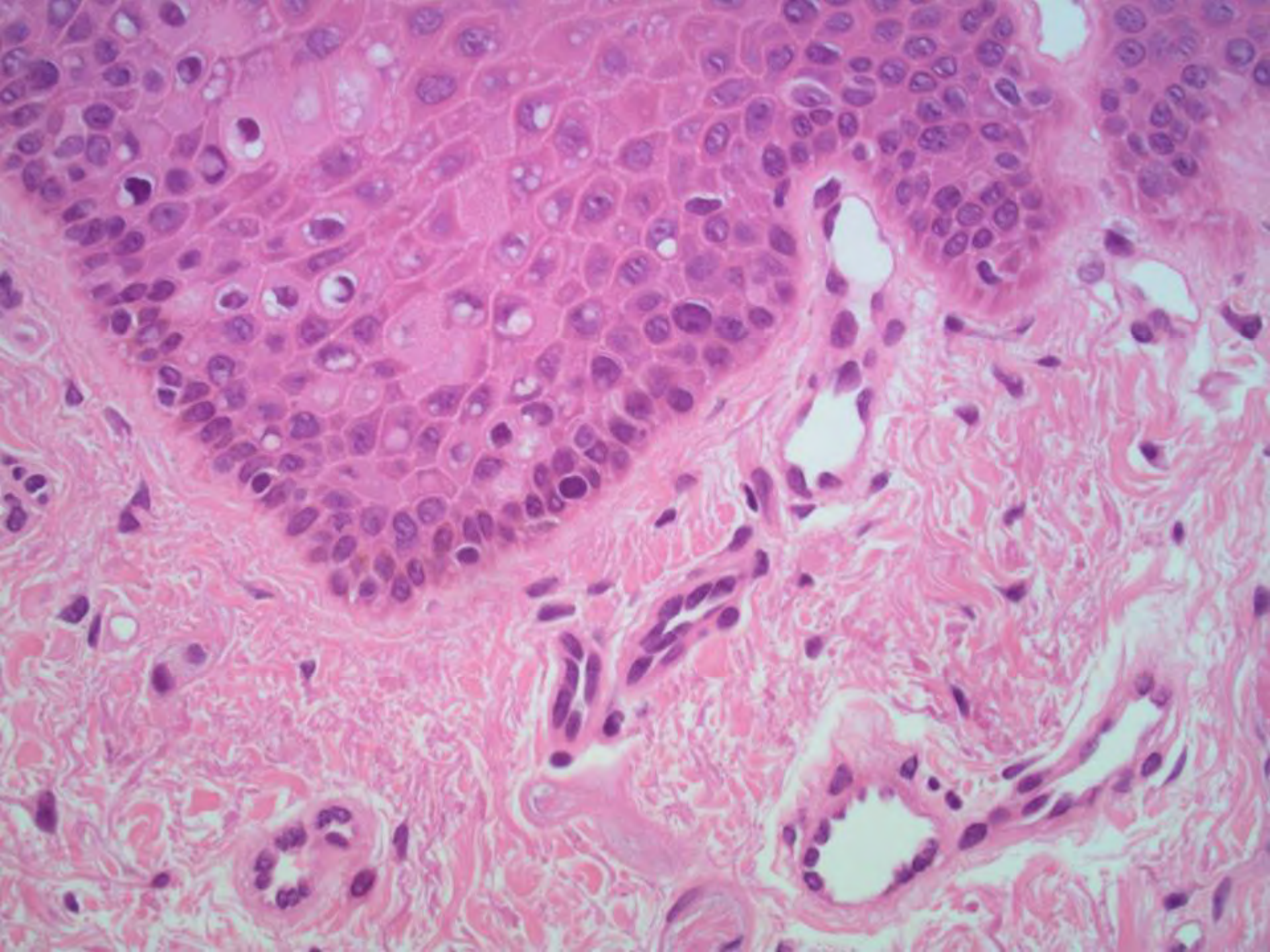


# Melanocyte

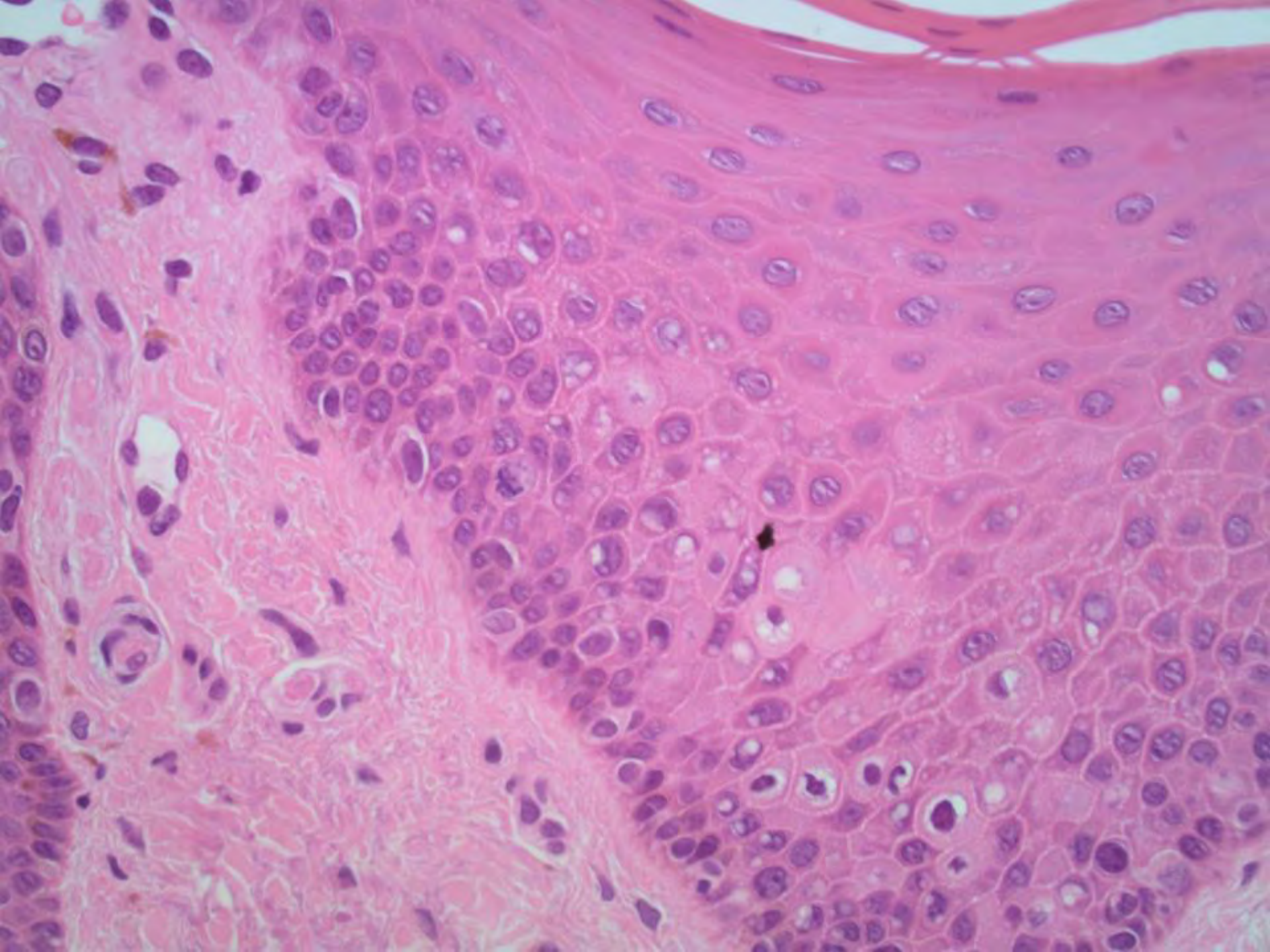
---

- Dendritic cell derived from neural crest
- Produces melanin pigment which is then stored in keratinocytes
- 1 melanocyte per 4-10 basal keratinocytes











# Classification

---

- Benign
  - lentiginos
  - naevi
  - dermal melanocytoses
  - dysplastic naevi
  
- Melanoma



---

# Moles



# Mole (European)

---



[www.naturfoto.cz](http://www.naturfoto.cz)

© Jiří Bohdal



MELBOURNE PATHOLOGY

*"We take it personally"*





# Praia Mole





# Praia Mole, Brazil



# Local variants







# Mole



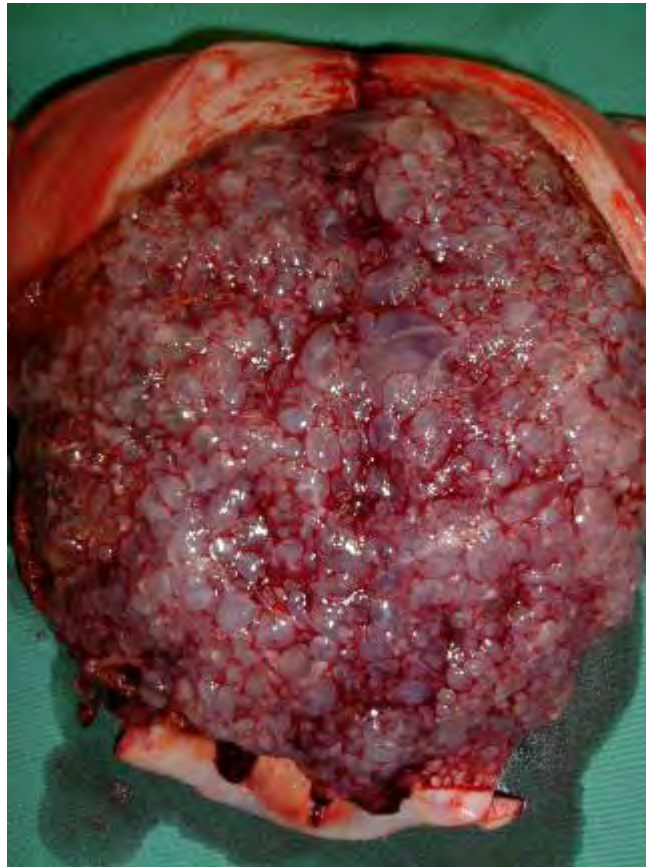

# The Mole



# Hydatidiform mole

---



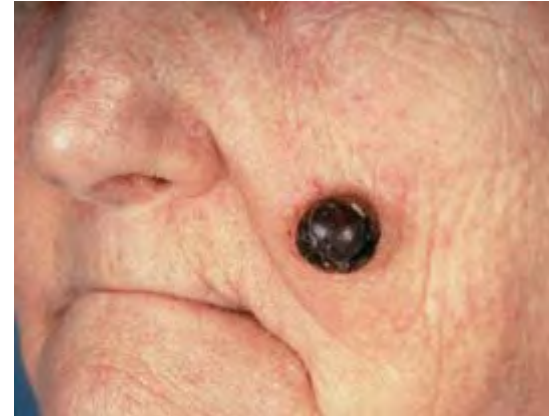

MELBOURNE PATHOLOGY

*"We take it personally"*



# Moles

---







# Benign

---

- Lesions with basal melanocyte proliferation
- Melanocytic naevi
- Dermal melanocytoses
- Dysplastic naevi

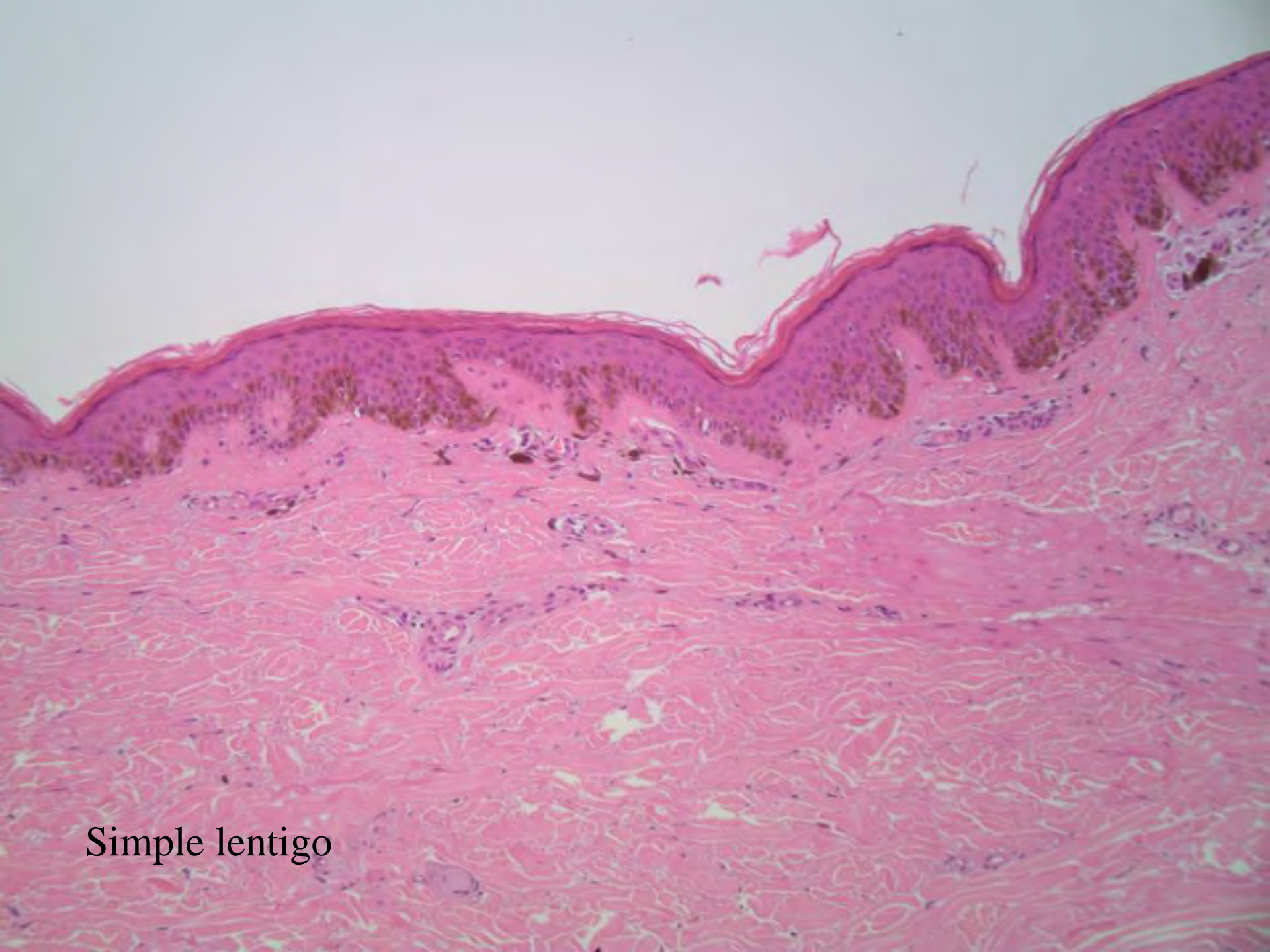


# Lesions with basal melanocyte proliferation

---

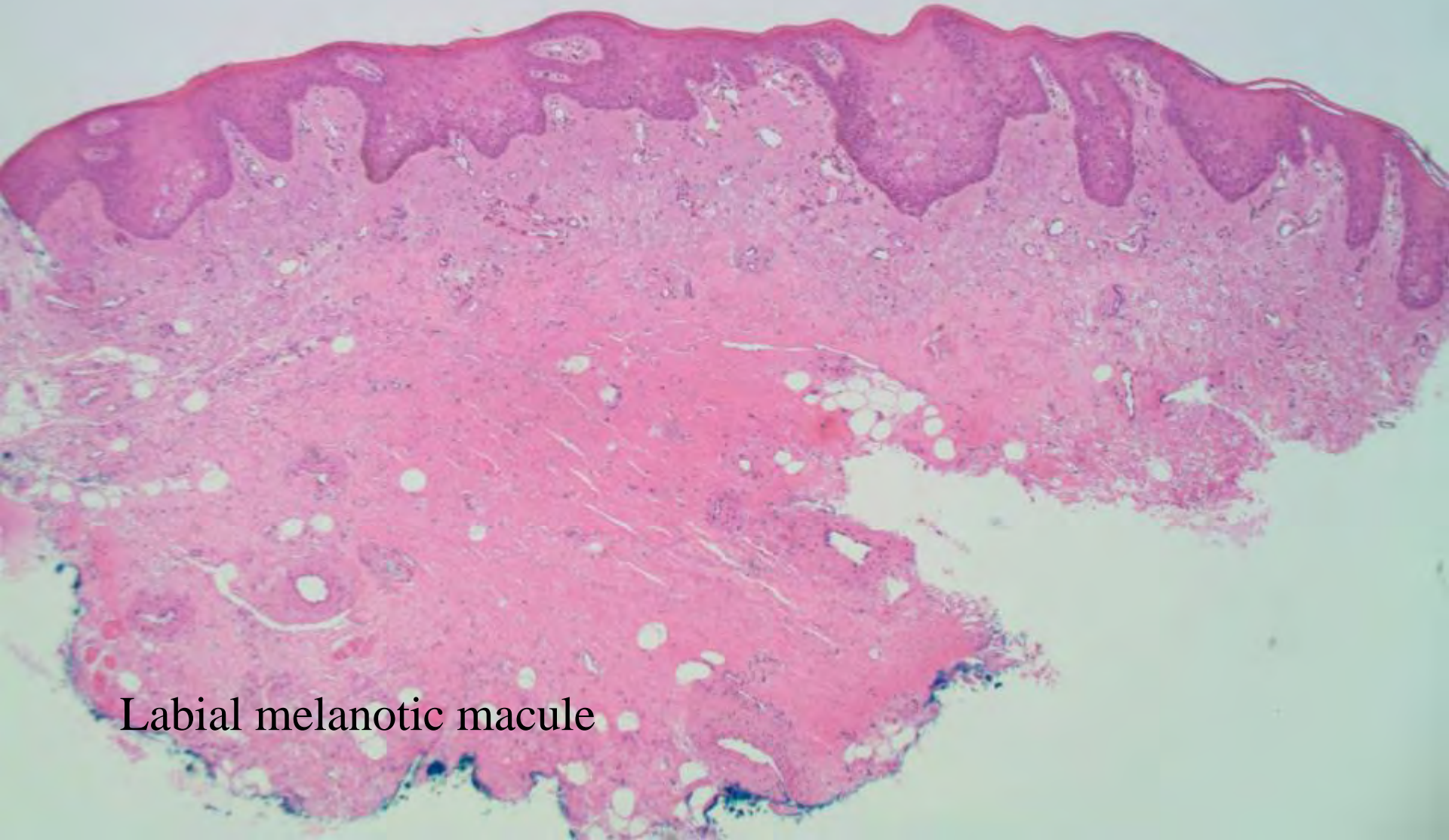- Simple lentigo
- Multiple lentiginos
- Melanotic macules (labial and genital)
- Solar lentigo
- Lentiginous naevus
- Naevus spilus
- PUVA and scar lentigo





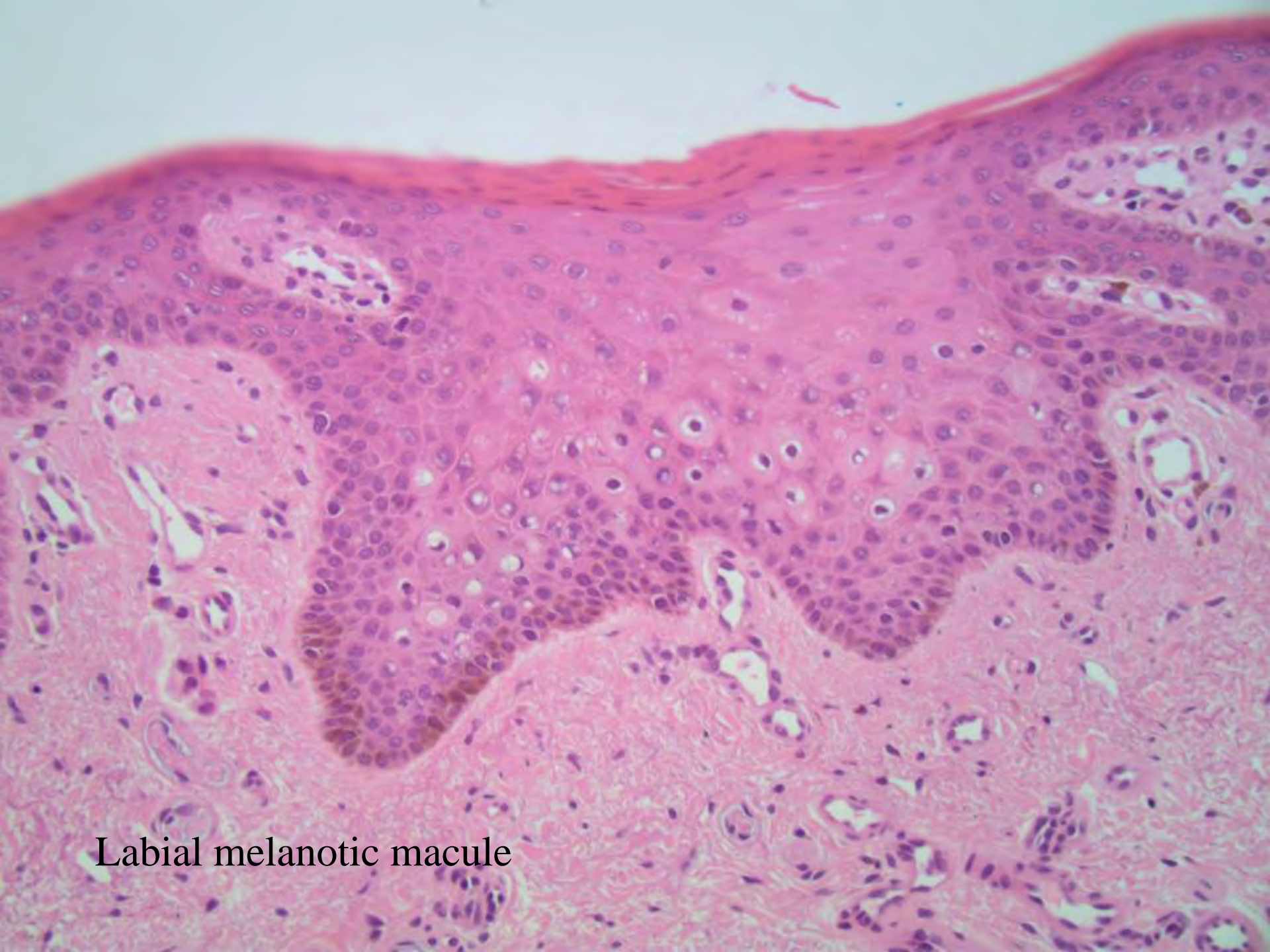
Simple lentigo





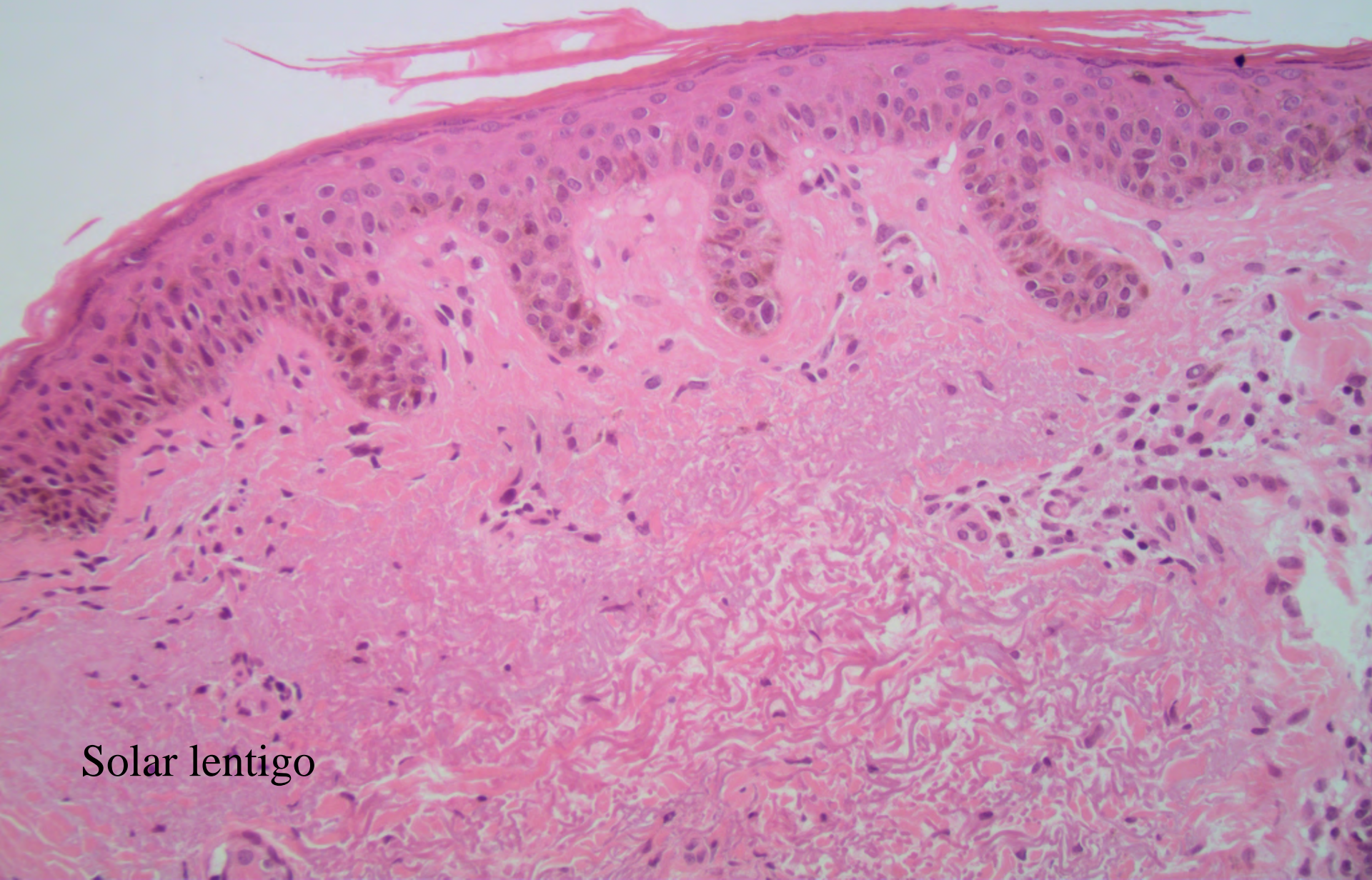
Labial melanotic macule





Labial melanotic macule





Solar lentigo

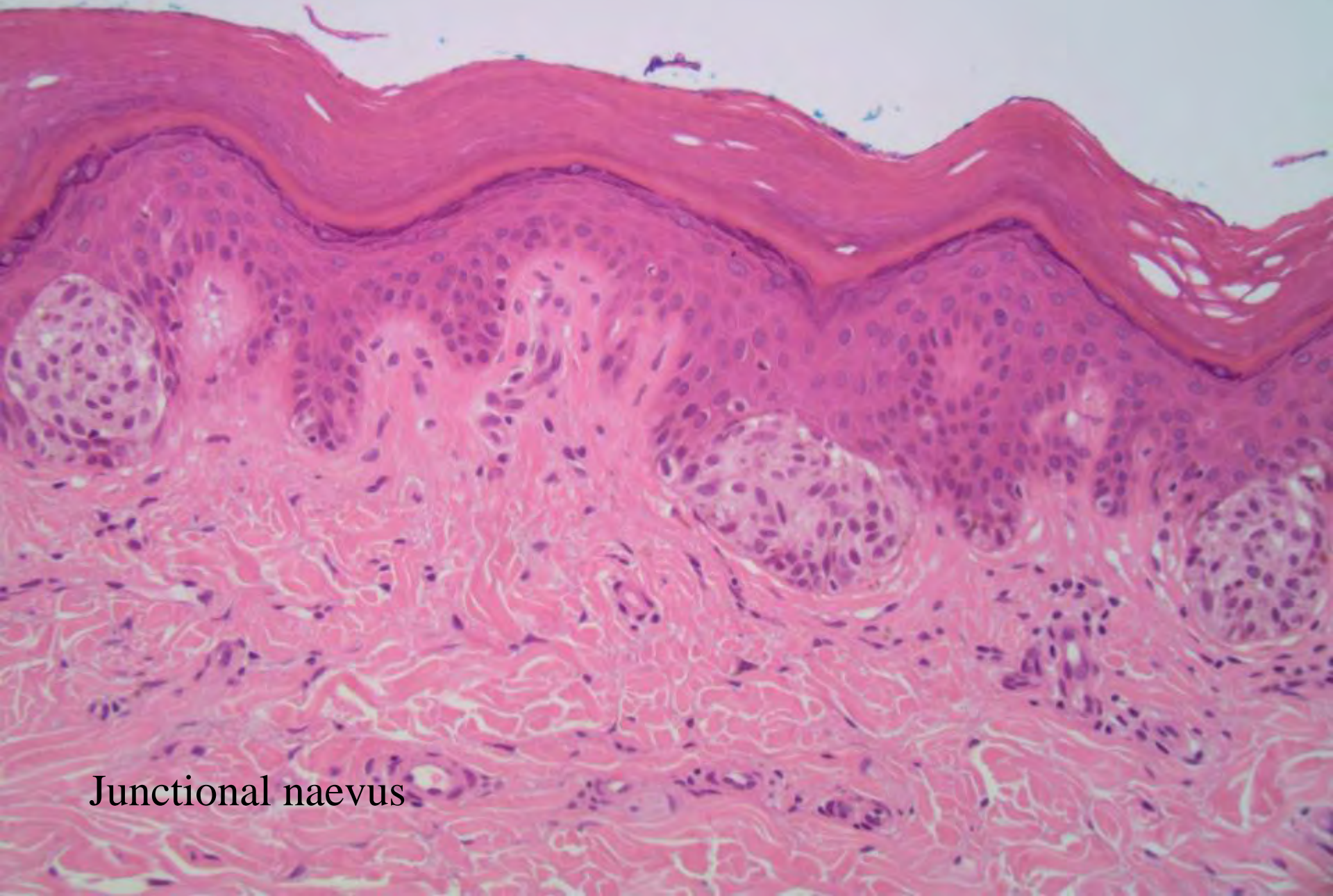


# Melanocytic naevi

---

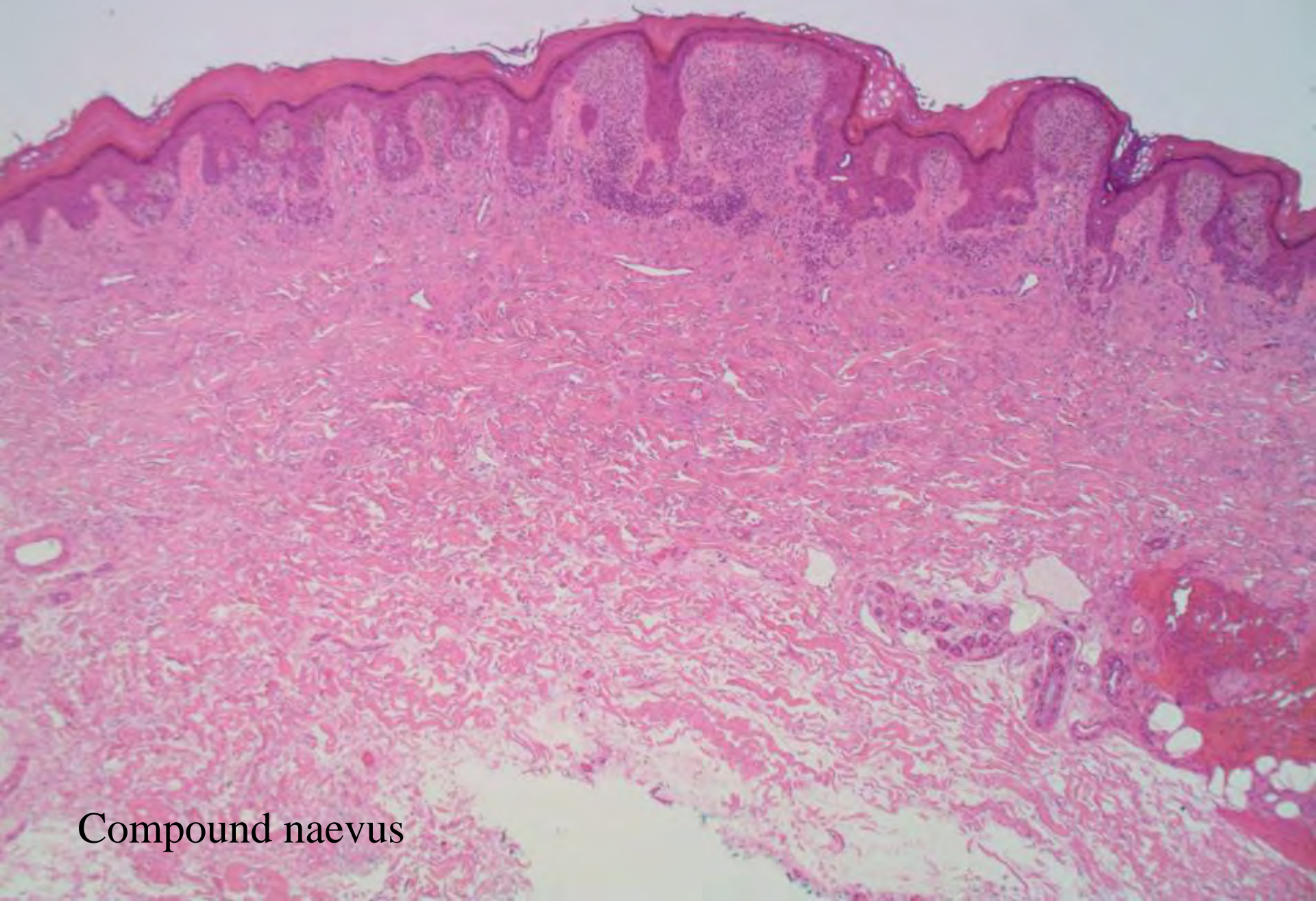
- Junctional naevus
- Compound naevus
- Intradermal naevus
- Congenital naevus
- Spitz naevus
- Others





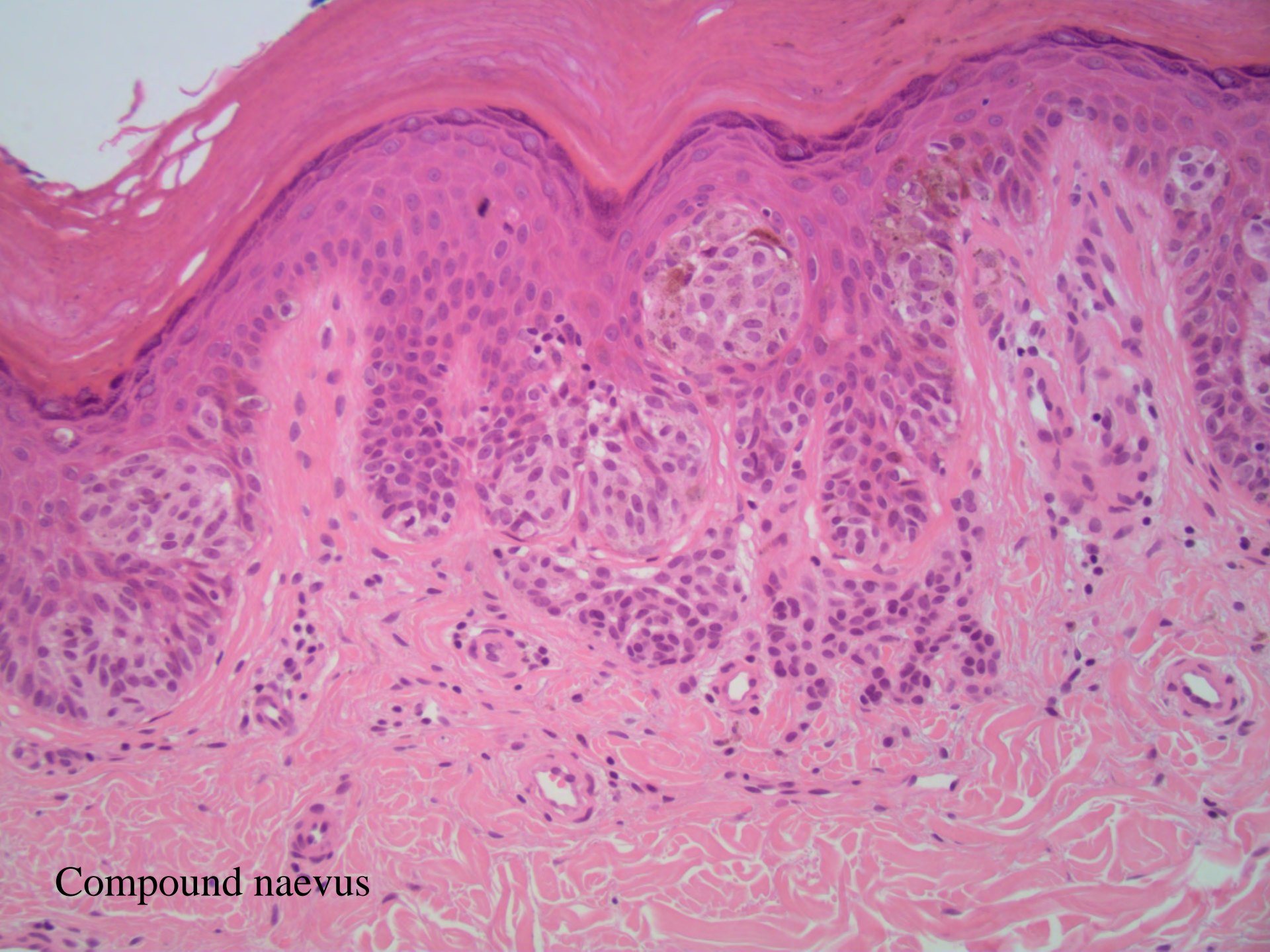
Junctional naevus





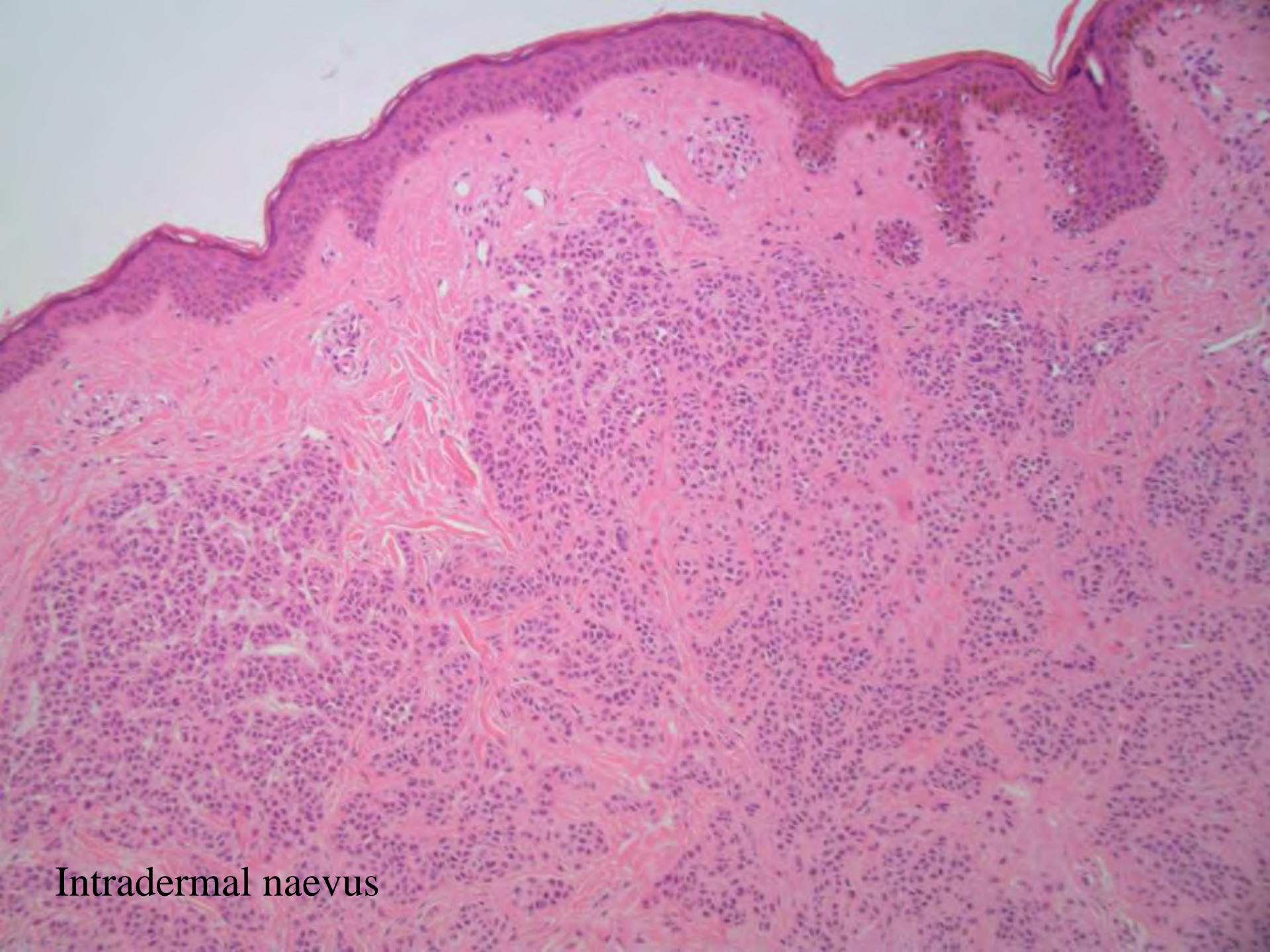
Compound naevus





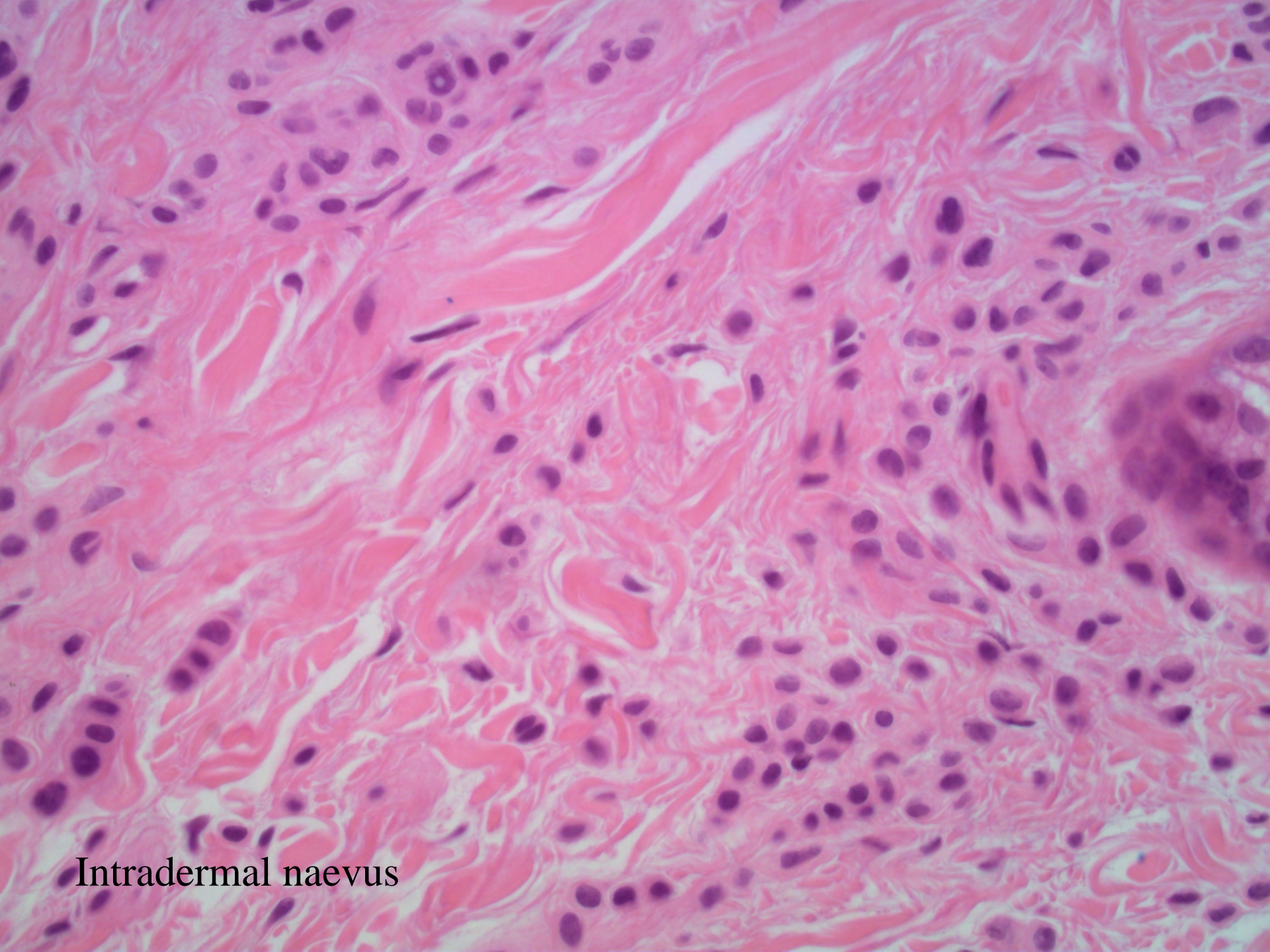
Compound naevus





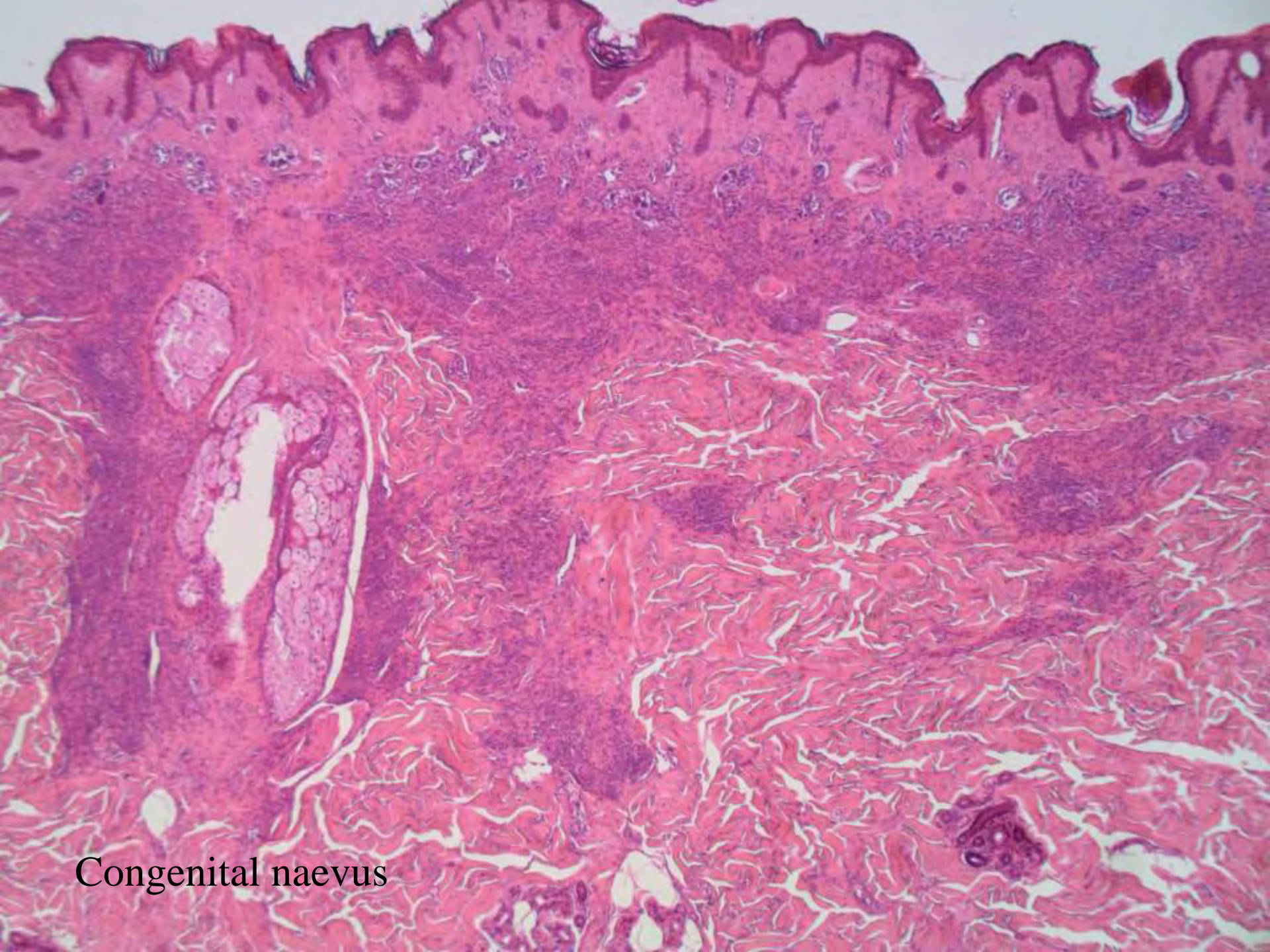
Intradermal naevus





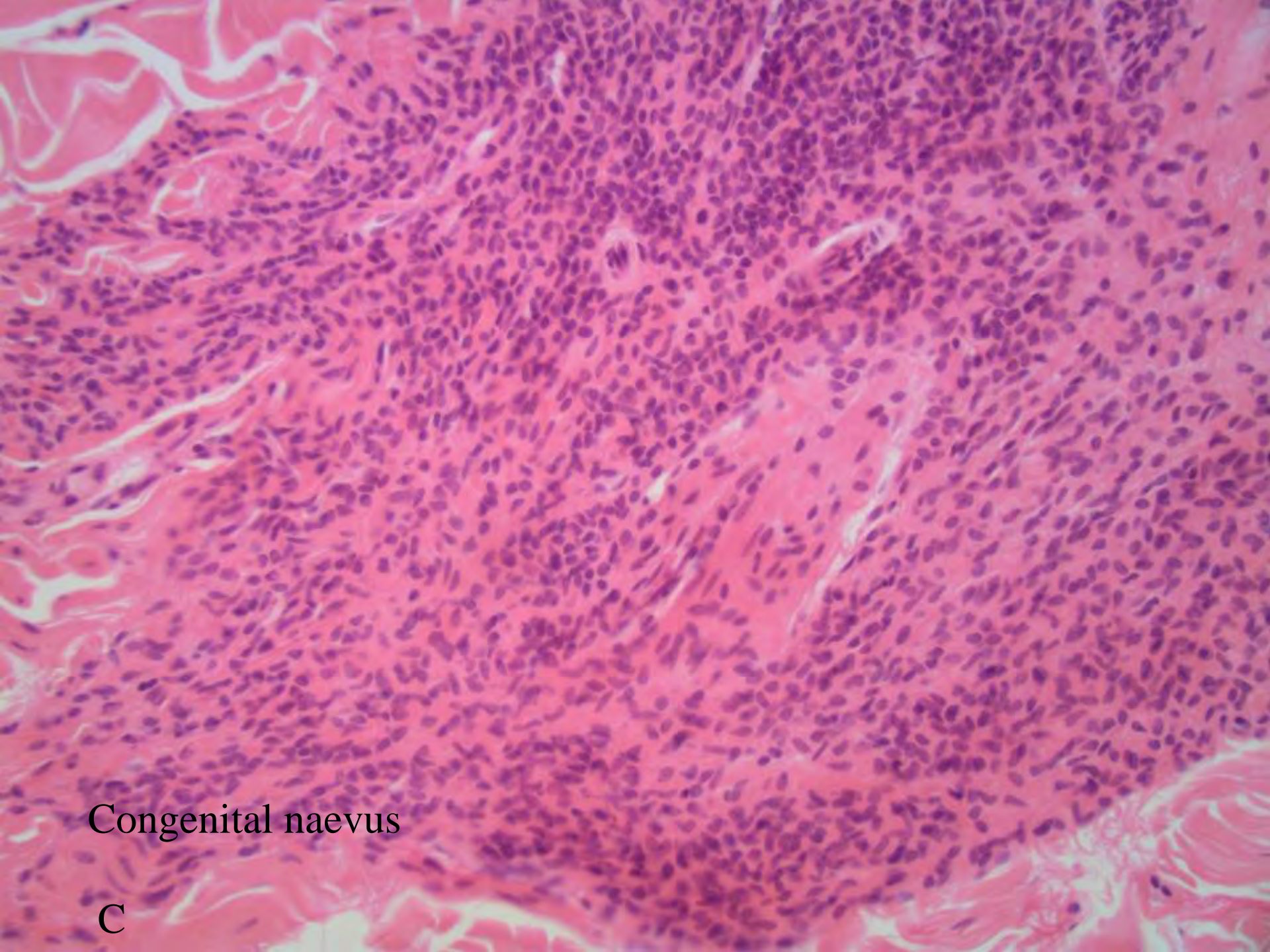
Intradermal naevus





Congenital naevus

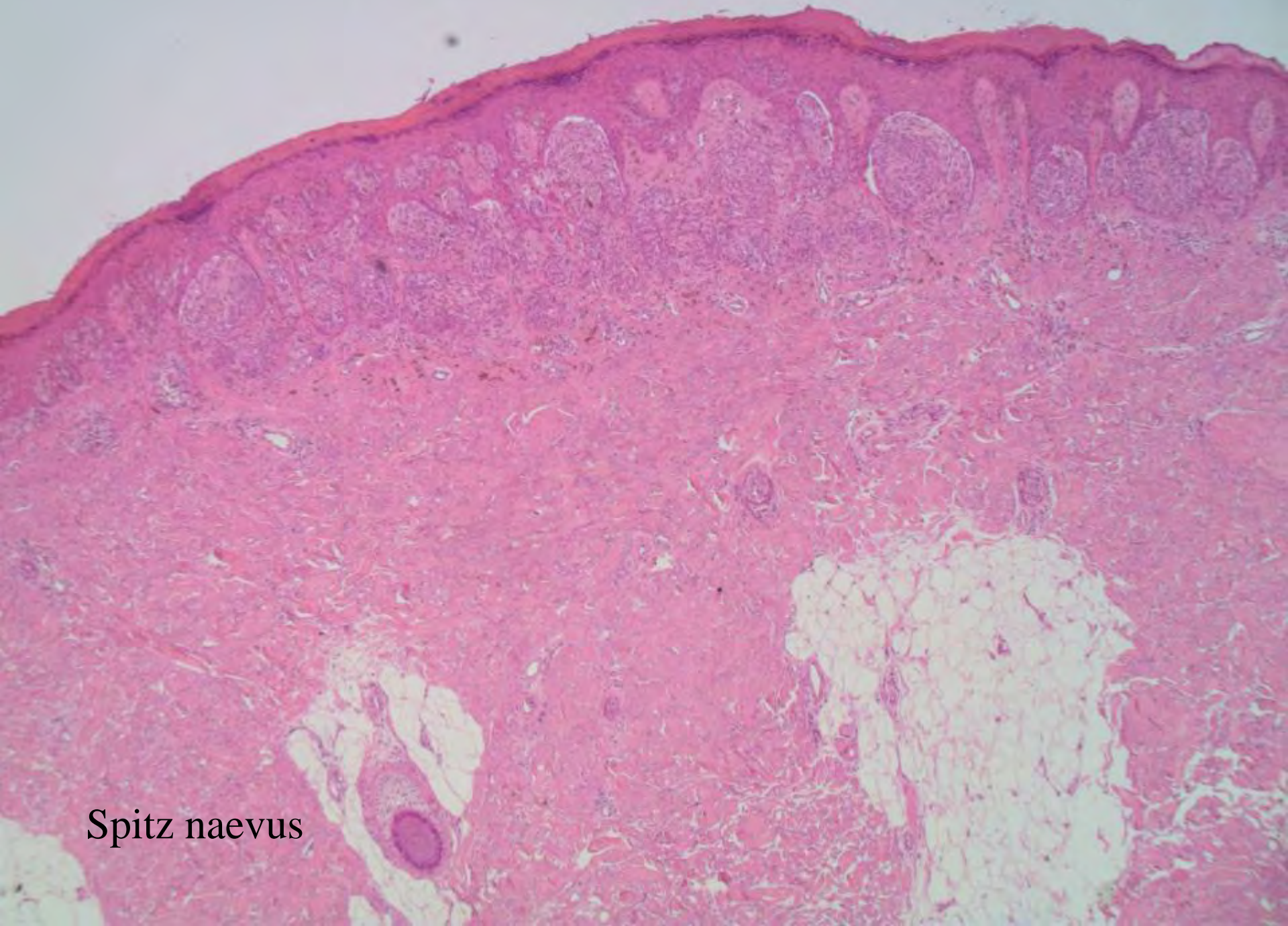




Congenital naevus

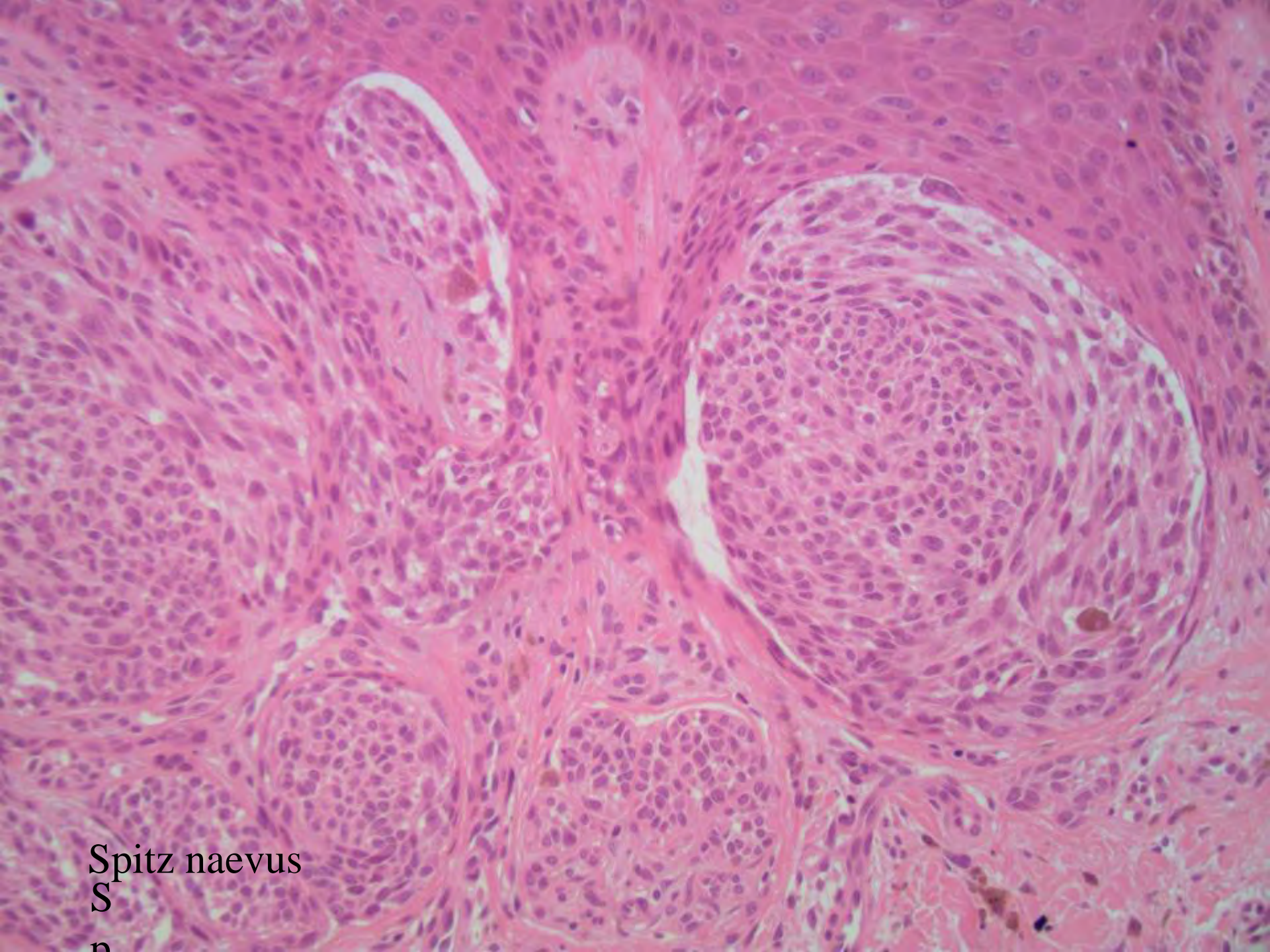C





Spitz naevus





Spitz naevus

S

n

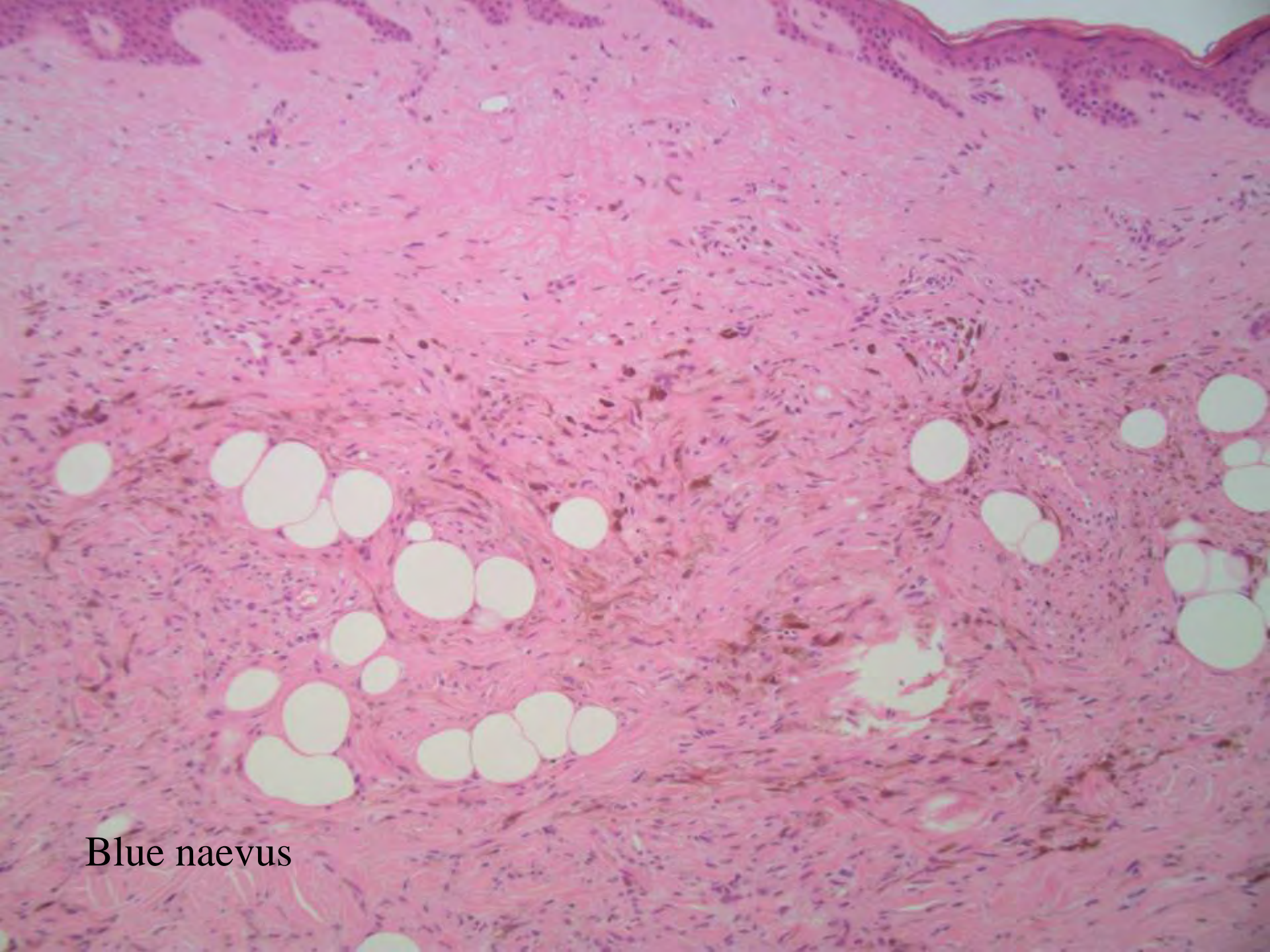


# Dermal melanocytoses

---

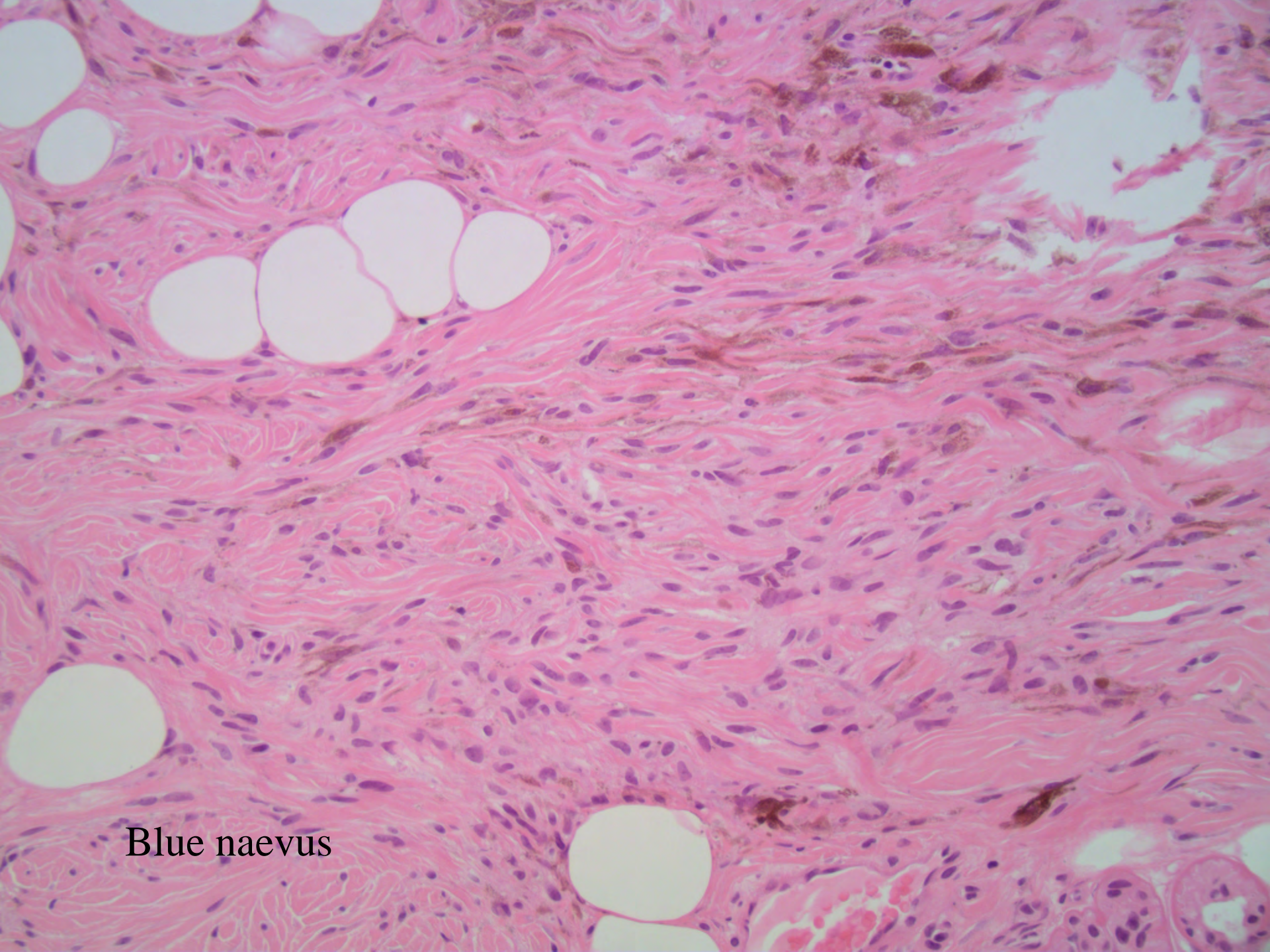
- Mongolian spot
- Naevus of Ota and Ito
- Blue naevus and variants





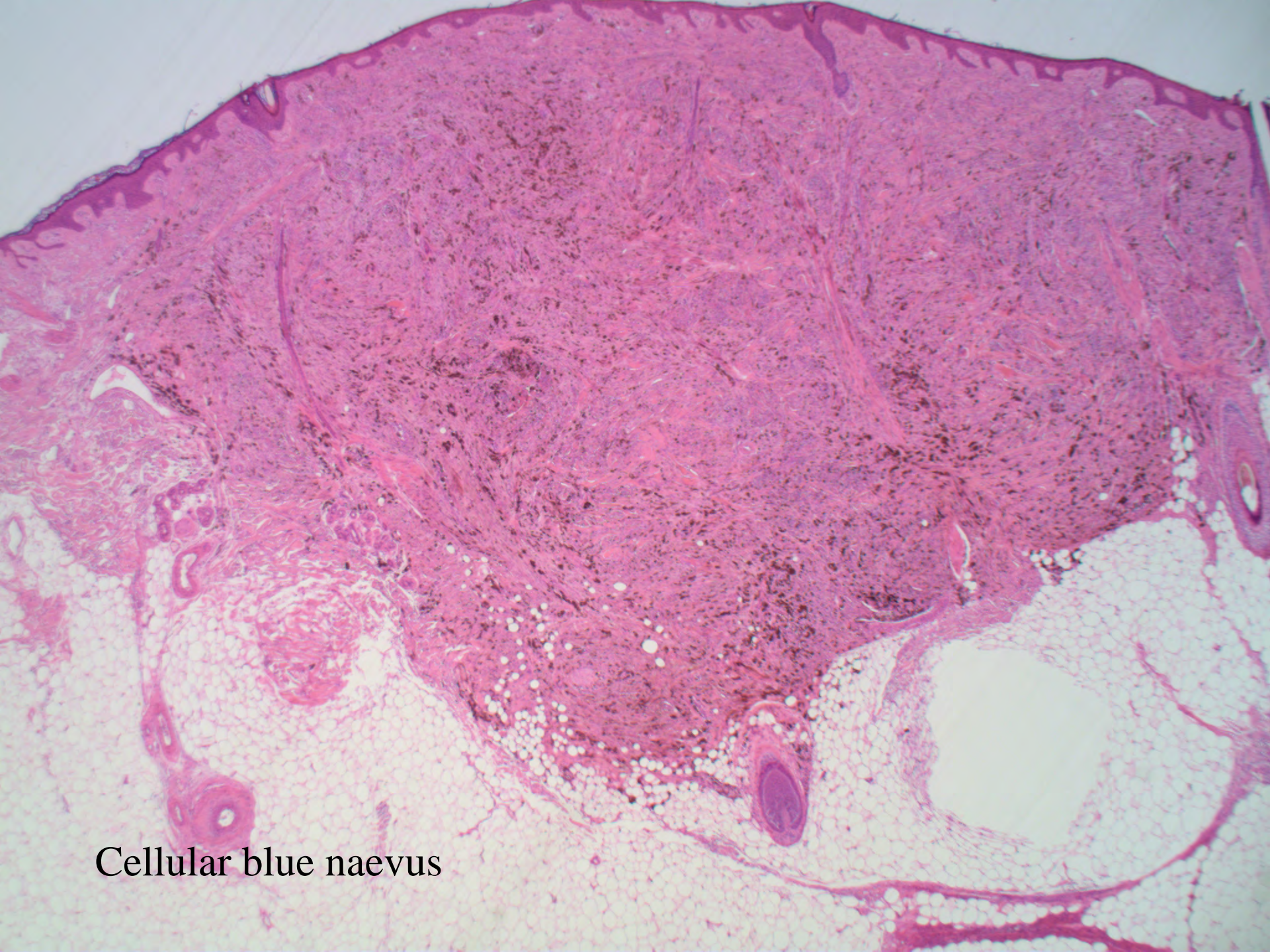Blue naevus





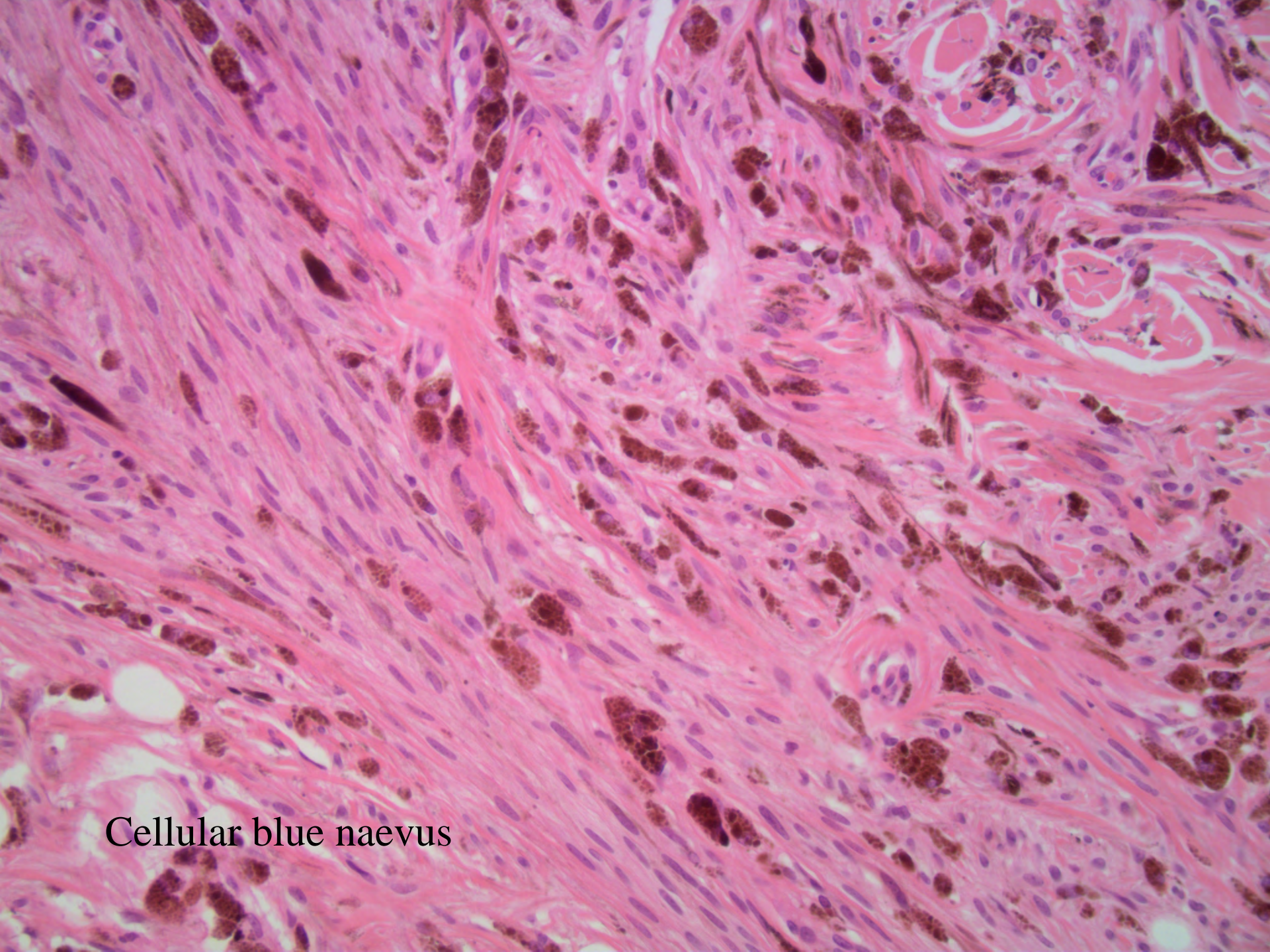
Blue naevus





Cellular blue naevus





Cellular blue naevus

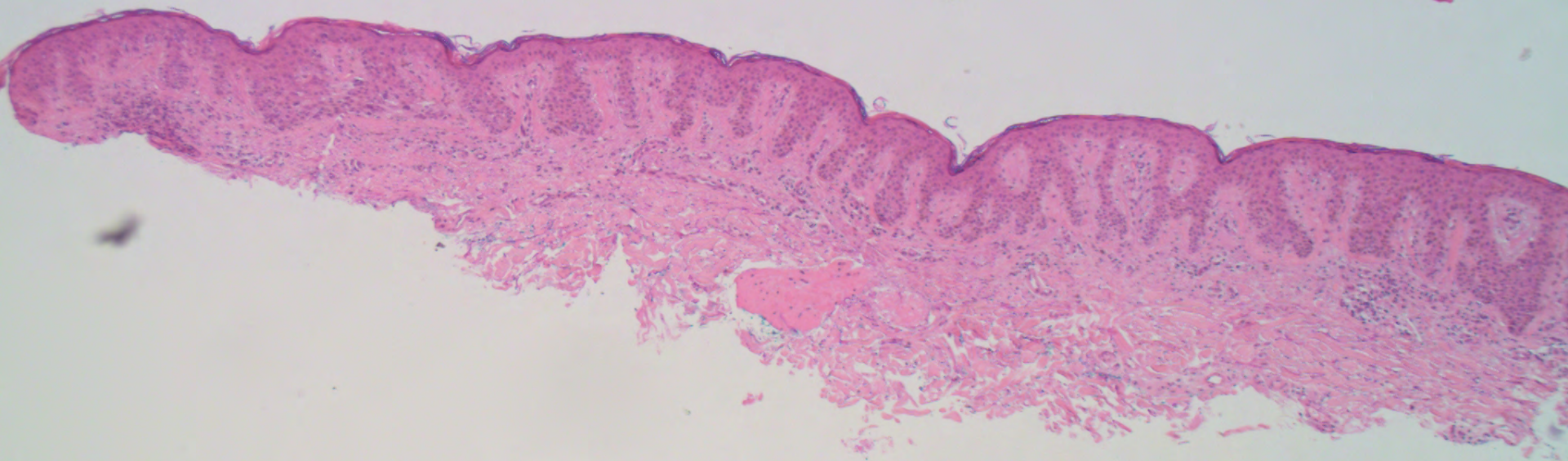


# Dysplastic naevi

---

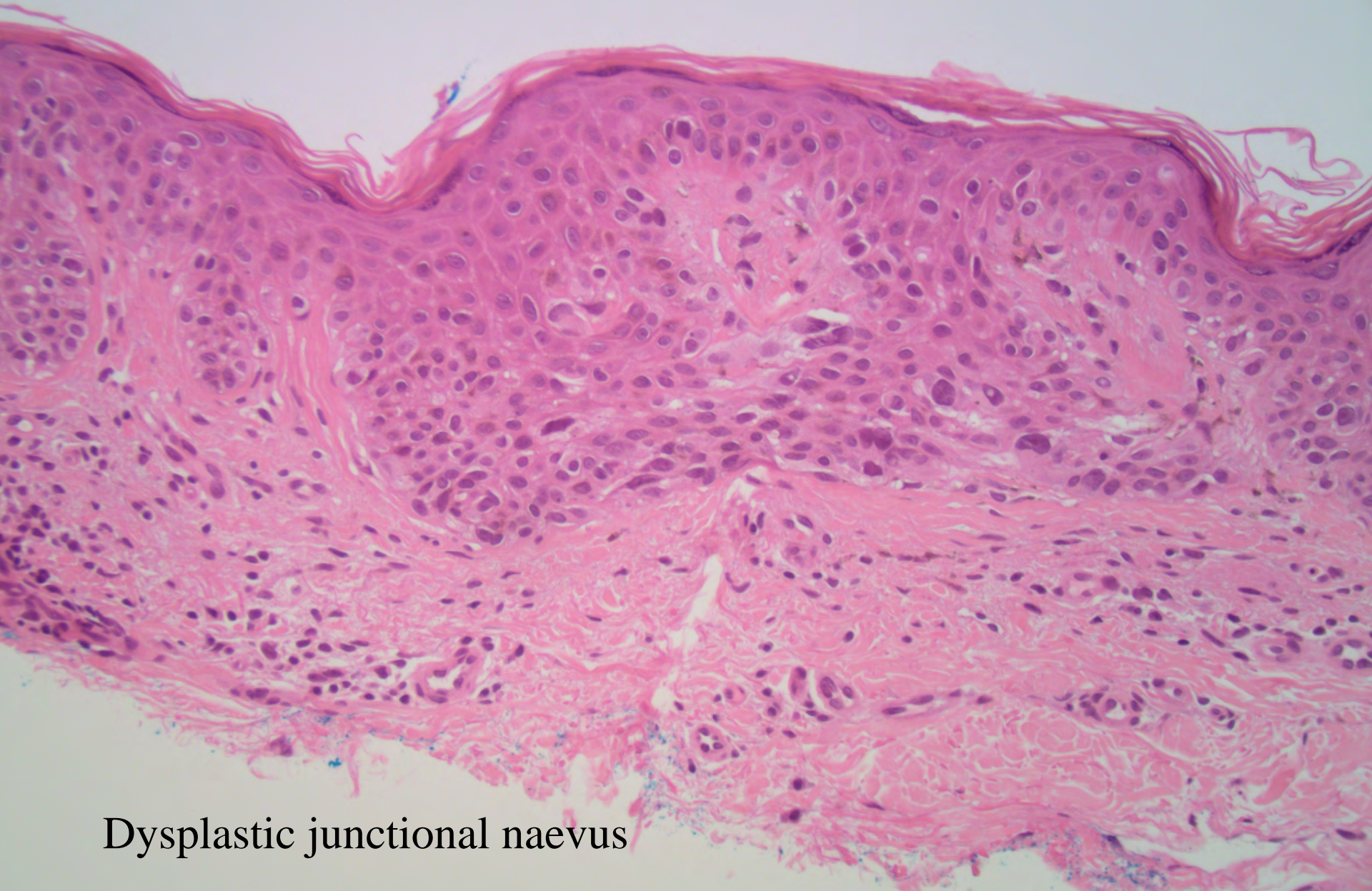
- Junctional or compound
- “Mild, moderate, severe”
- Criteria:
  - lentiginous hyperplasia and junctional nest disarray
  - random cytological atypia
  - stromal response





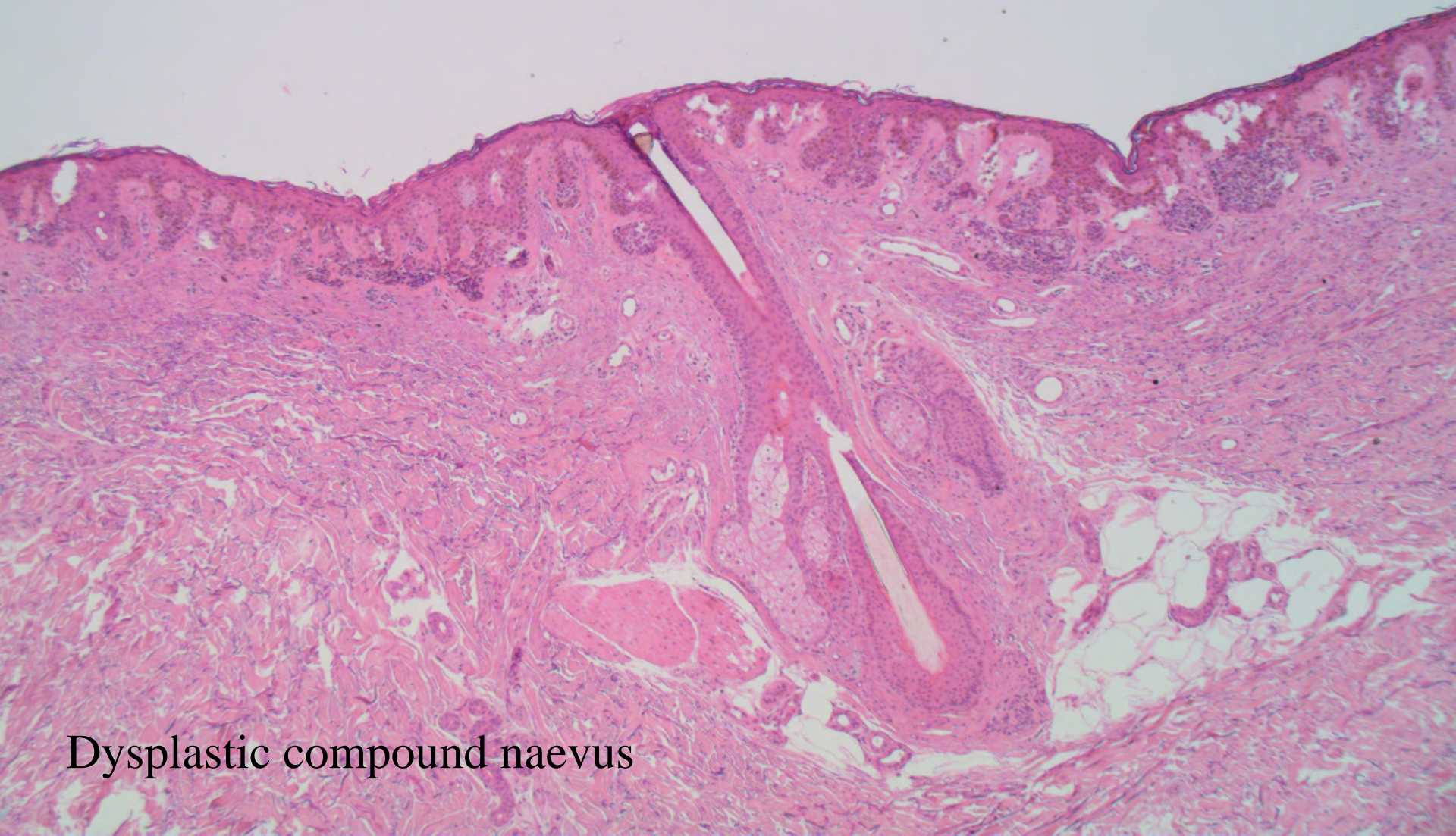
Dysplastic junctional naevus





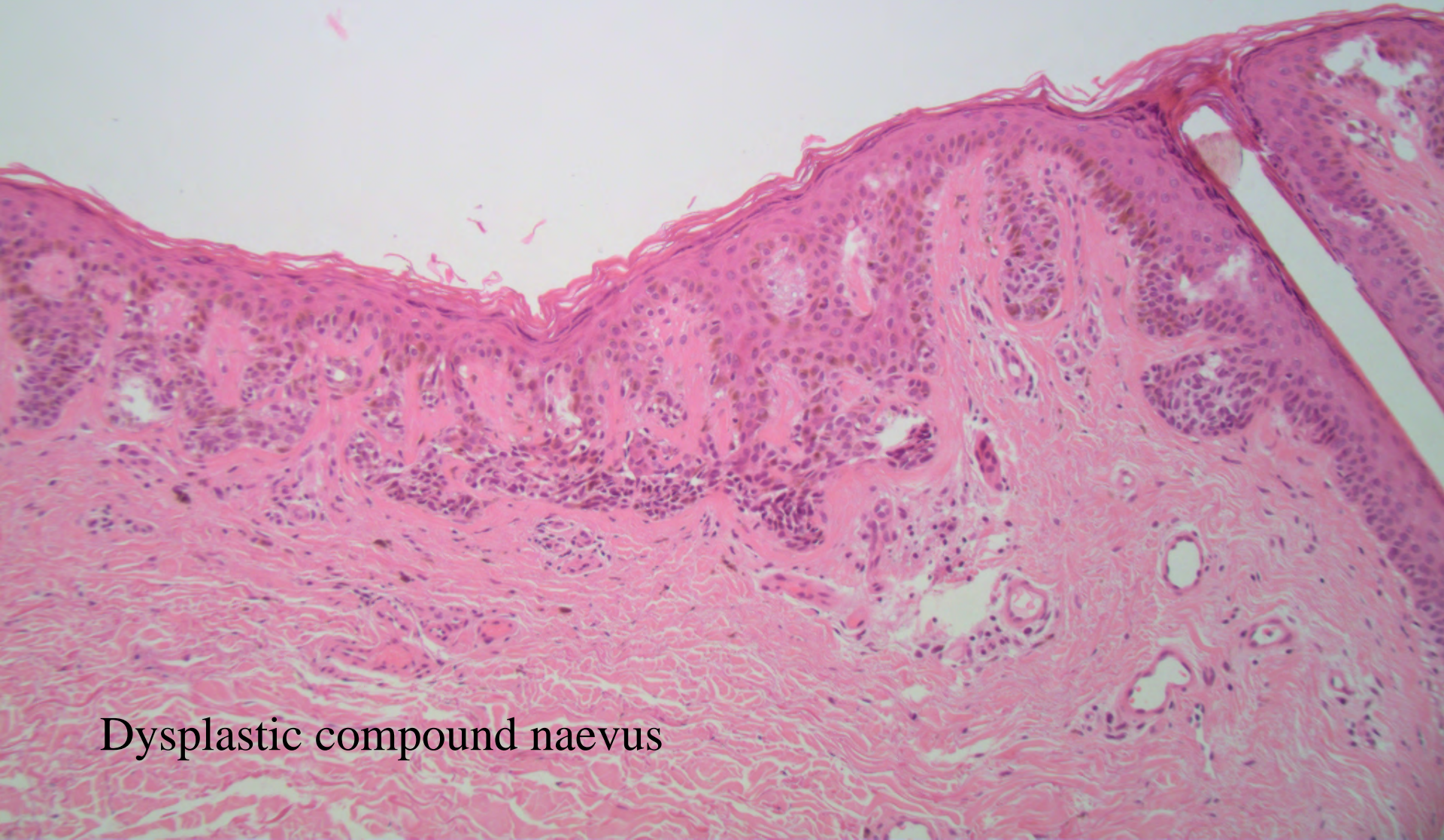
Dysplastic junctional naevus





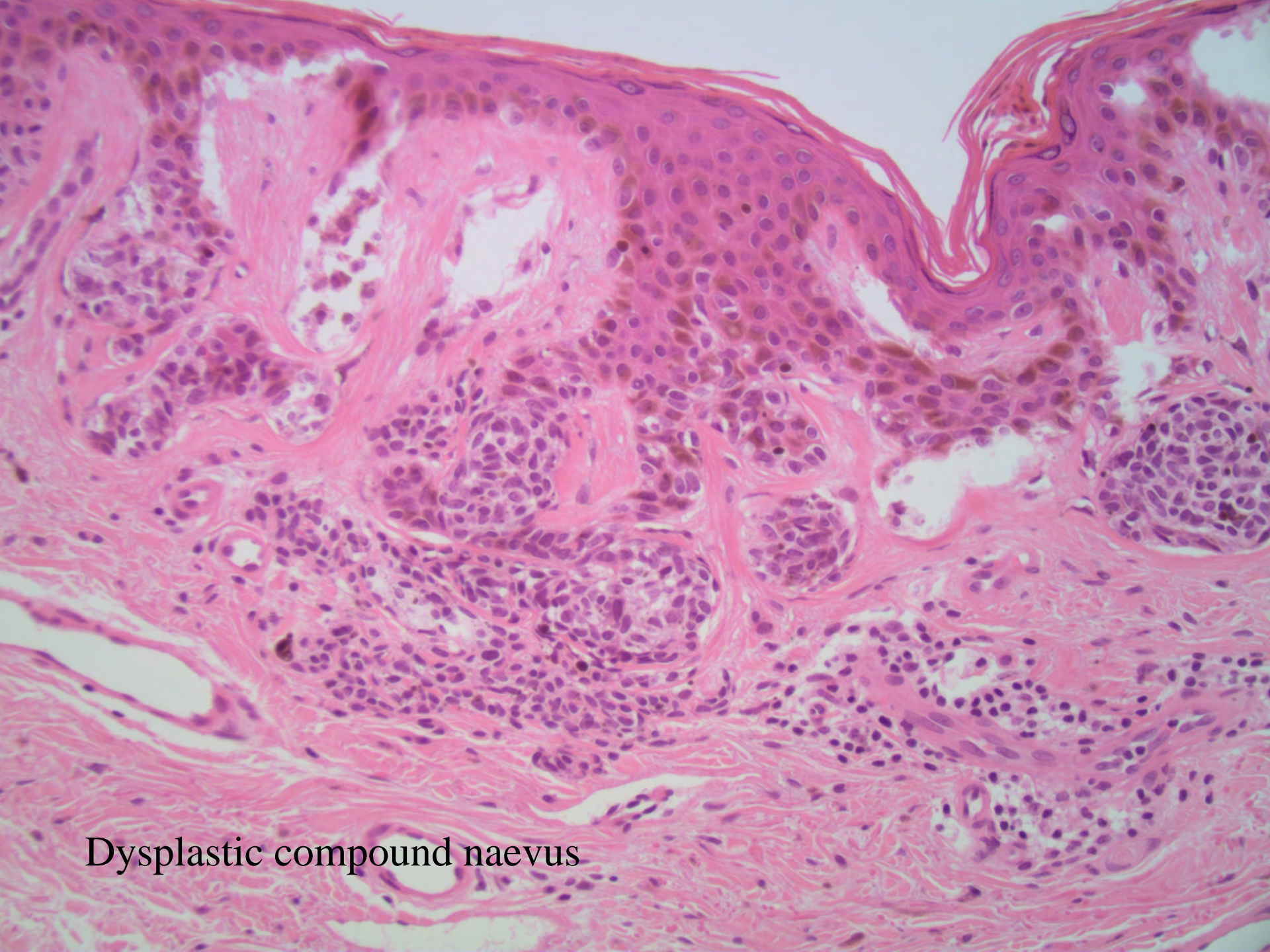
Dysplastic compound naevus





Dysplastic compound naevus





Dysplastic compound naevus

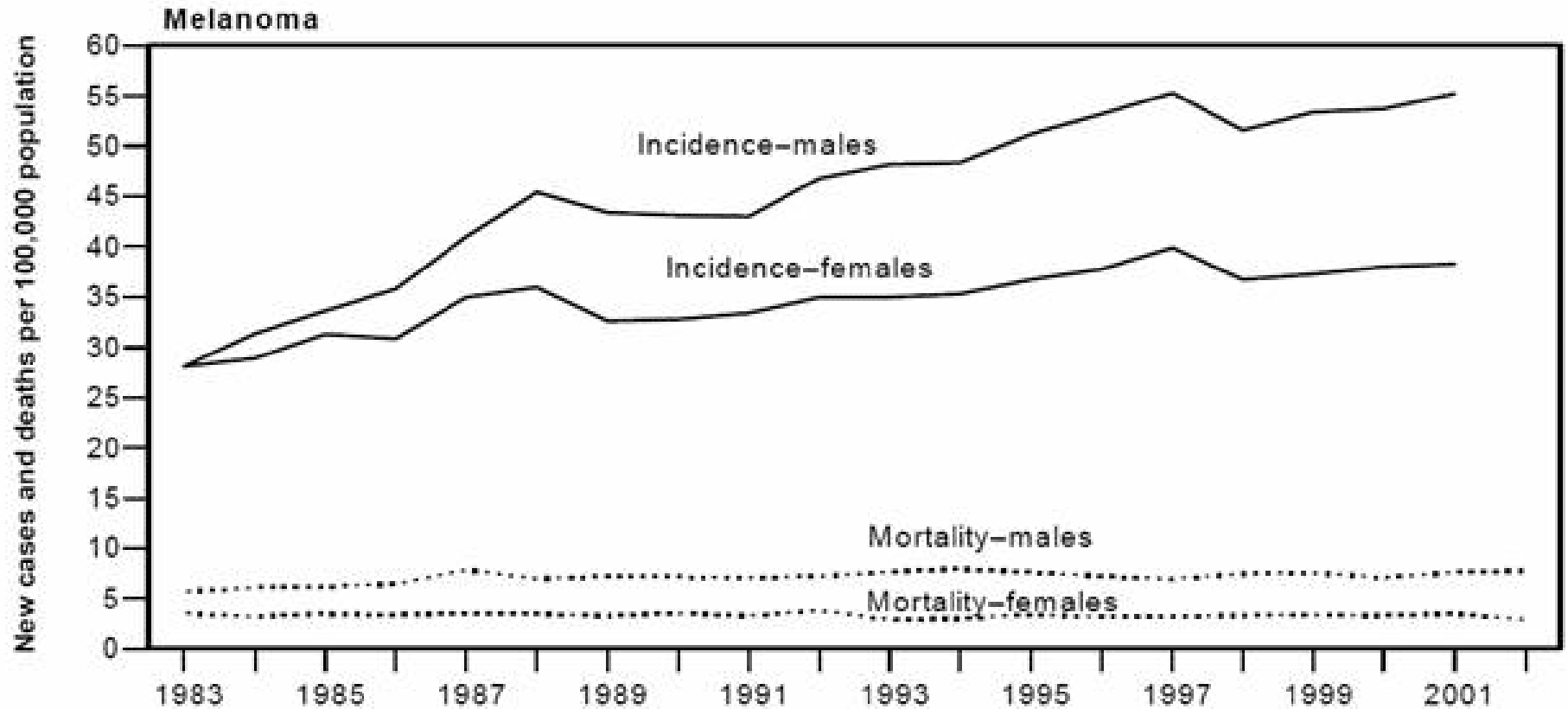


---

# Malignant melanoma



# Malignant melanoma Incidence





# Malignant melanoma

## Risk factors

---

- Skin and hair colour, numerous freckles
- Tendency to burn; blistering sunburns
- PUVA therapy
- Tanning salons
- Naevi (numerous, large, atypical)
- Others (immunosuppression, genetic factors, inherited disorders)





# Malignant melanoma

## Risk factors

---

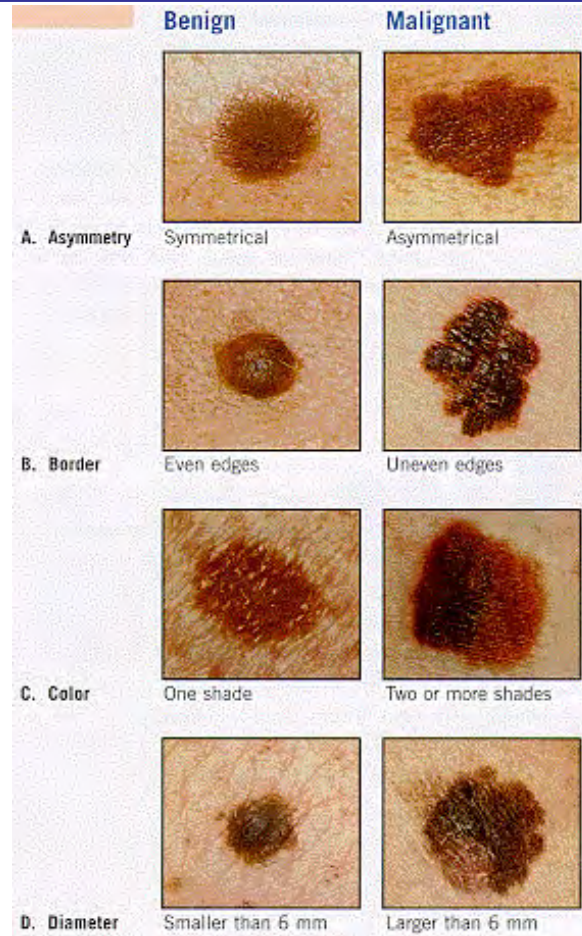


MELBOURNE PATHOLOGY

*"We take it personally"*

# Malignant melanoma

## Clinical features





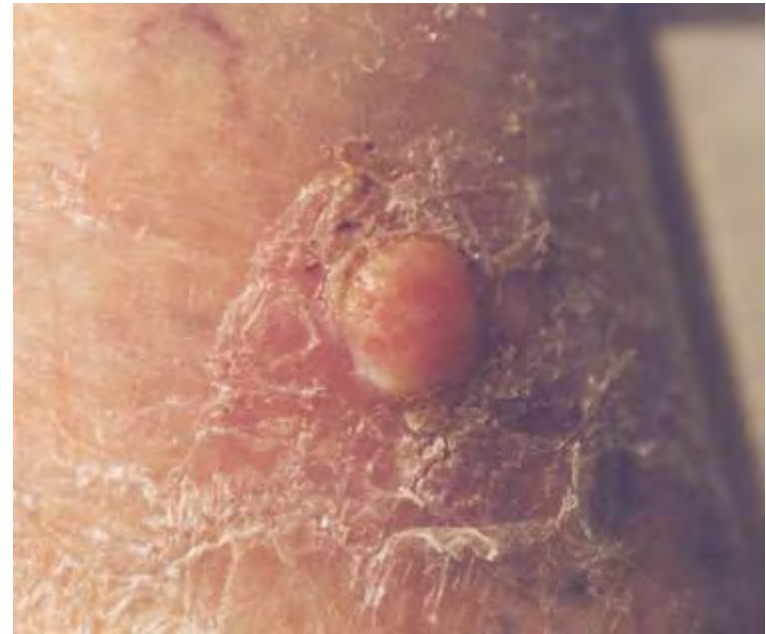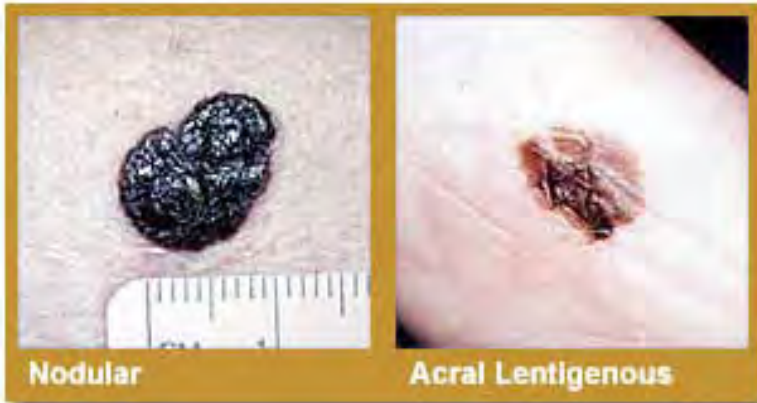
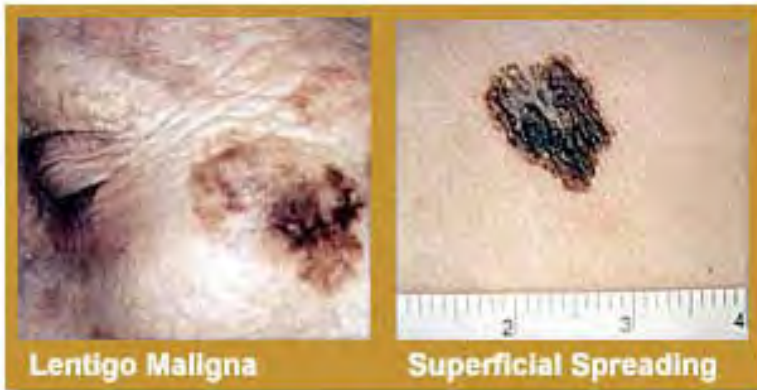


# Malignant melanoma Classification

---

- Lentigo maligna melanoma
- Superficial spreading melanoma
- Acral lentiginous melanoma
- Nodular melanoma
- Desmoplastic melanoma
- Special/rare variants

# Malignant melanoma







# Malignant melanoma

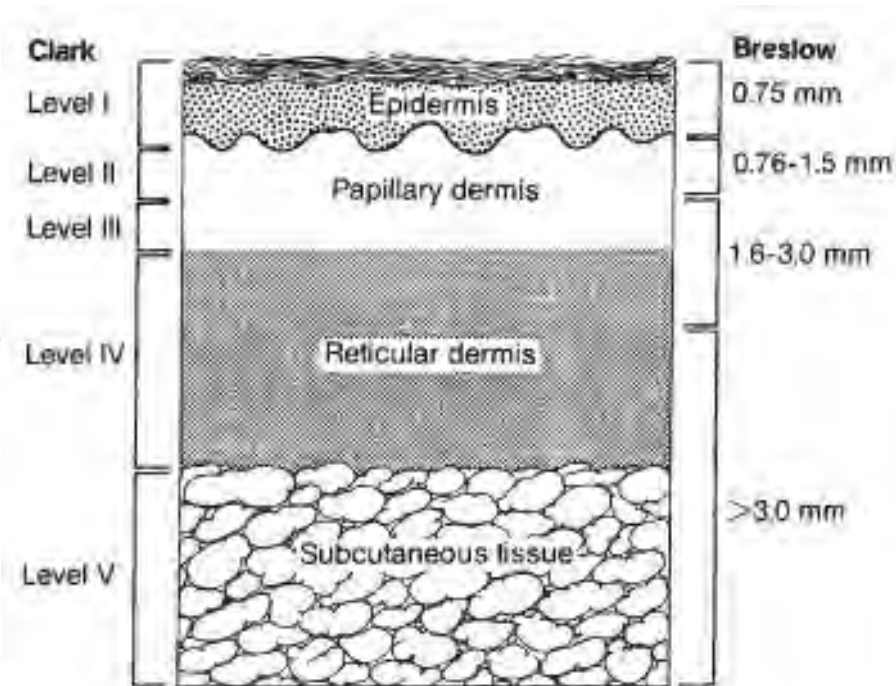
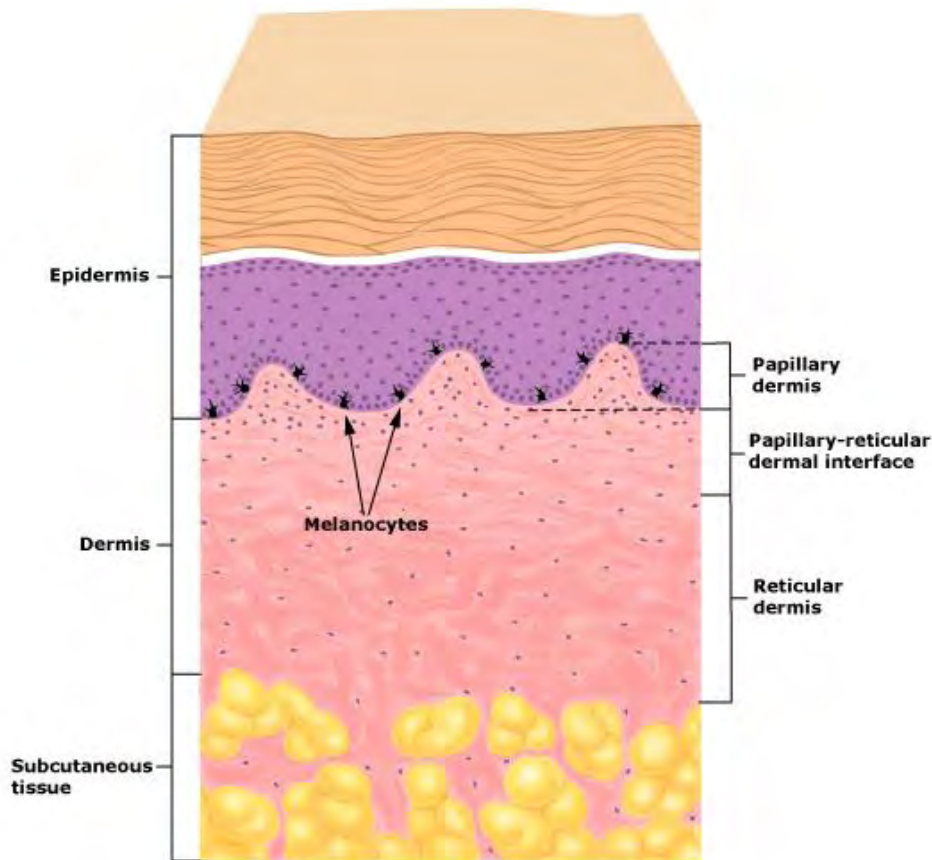
## Clark levels

---

- Level 1 – intraepidermal (melanoma in situ)
- Level 2 – invasion into papillary dermis
- Level 3 – expansion of papillary dermis and extension to papillary-reticular dermal interface
- Level 4 – invasion into reticular dermis
- Level 5 – invasion into subcutis

# Malignant melanoma

## Clark level and Breslow thickness





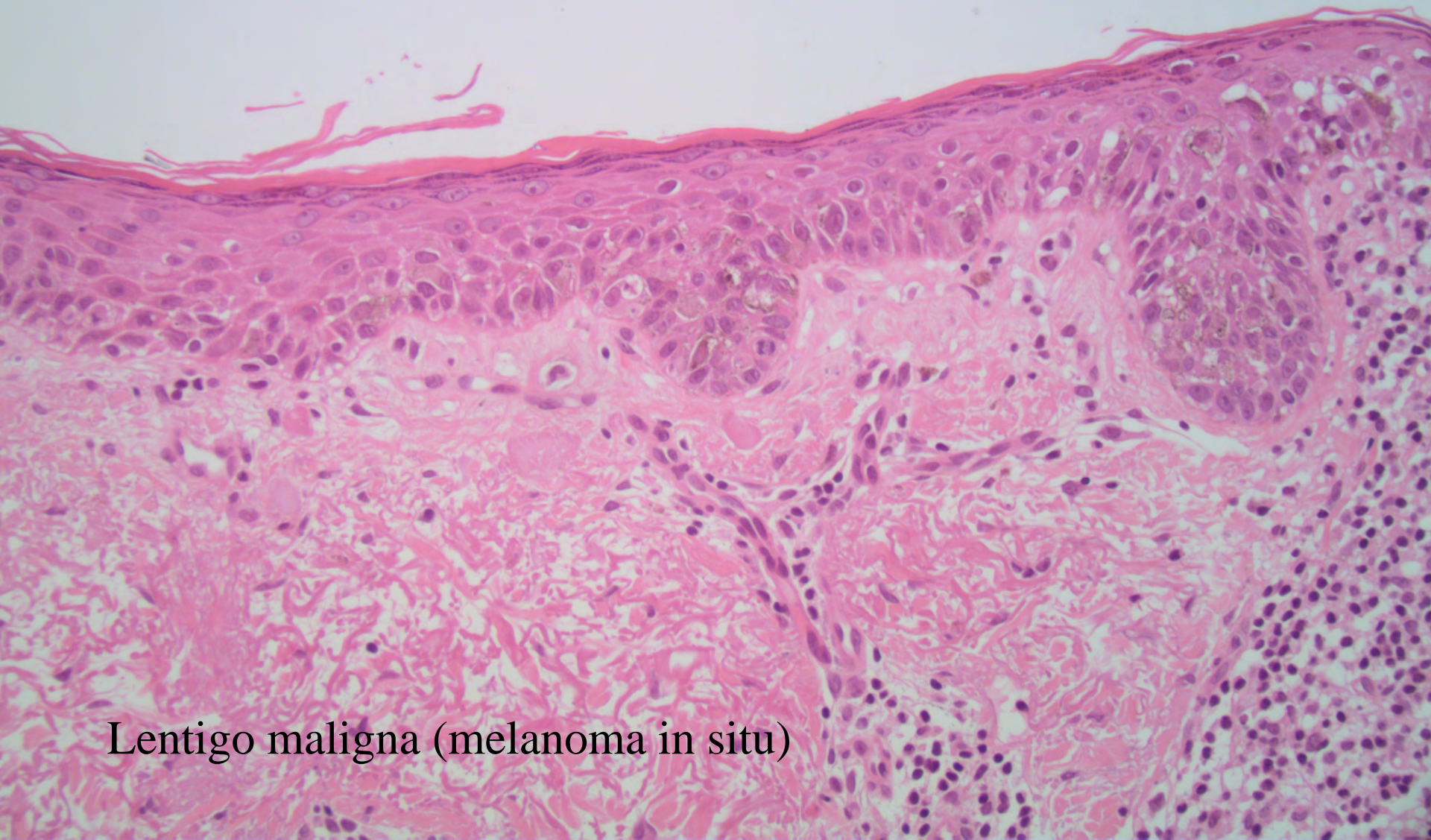


# Malignant melanoma

## Histological criteria

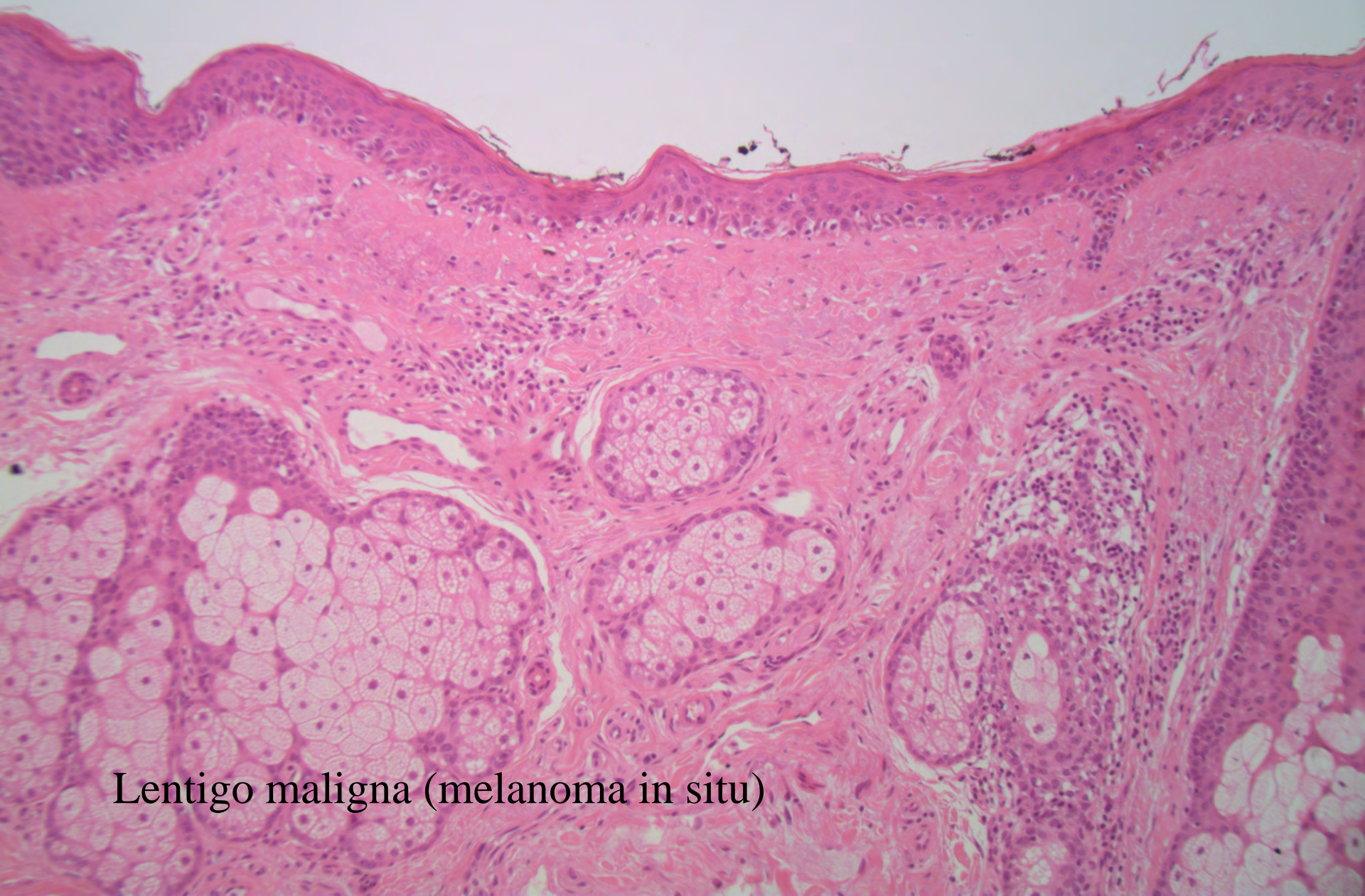
---

- Architectural
  - Pagetoid spread
  - Lack of maturation in dermal nests
- Cytological
  - Nuclear pleomorphism
  - Mitoses (deep dermal)



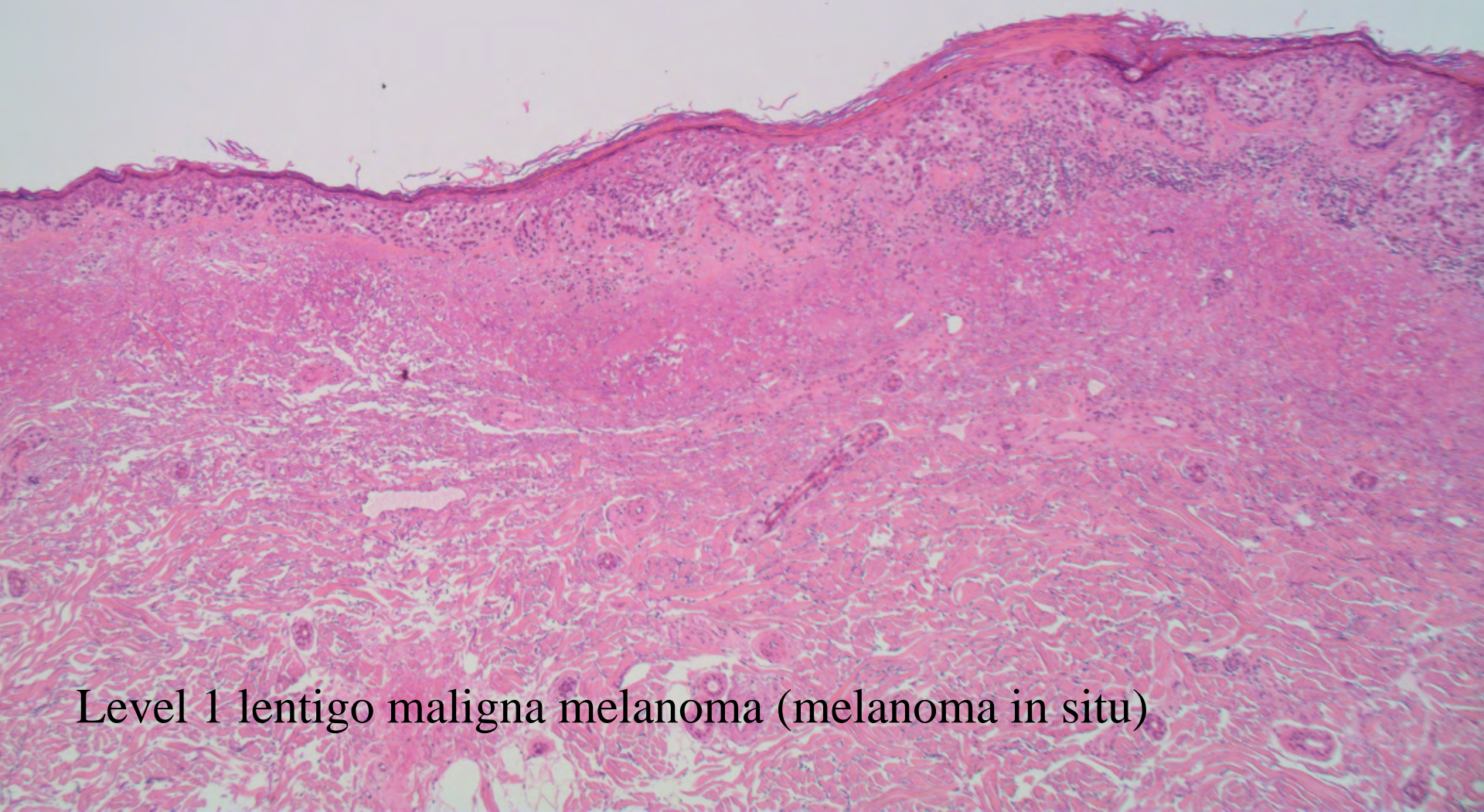
Lentigo maligna (melanoma in situ)





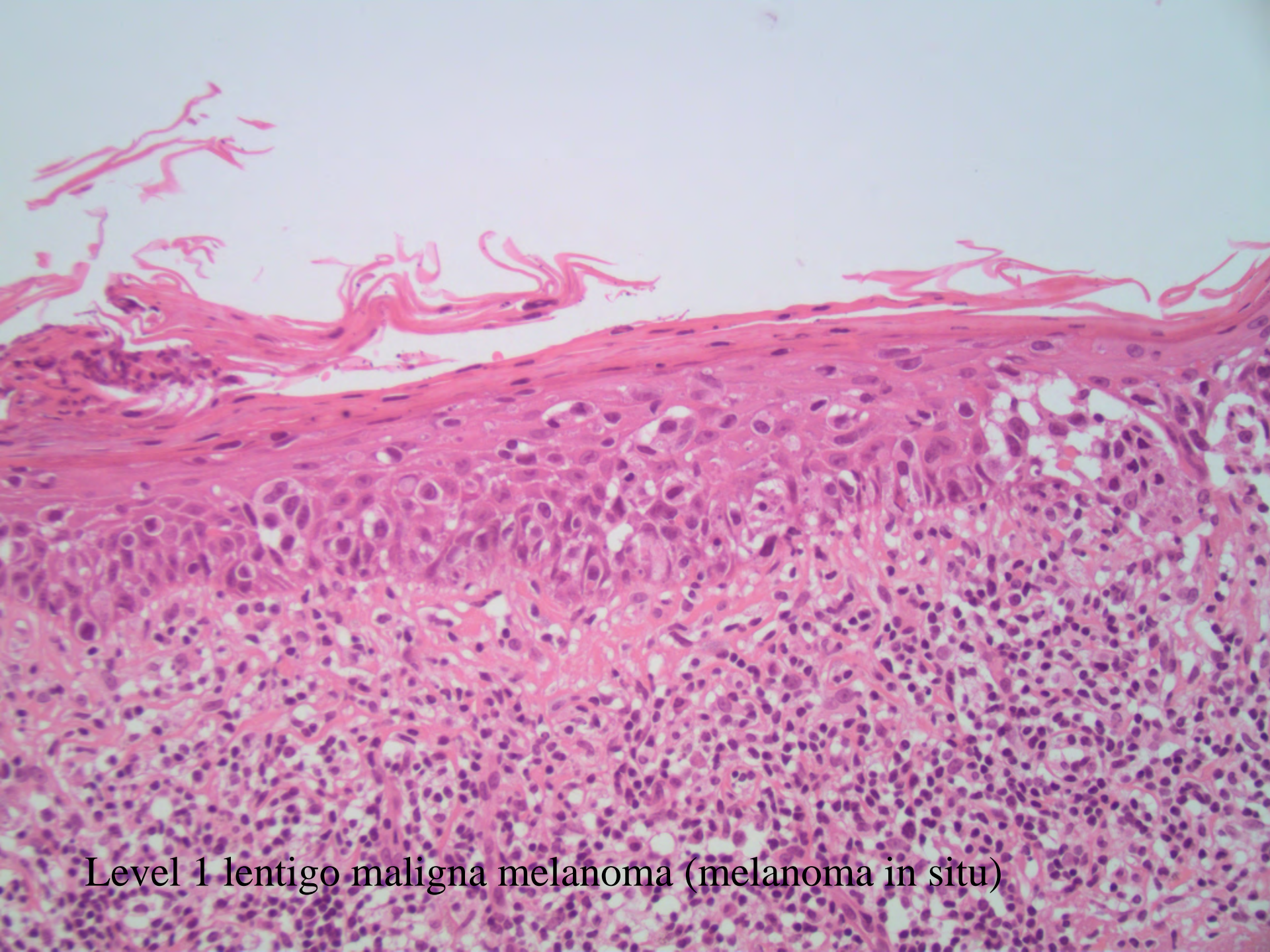
Lentigo maligna (melanoma in situ)





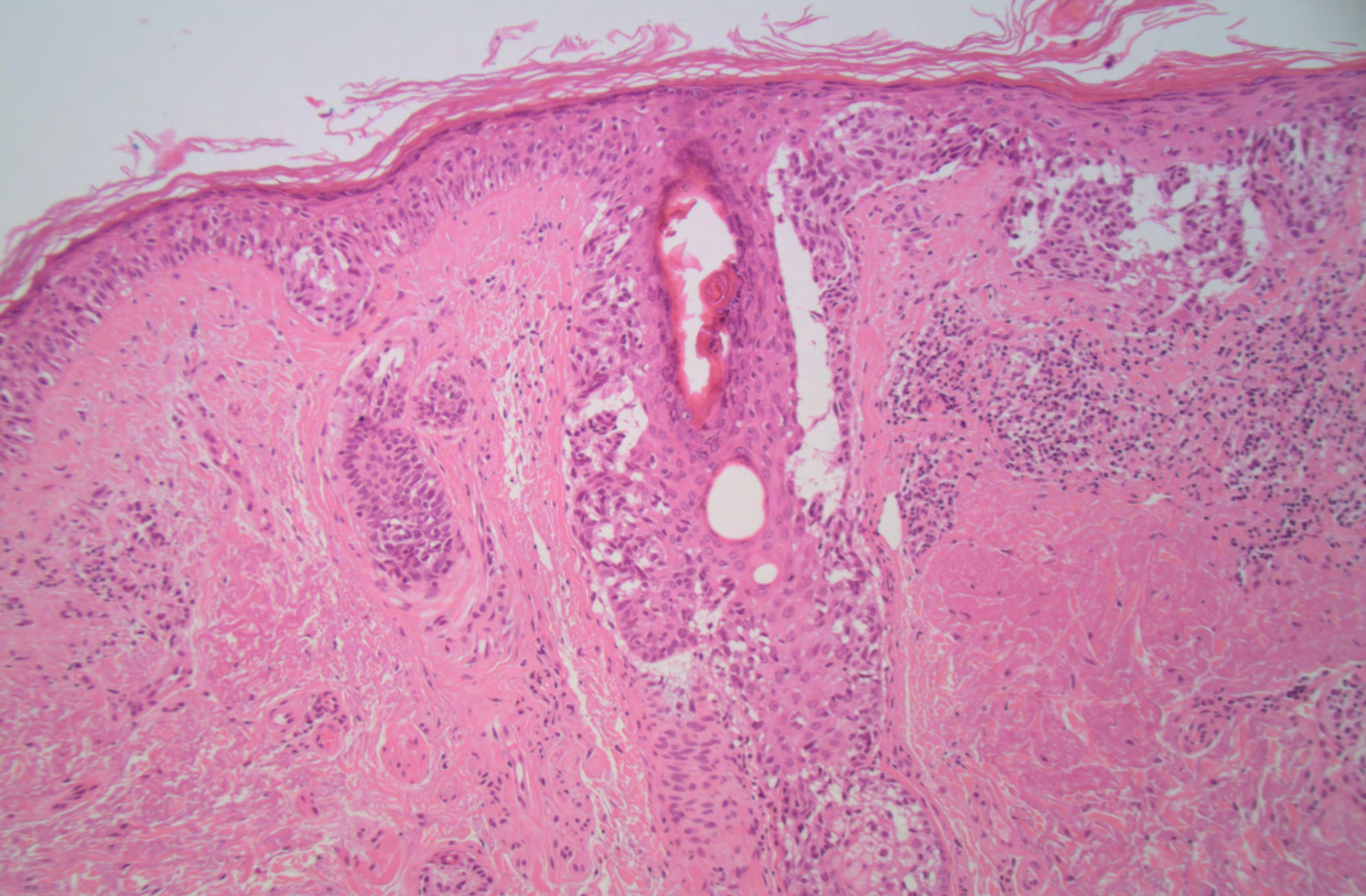
Level 1 lentigo maligna melanoma (melanoma in situ)





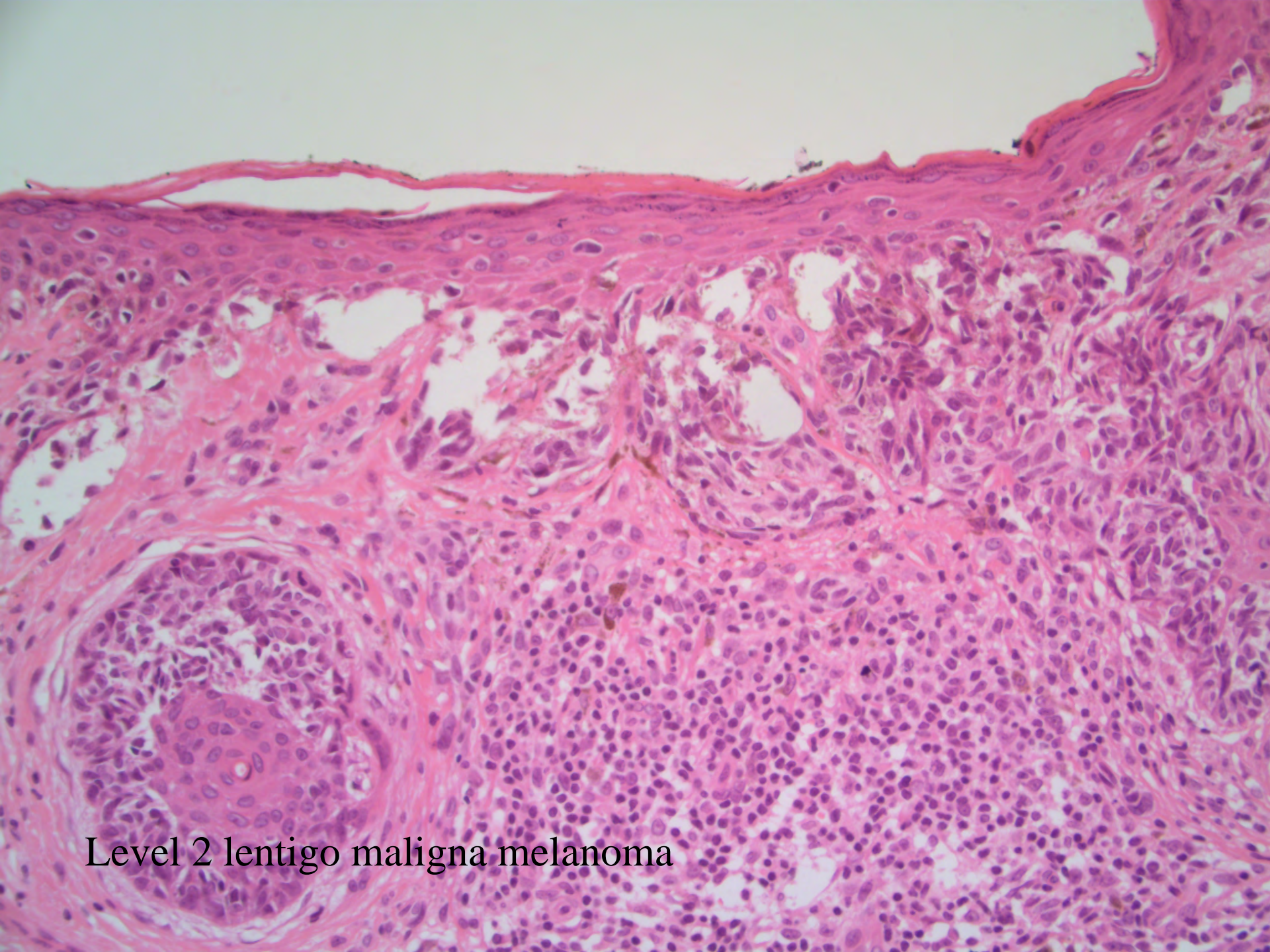
Level 1 lentigo maligna melanoma (melanoma in situ)





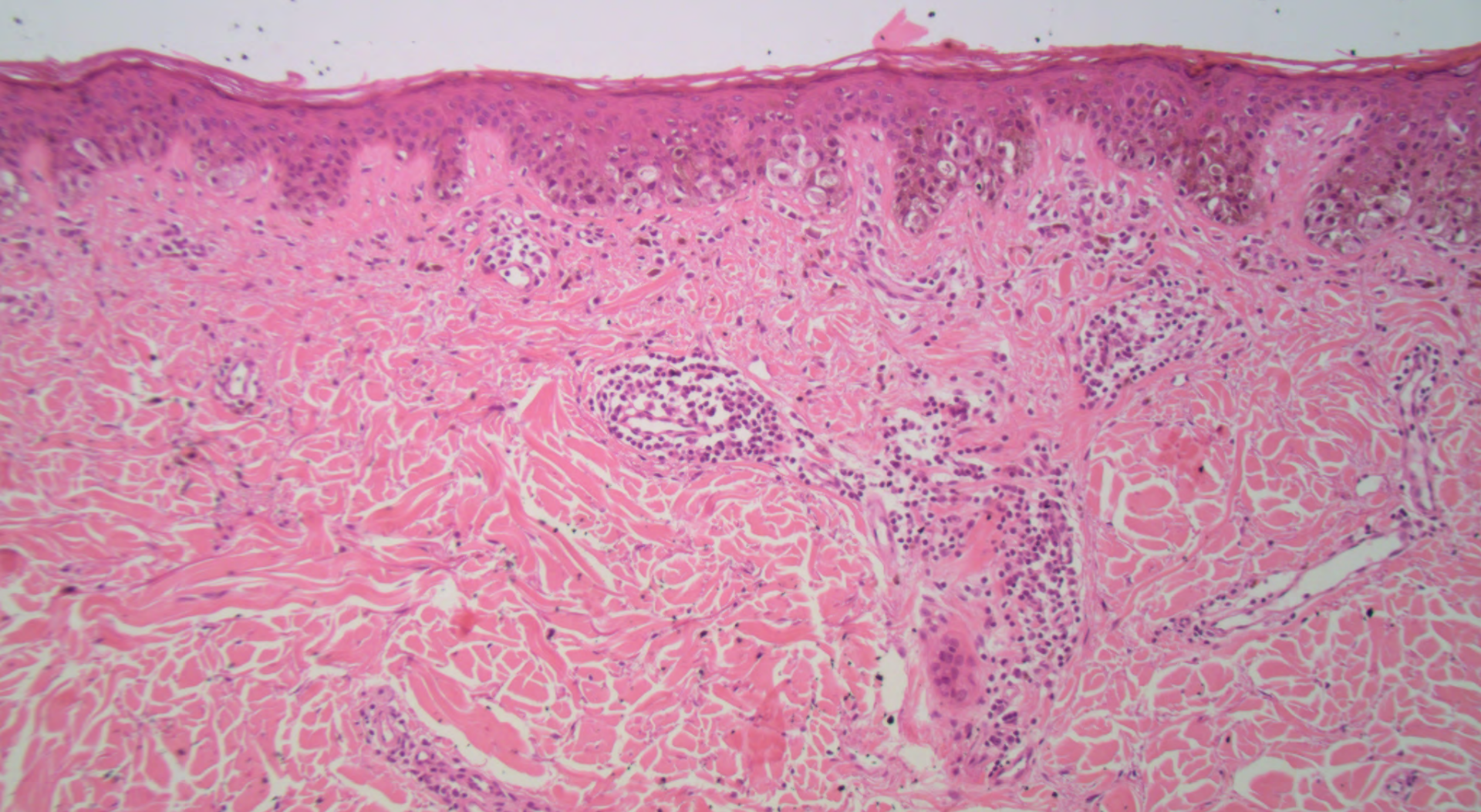
Level 1 lentigo maligna melanoma (melanoma in situ)





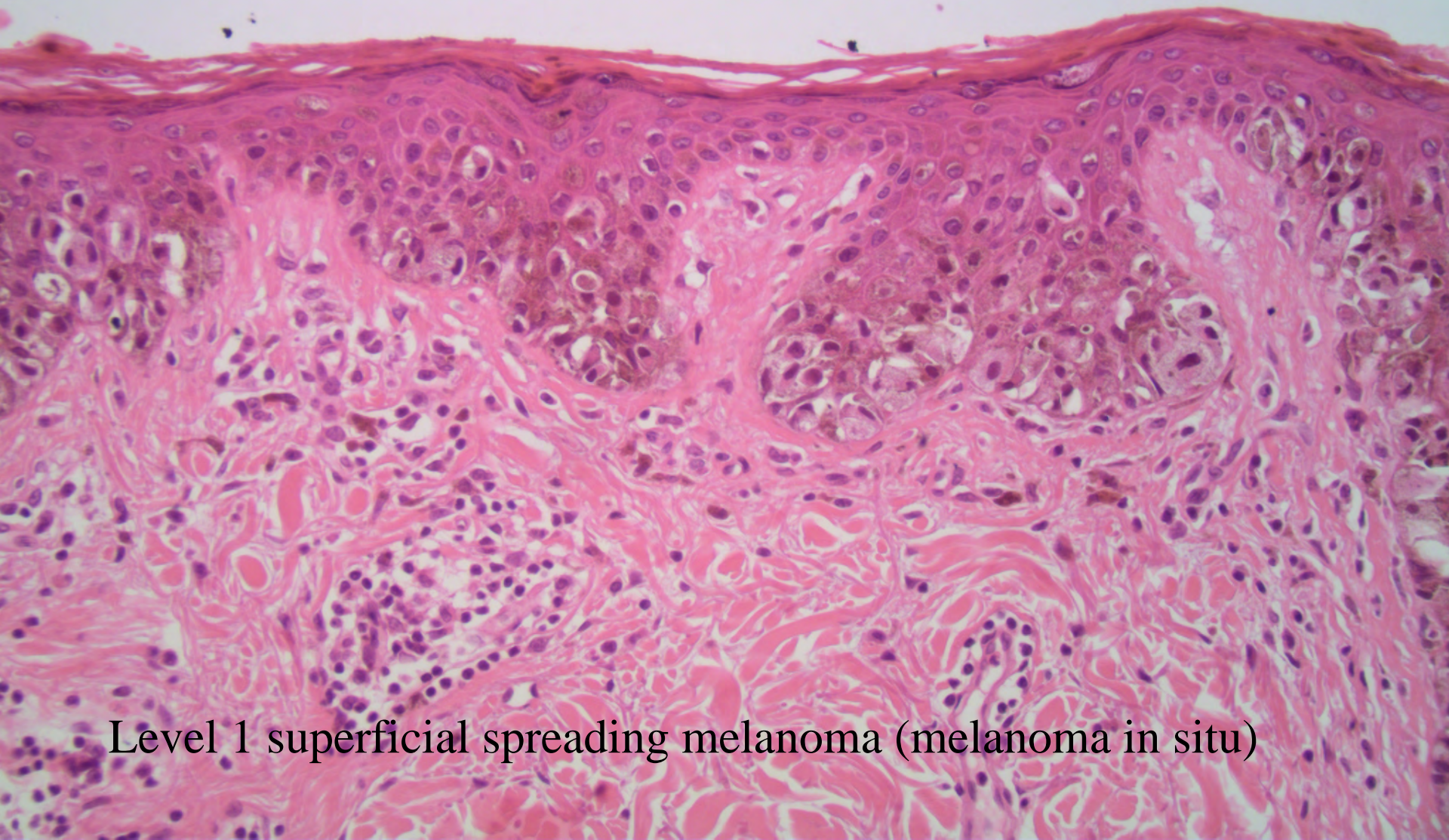
Level 2 lentigo maligna melanoma





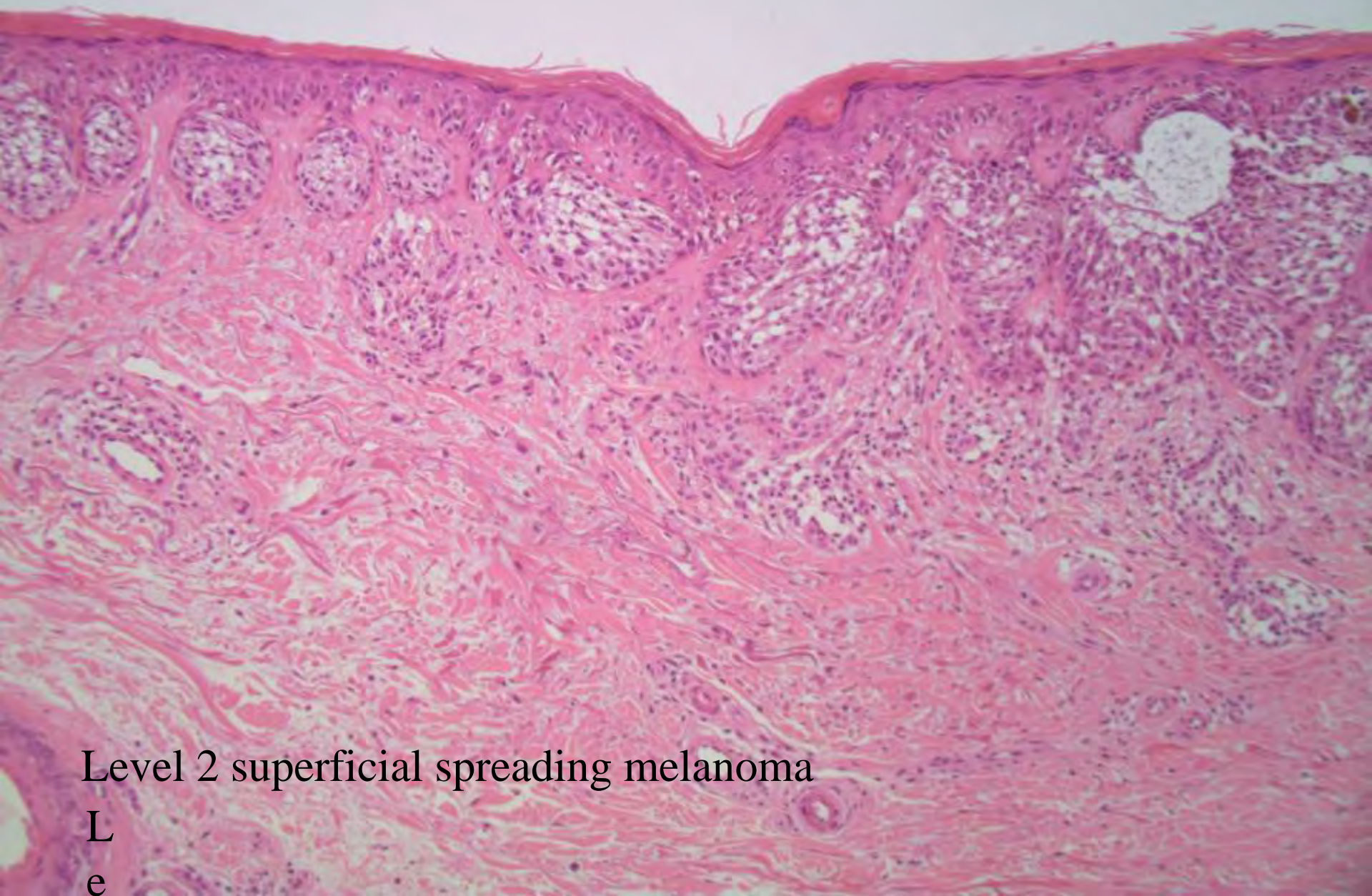
Level 1 superficial spreading melanoma (melanoma in situ)





Level 1 superficial spreading melanoma (melanoma in situ)



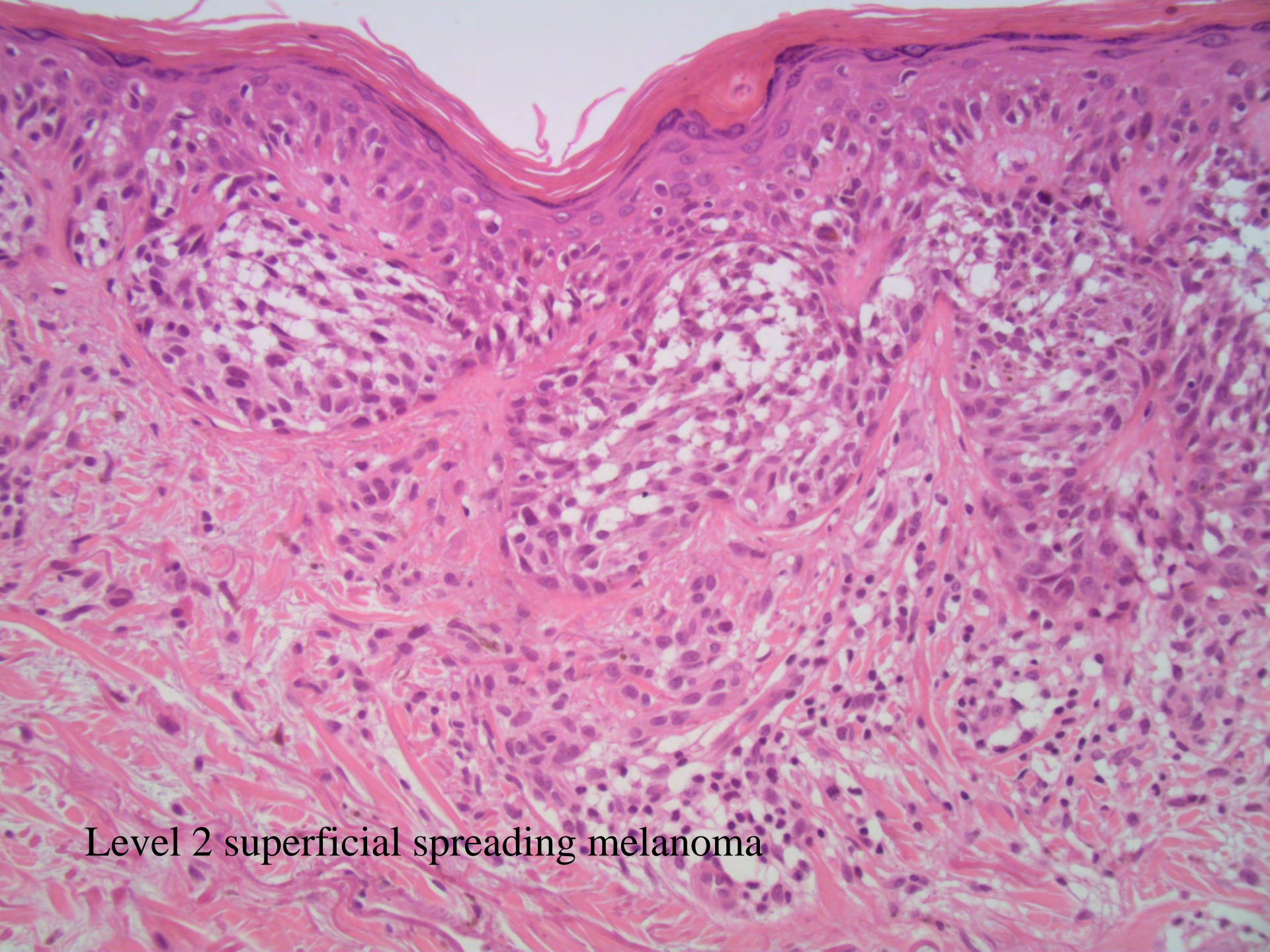


Level 2 superficial spreading melanoma

L

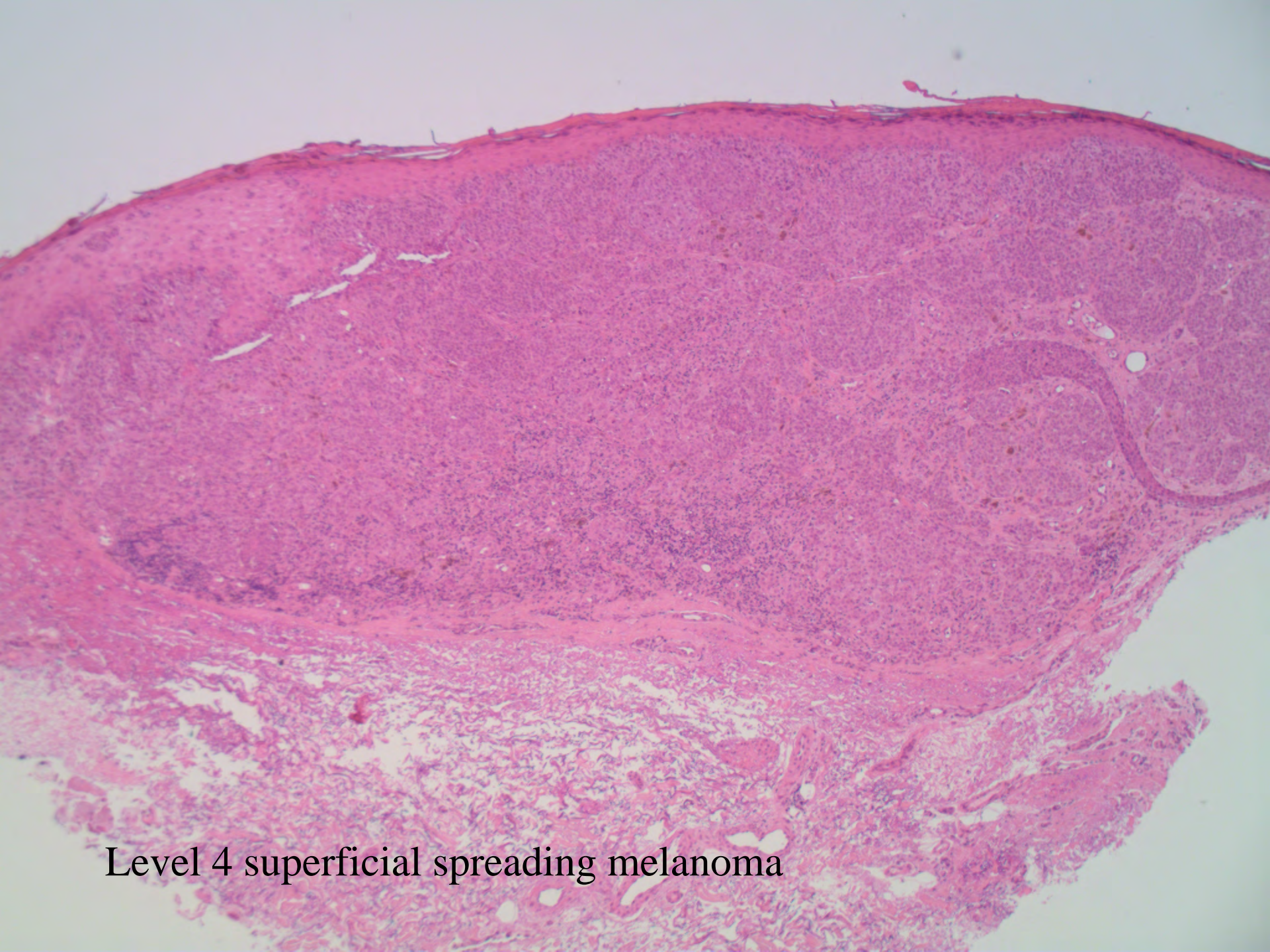
e





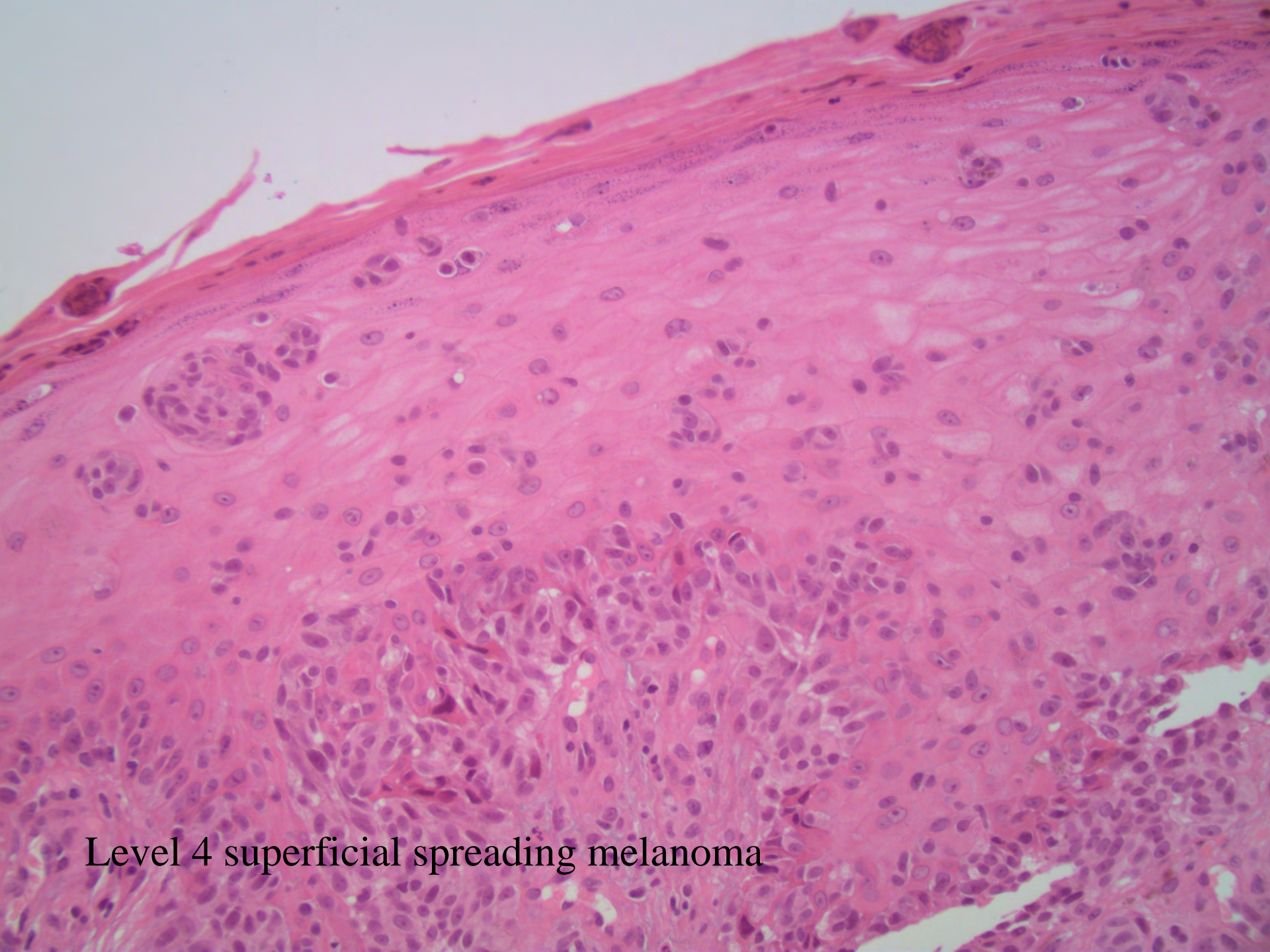
Level 2 superficial spreading melanoma





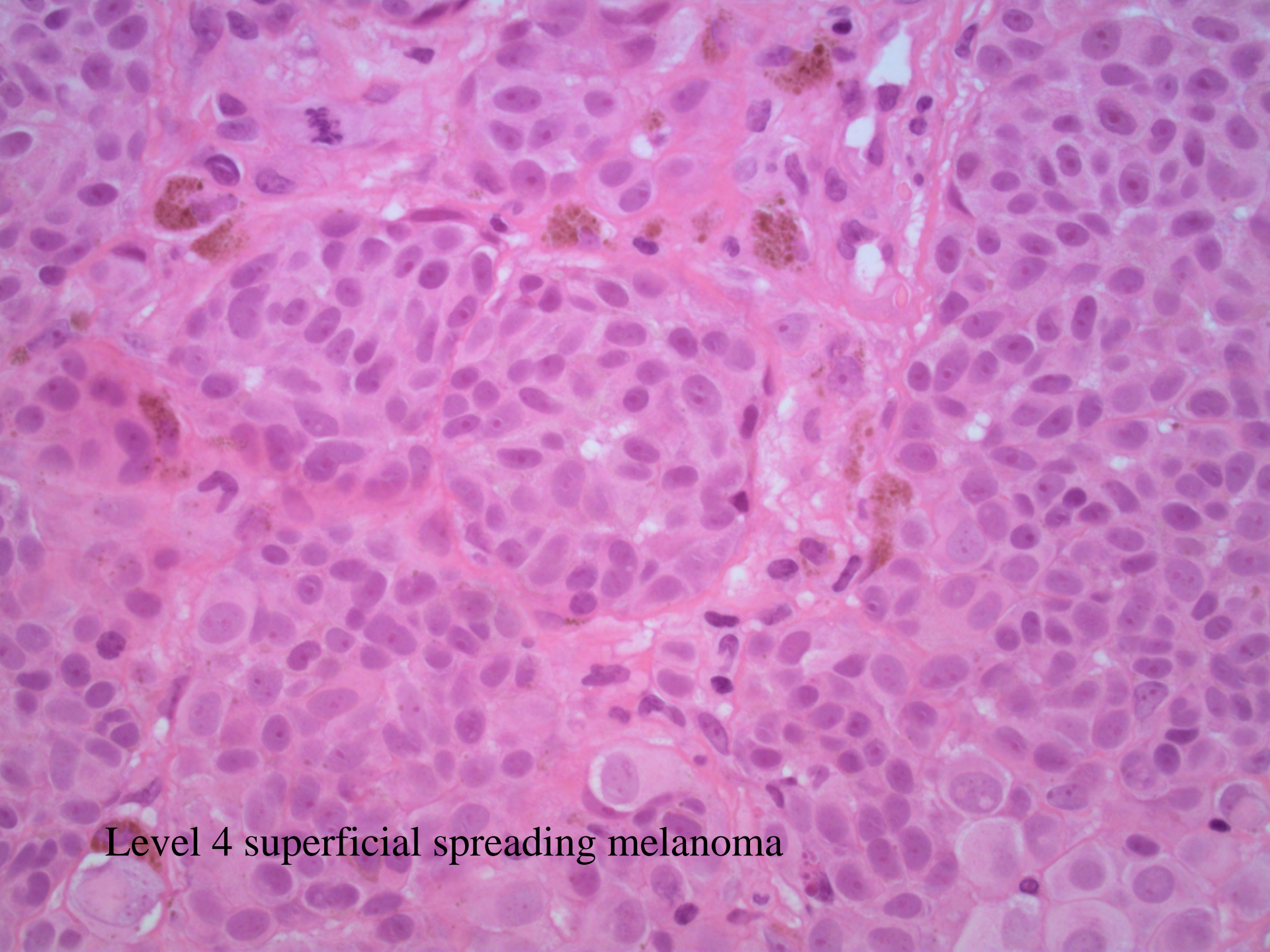
Level 4 superficial spreading melanoma





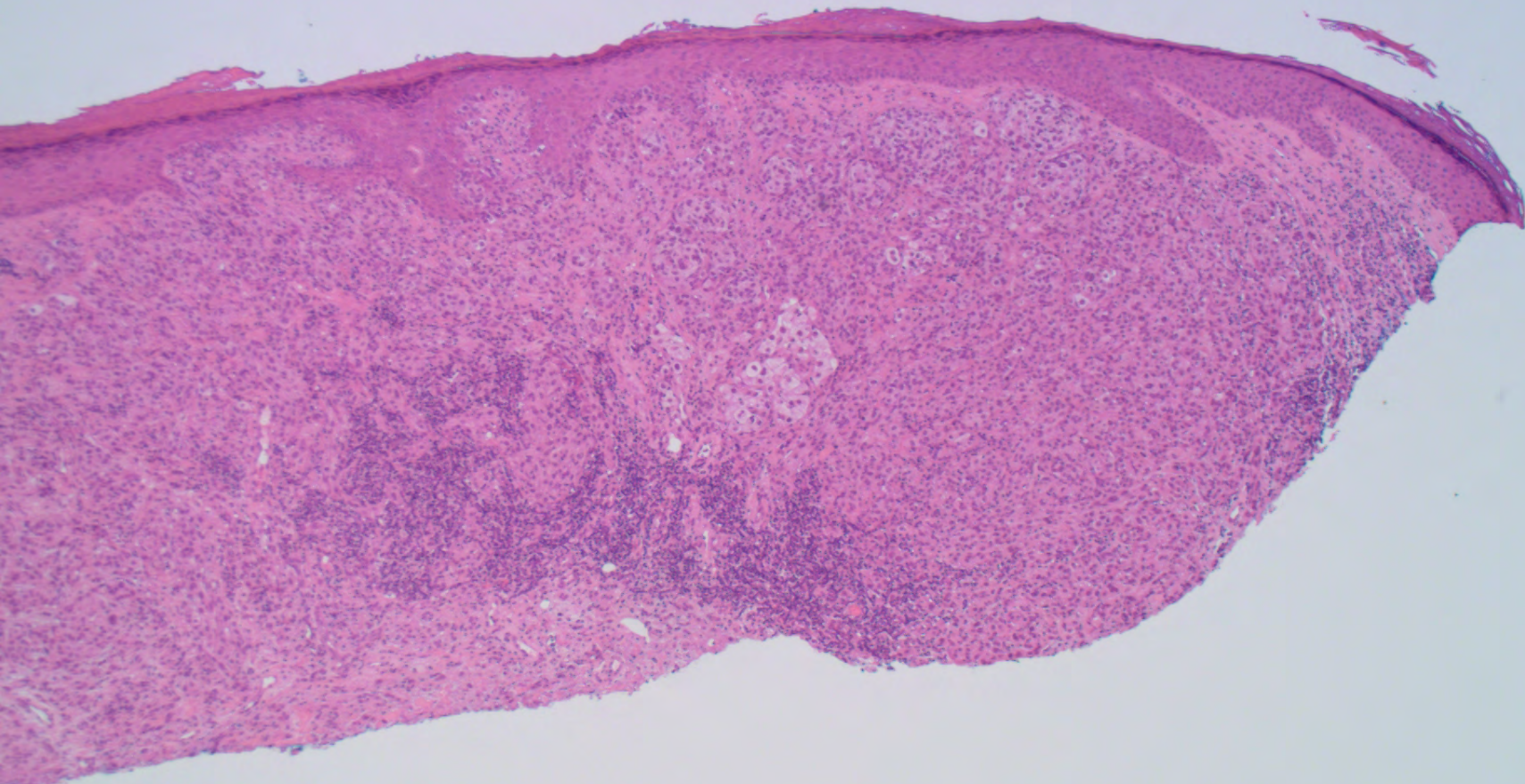
Level 4 superficial spreading melanoma





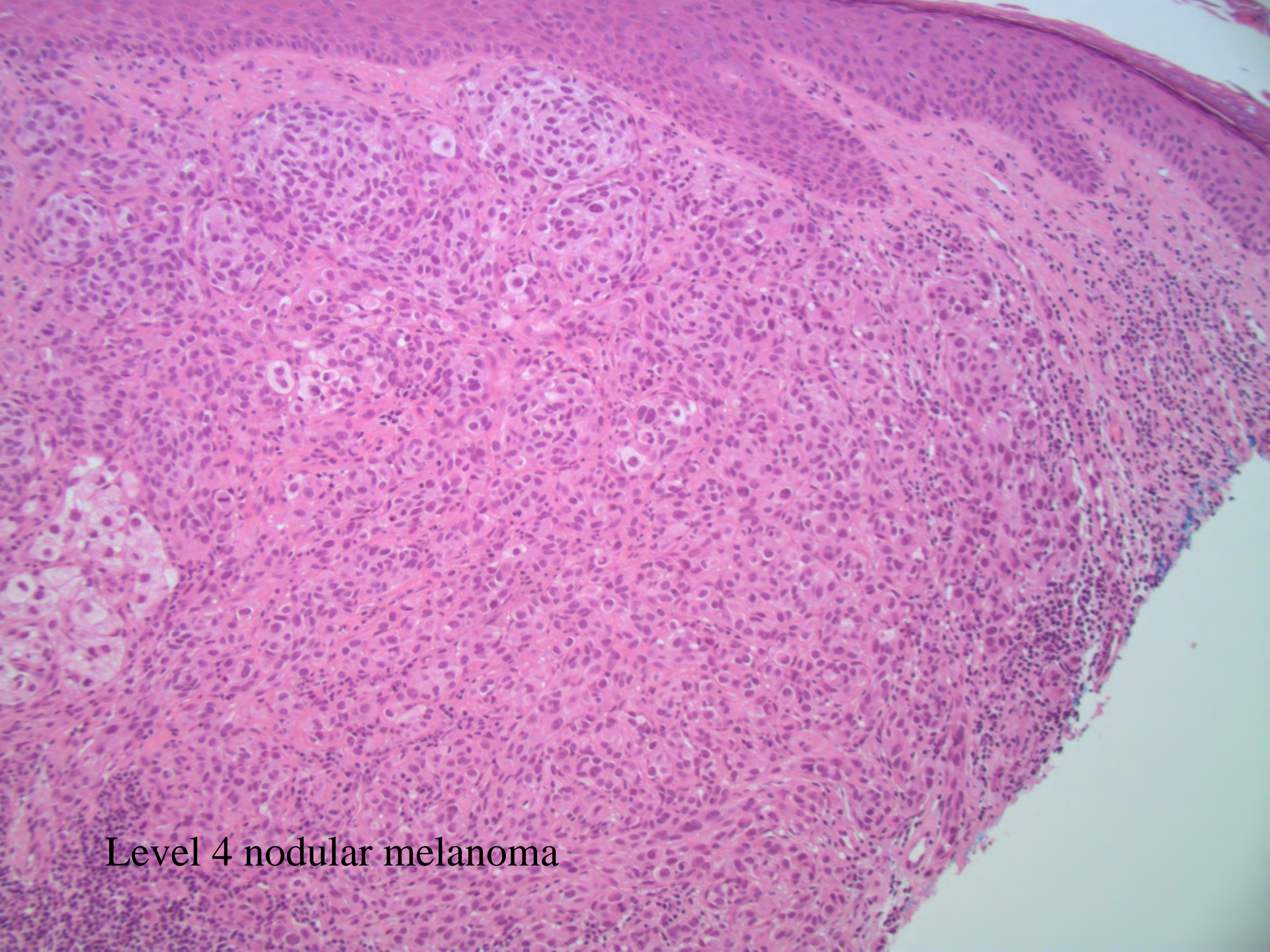
Level 4 superficial spreading melanoma





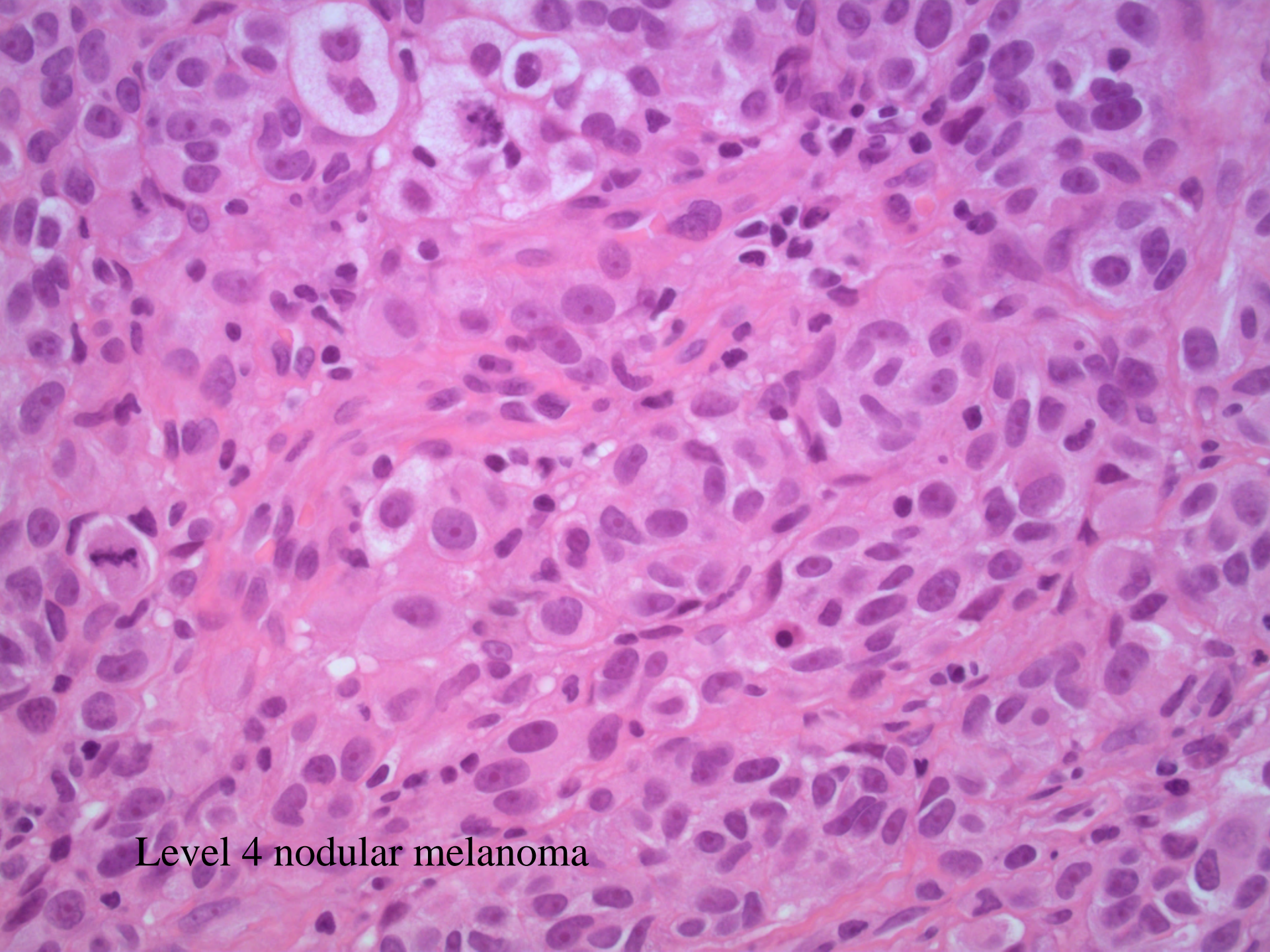
Level 4 nodular melanoma





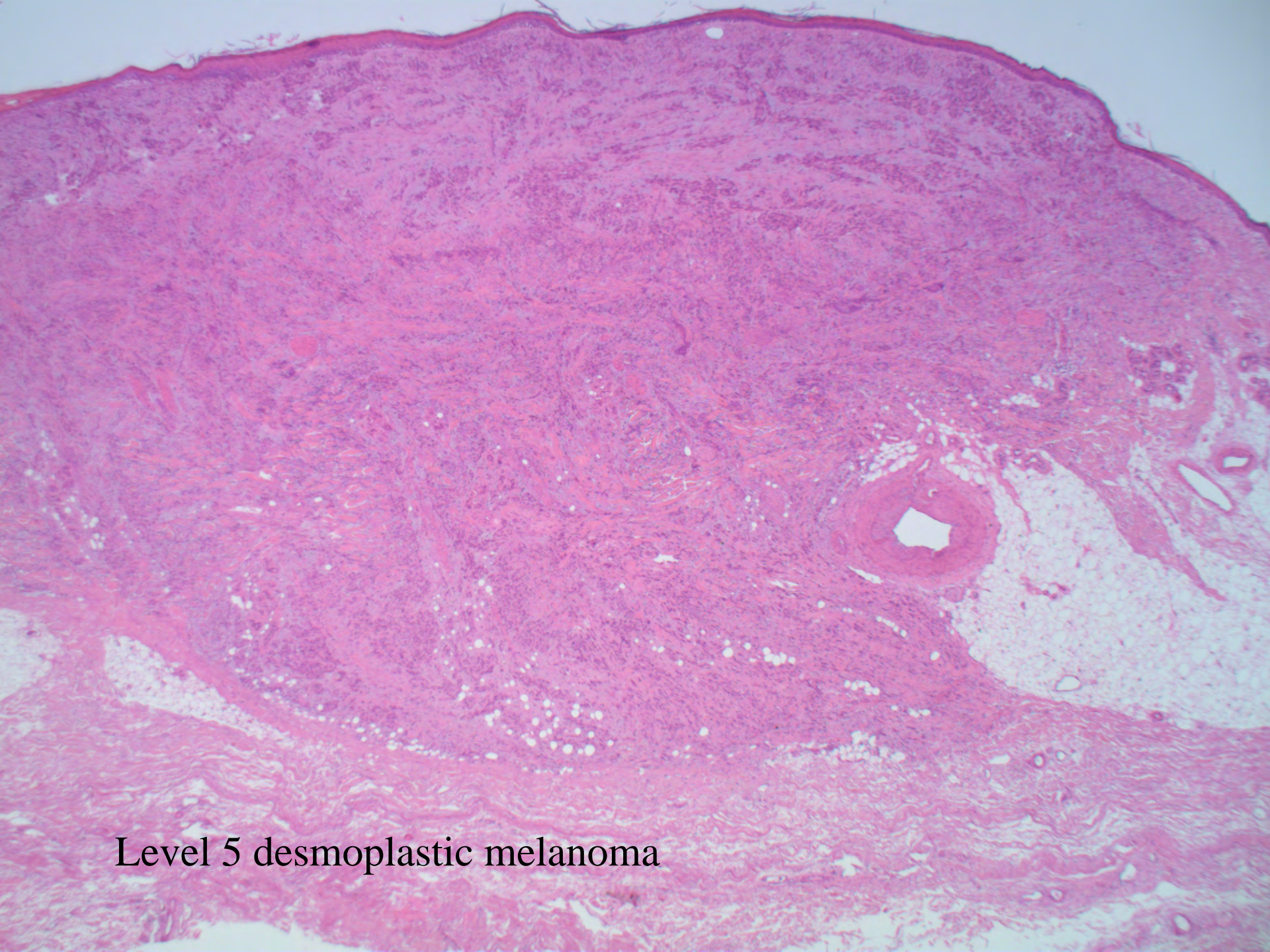
Level 4 nodular melanoma





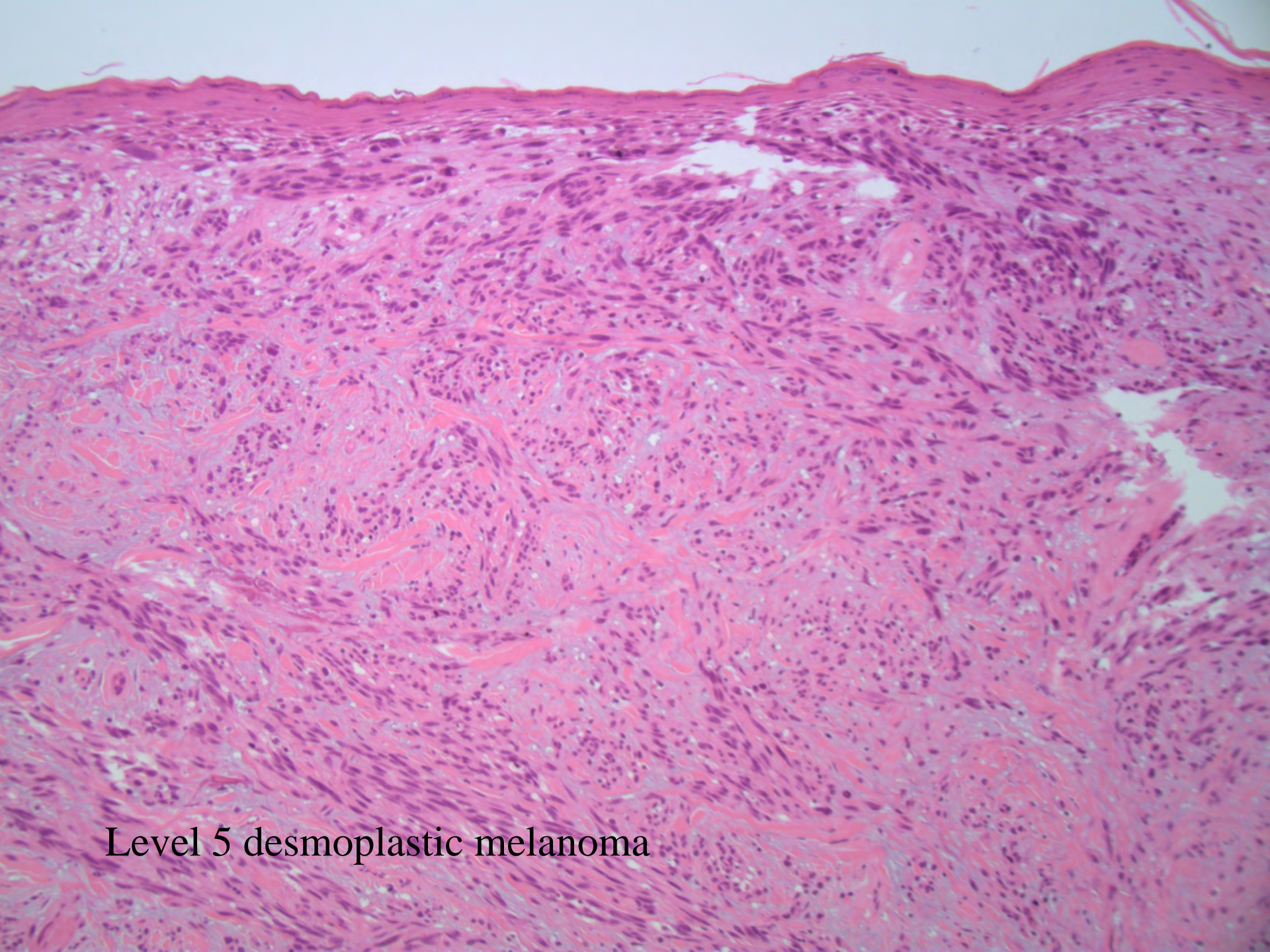
Level 4 nodular melanoma





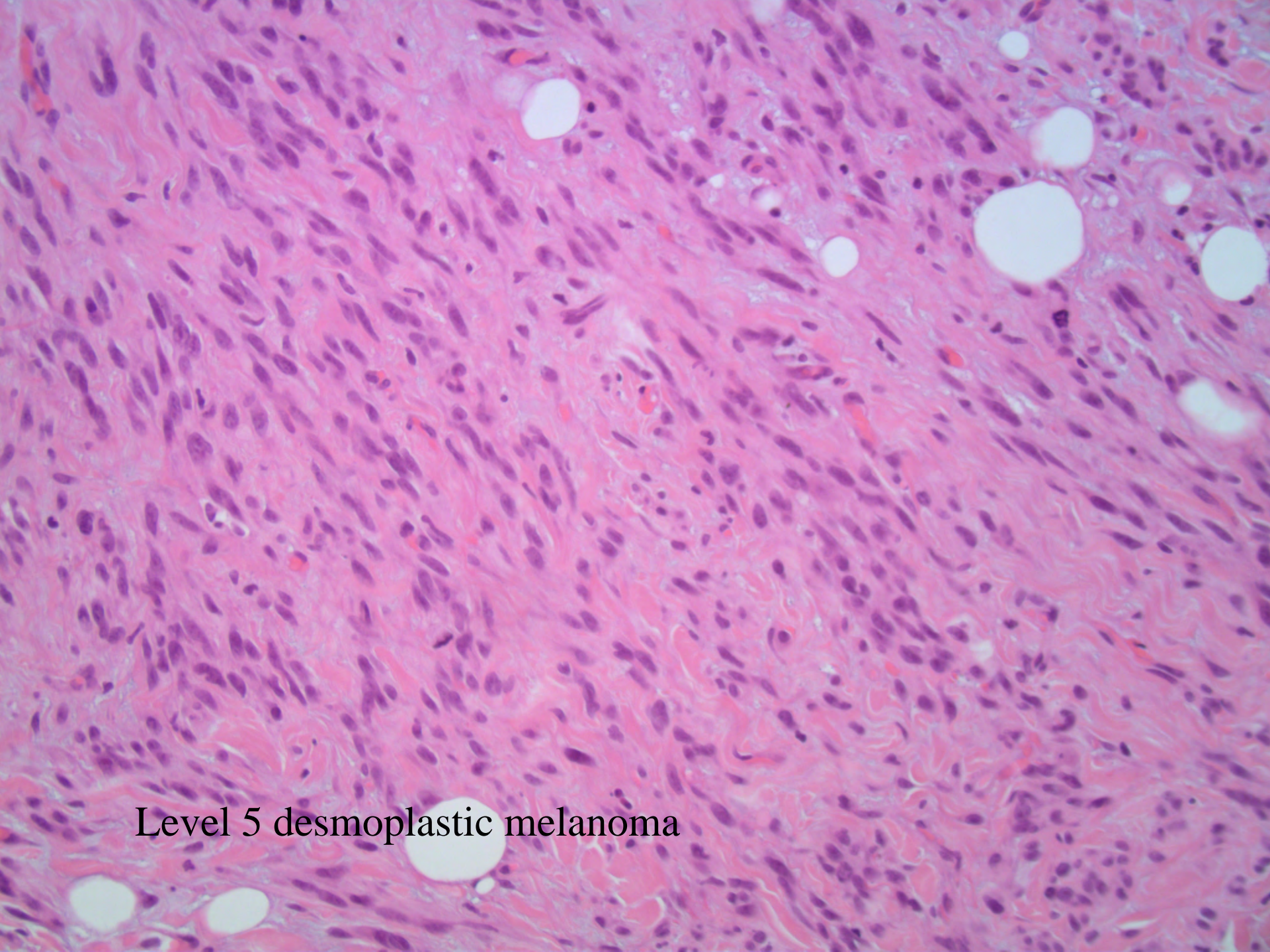
Level 5 desmoplastic melanoma





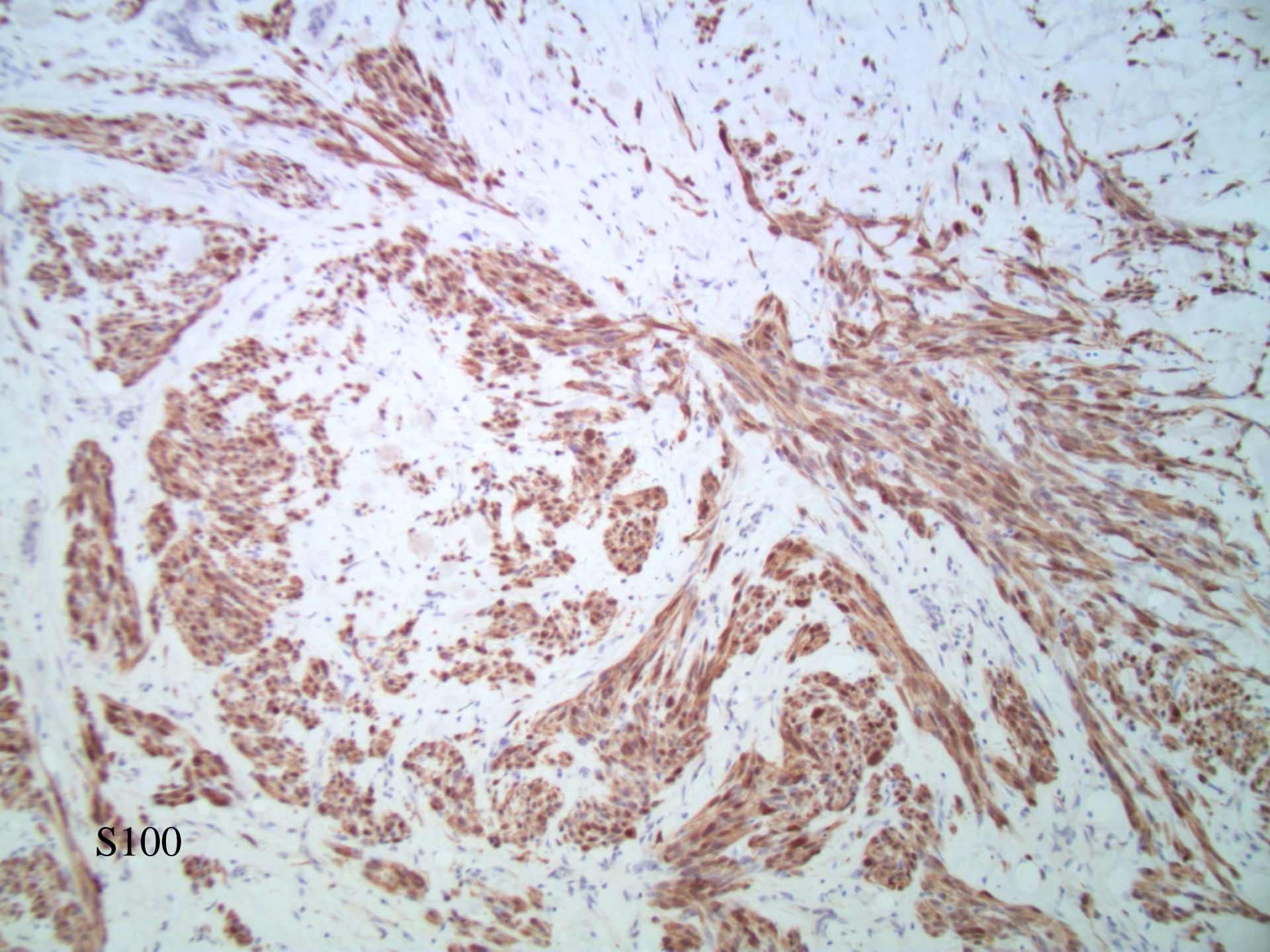
Level 5 desmoplastic melanoma






Level 5 desmoplastic melanoma





S100




# Malignant melanoma

## Synoptic report

---

- Site
- Thickness (Breslow)
- Level (Clark)
- Architectural type
- Cell type
- In situ component






# Malignant melanoma

## Synoptic report

---

- Invasive component
  - Mitotic count
  - Tumour infiltrating lymphocytes
  - Microsatellites
  - Vascular invasion
  - Perineural invasion



# Malignant melanoma

## Synoptic report

---

- Regression – extent, full or partial
- Ulceration – extent
- Associated naevus
- Margins
  - Completely excised – in situ, invasive
  - Extending to margins



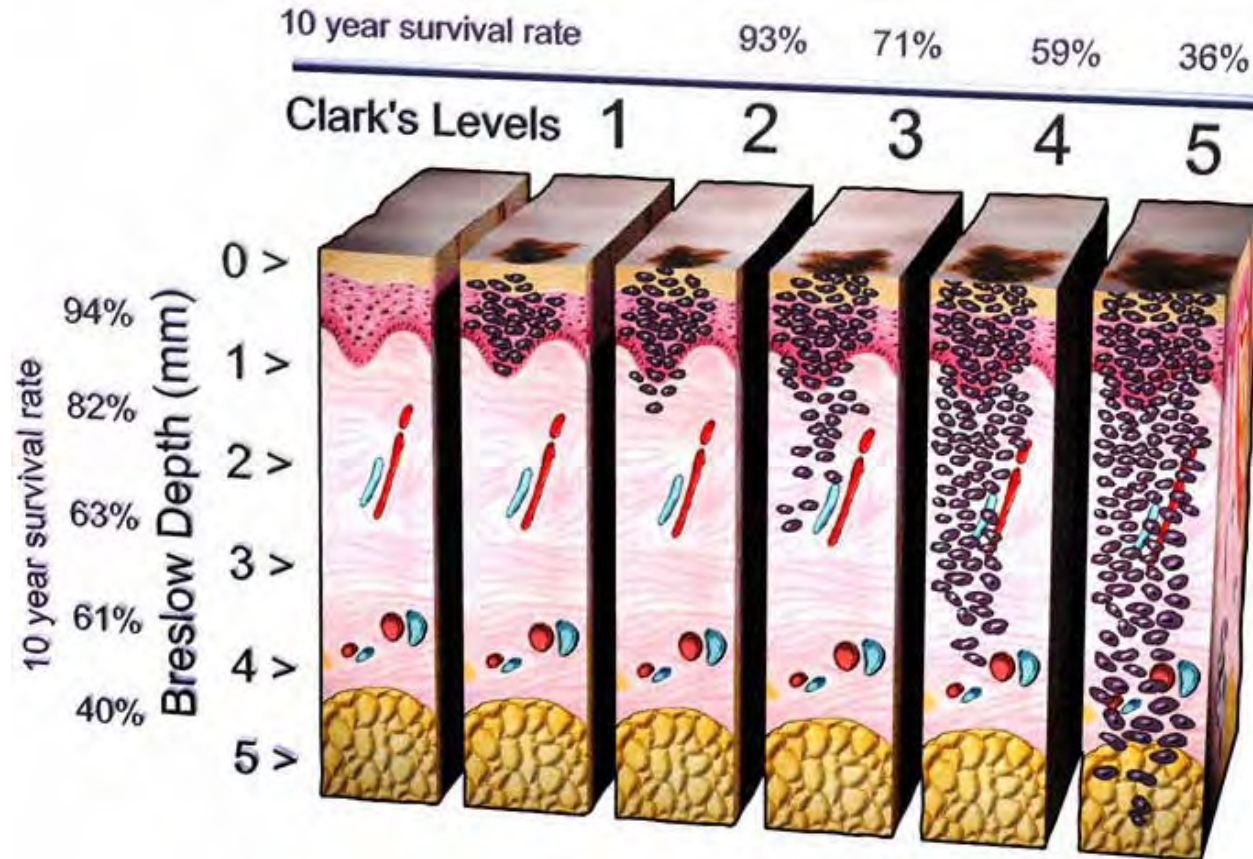


# Malignant melanoma Management

---

- Resection margins
  - MIS: 0.5mm
  - <1mm: 1cm
  - 1-2mm: 1-2cm
  - 2-4mm: 2cm
  - >4mm: 3cm
- Sentinel lymph node biopsy

# Malignant melanoma Prognosis



2001 Image by Med-Art ~ <http://www.med-ars.it>



MELBOURNE PATHOLOGY

*"We take it personally"*



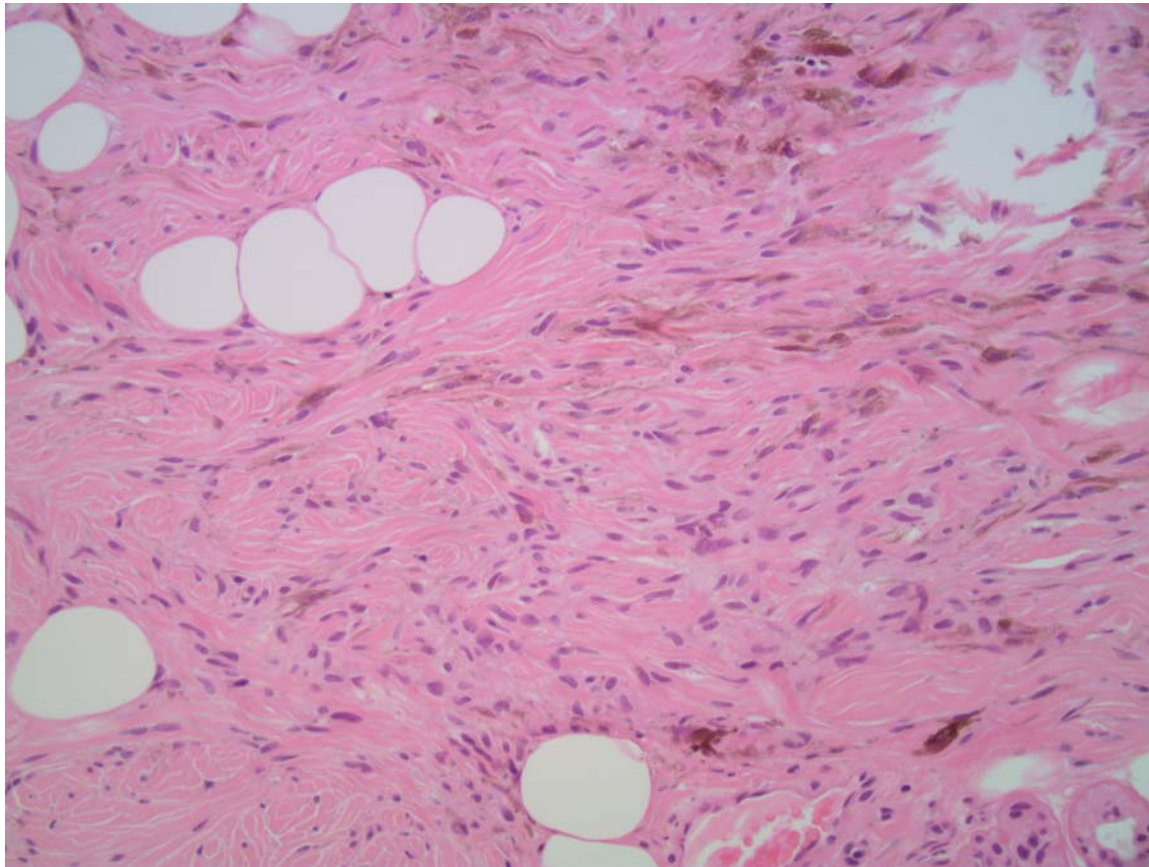


---

# Test

Have you been concentrating?

# Diagnosis?

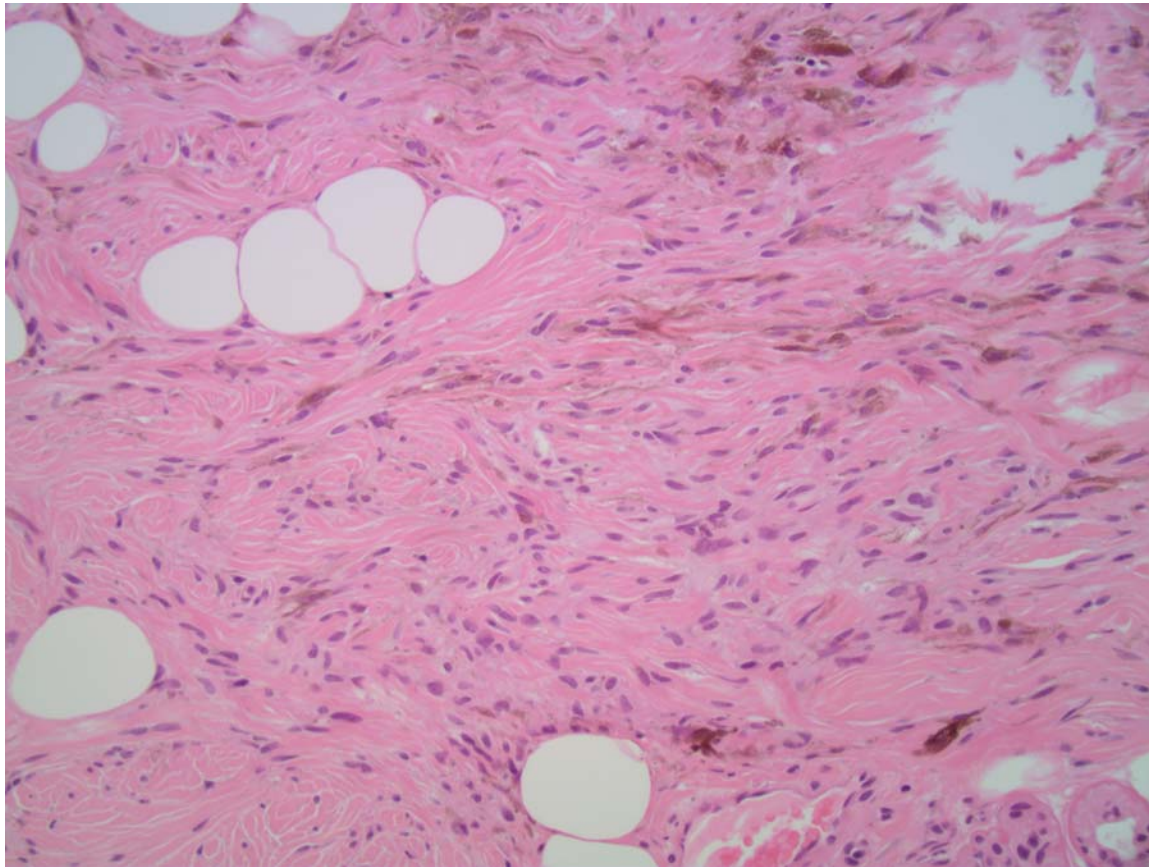




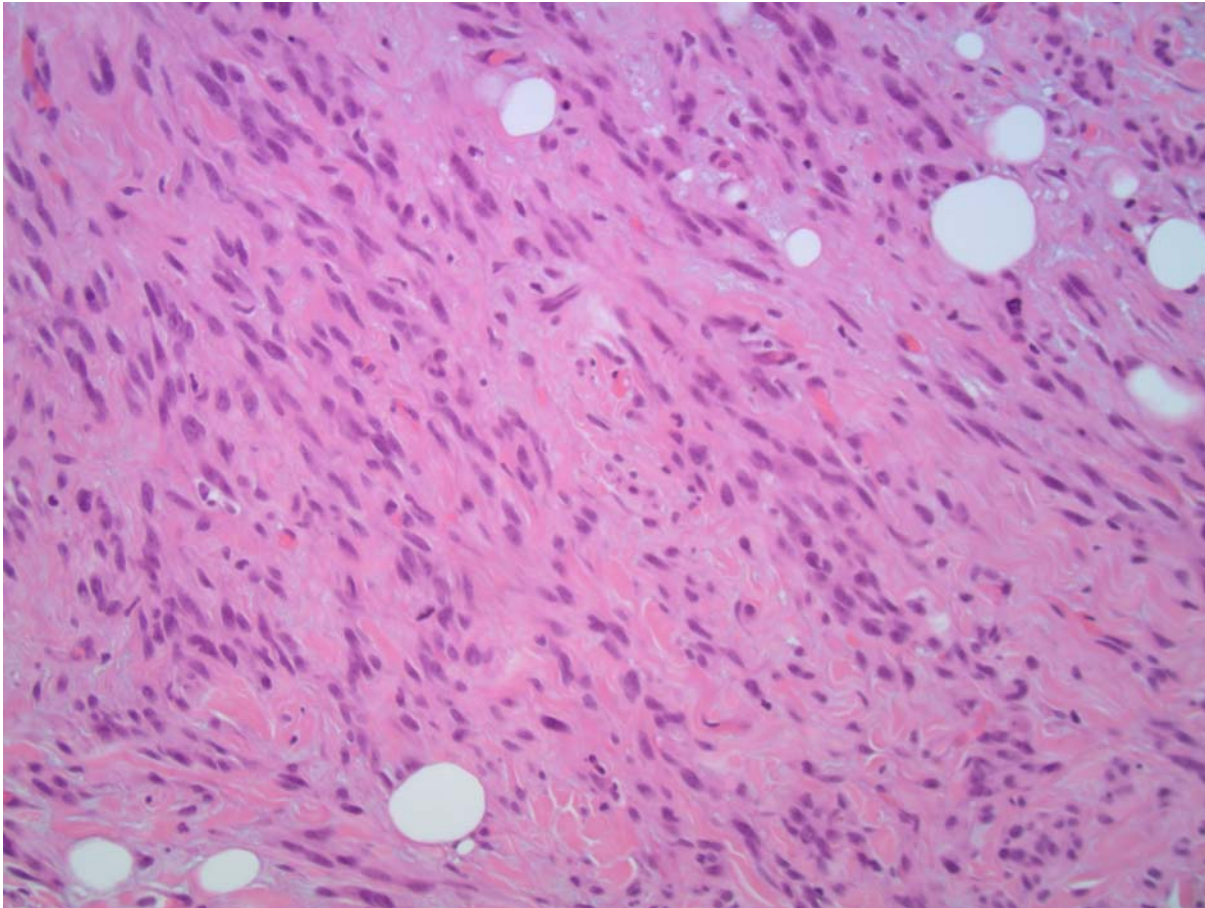


# Blue naevus

---

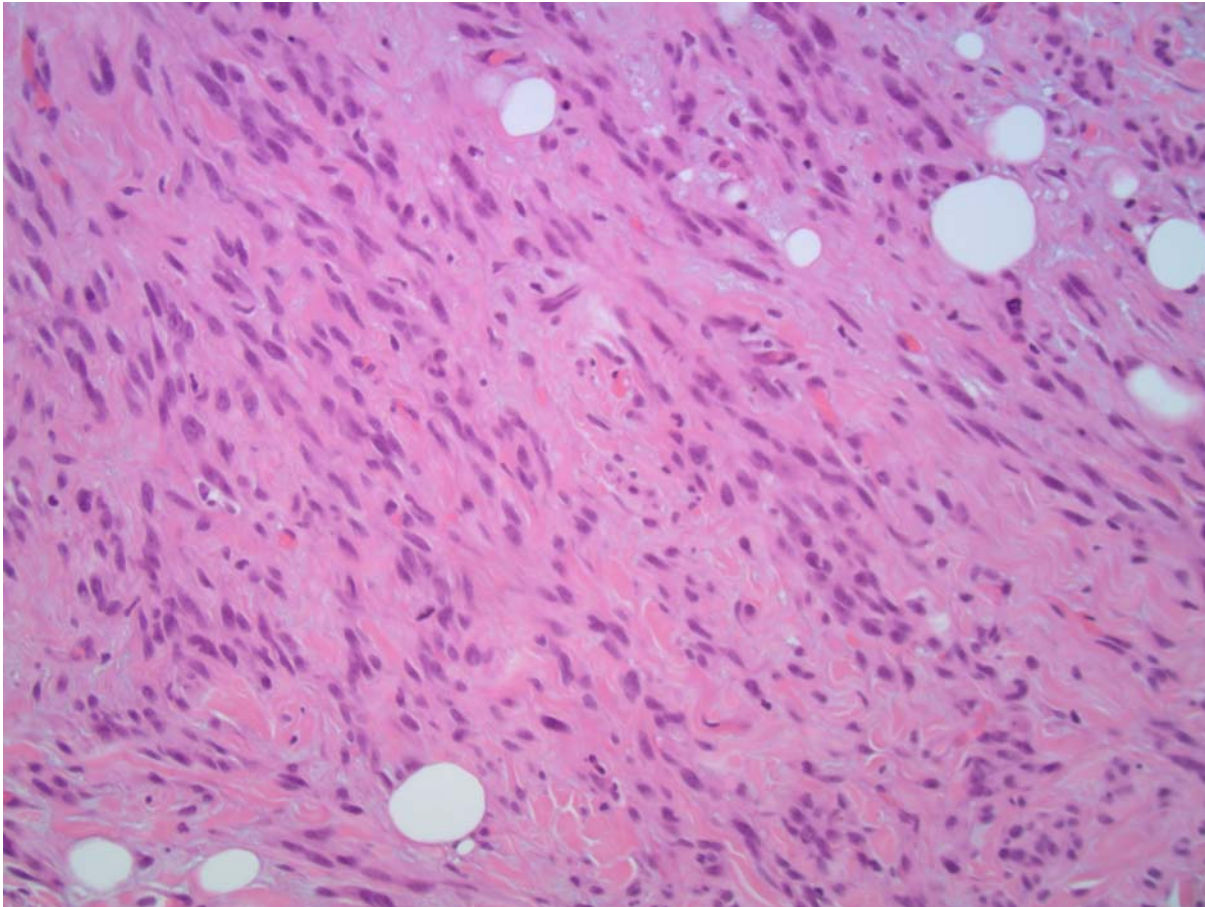


# Diagnosis?



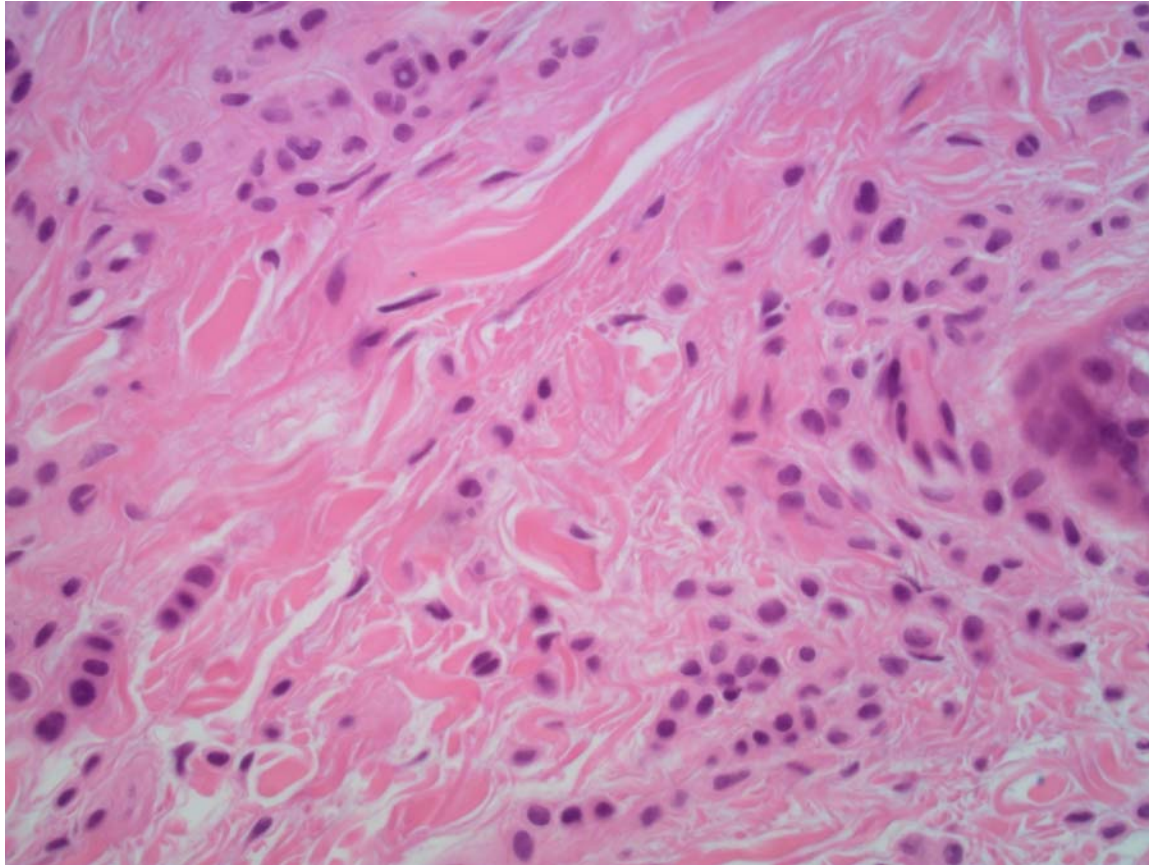


# Desmoplastic melanoma



# Diagnosis?

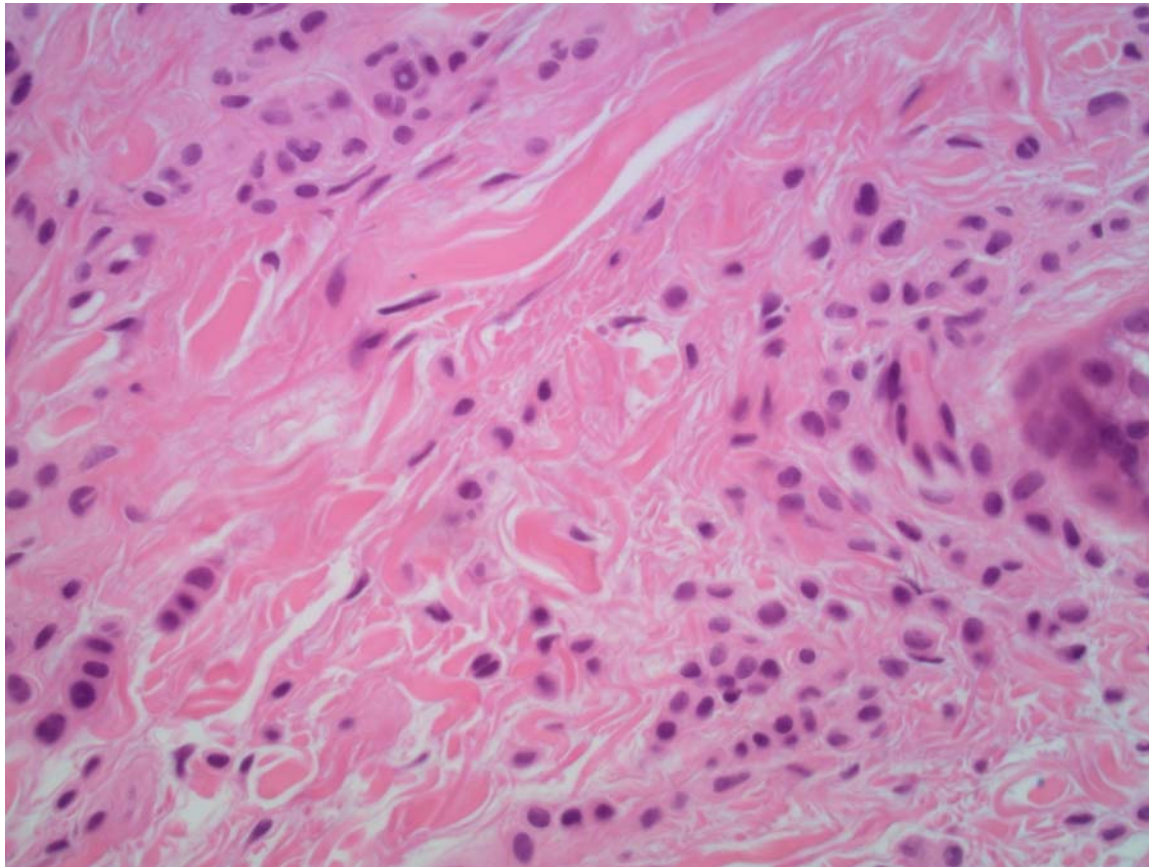
---





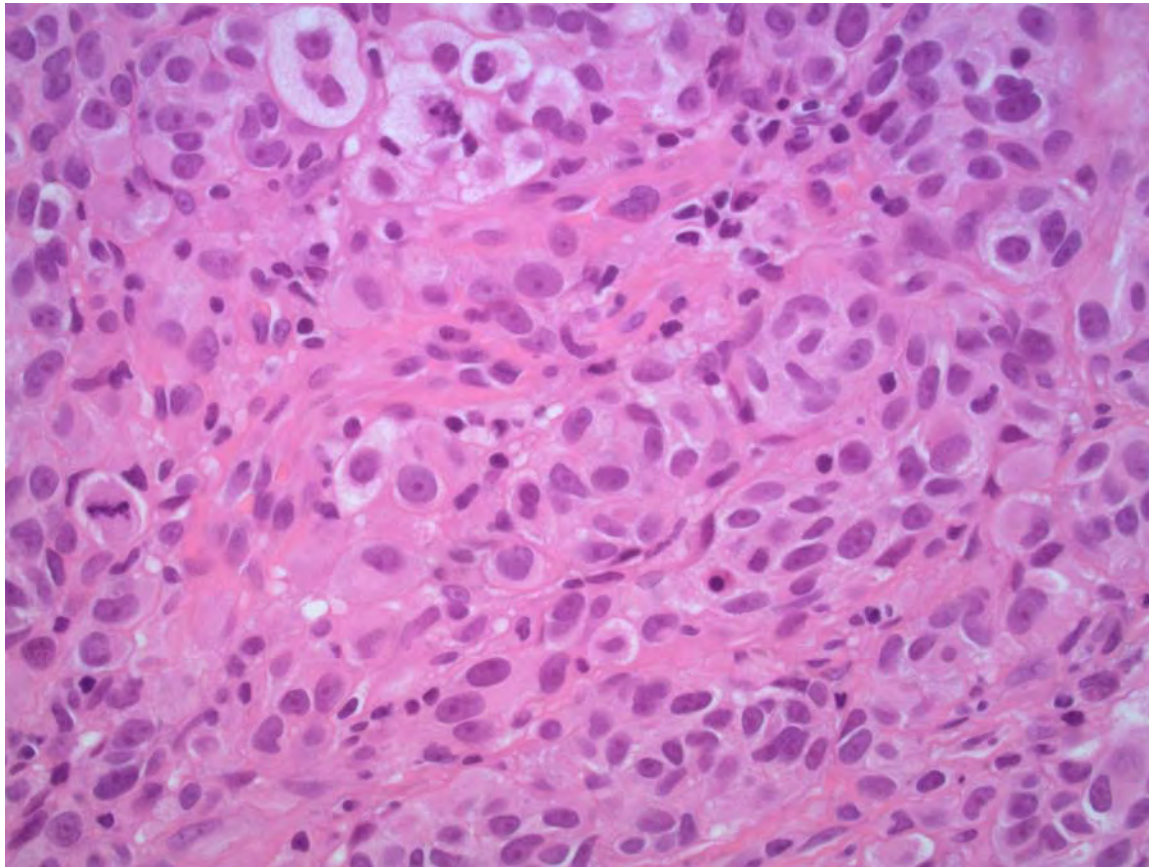
# Intradermal naevus

---



# Diagnosis?

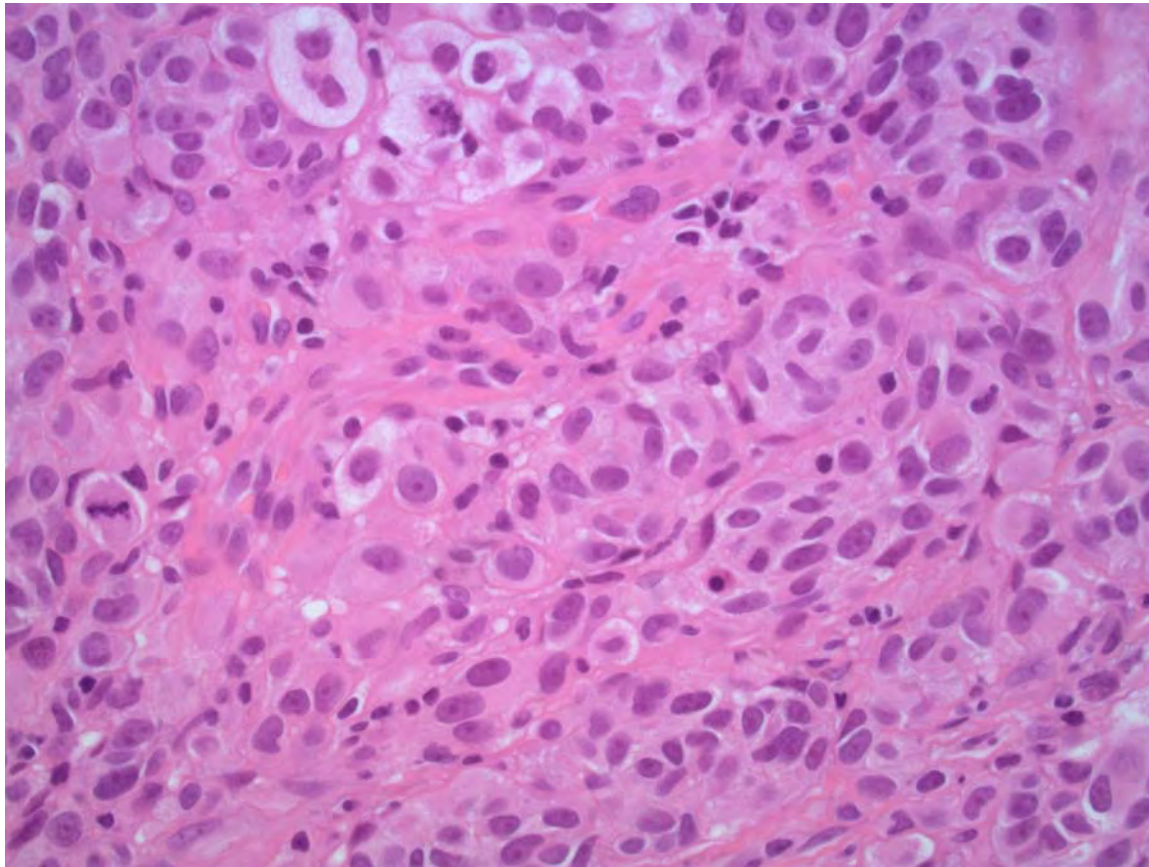
---





# Invasive melanoma

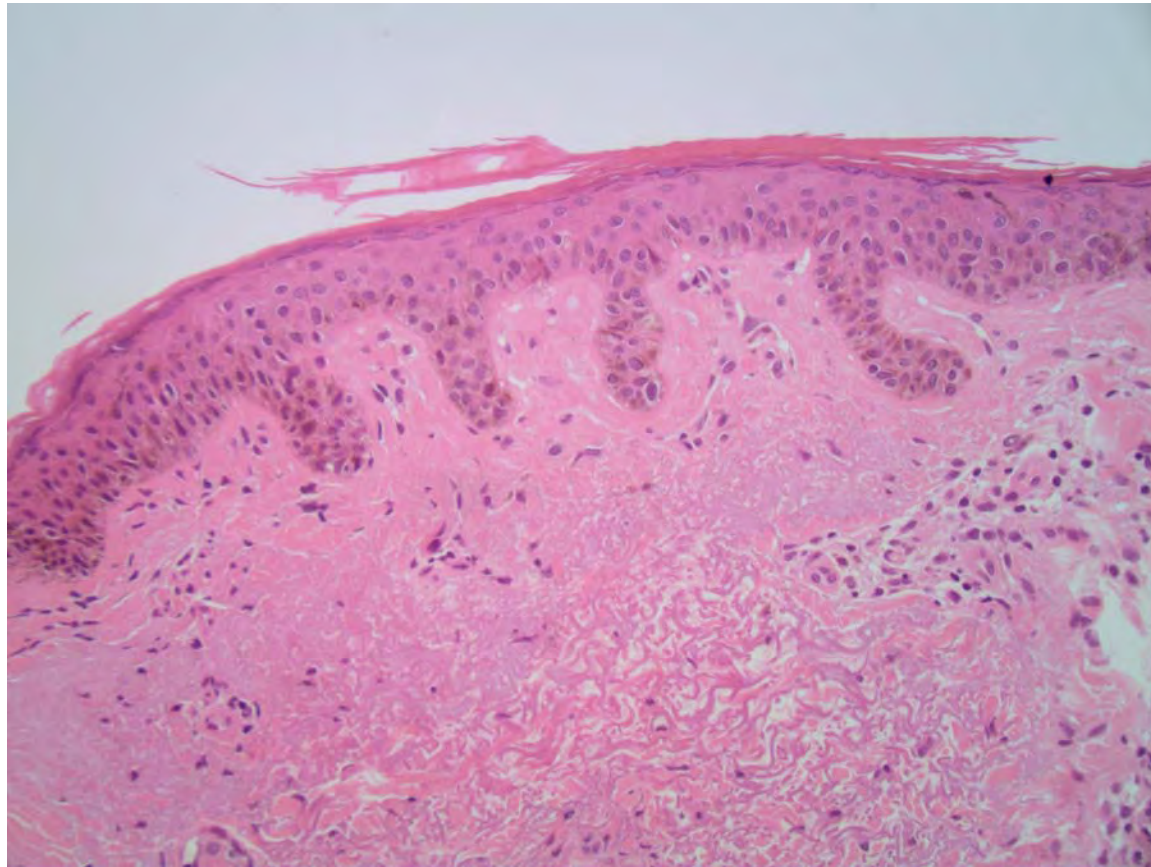
---





# Diagnosis

---

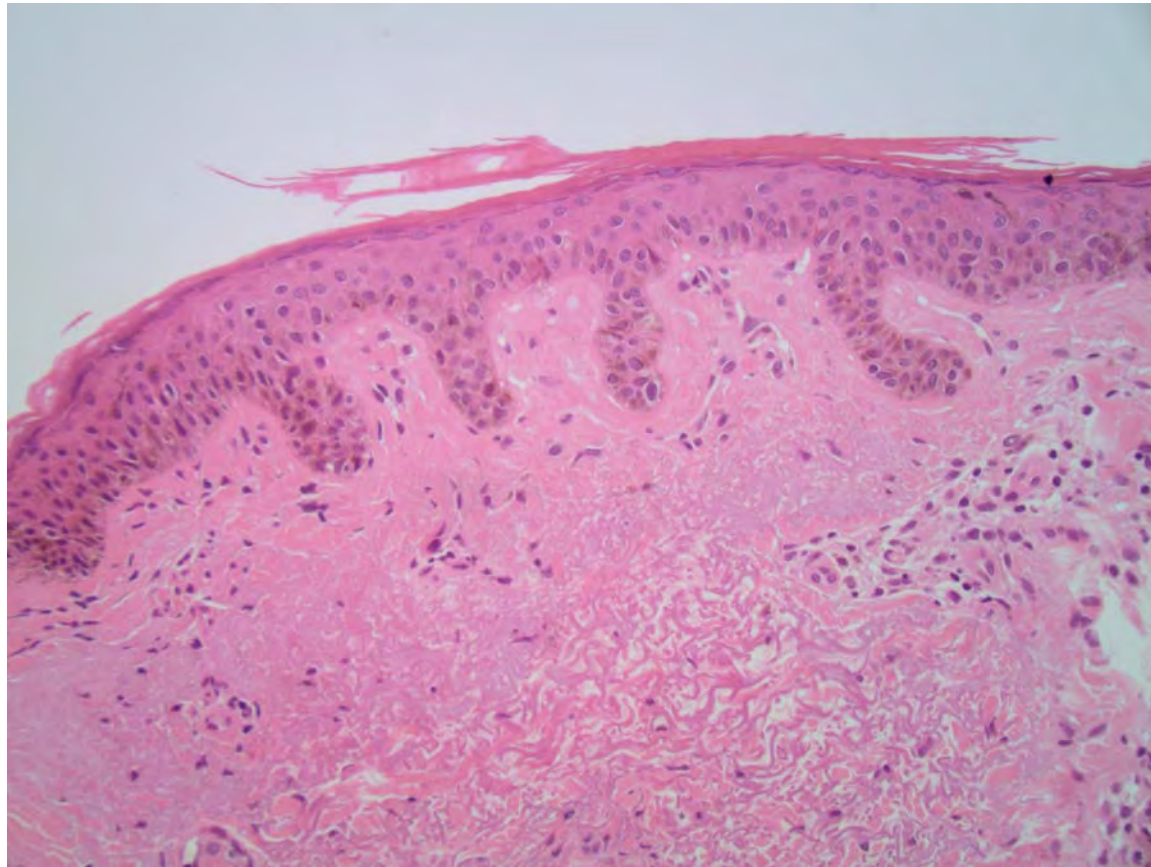




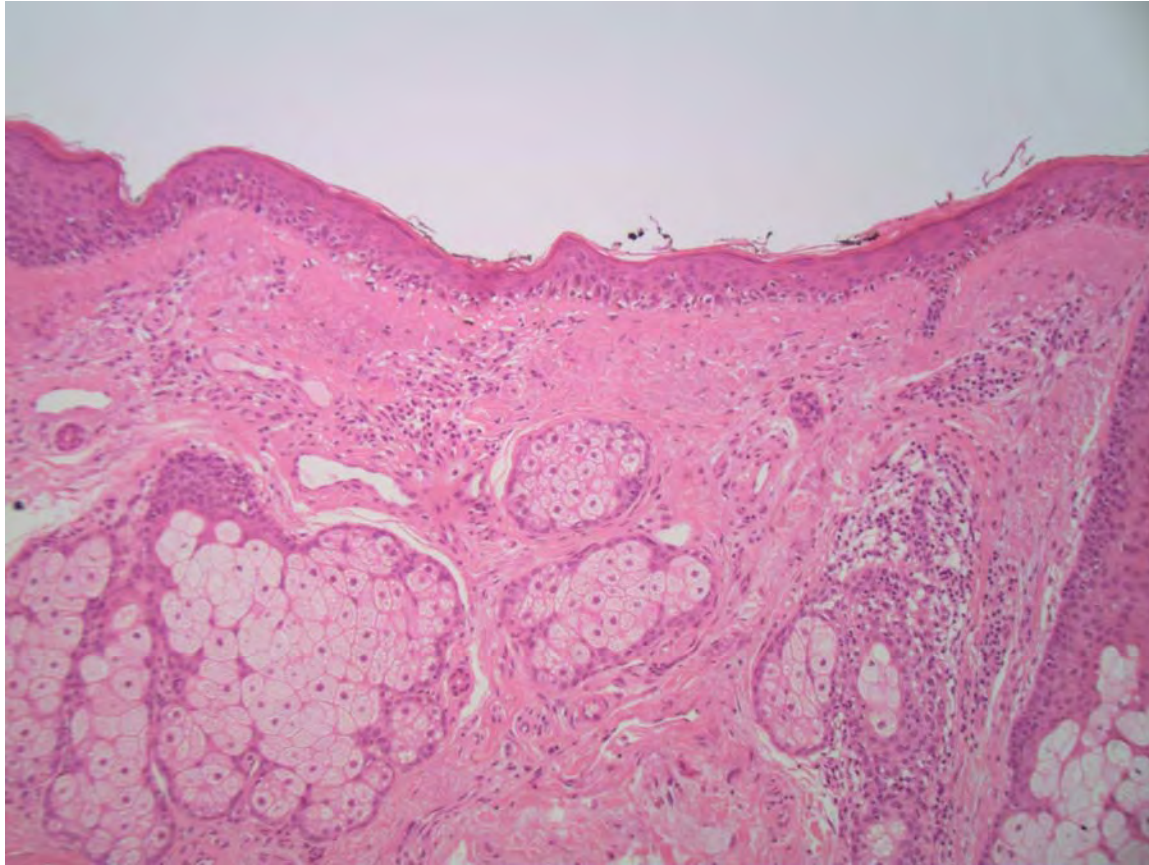


# Solar lentigo

---



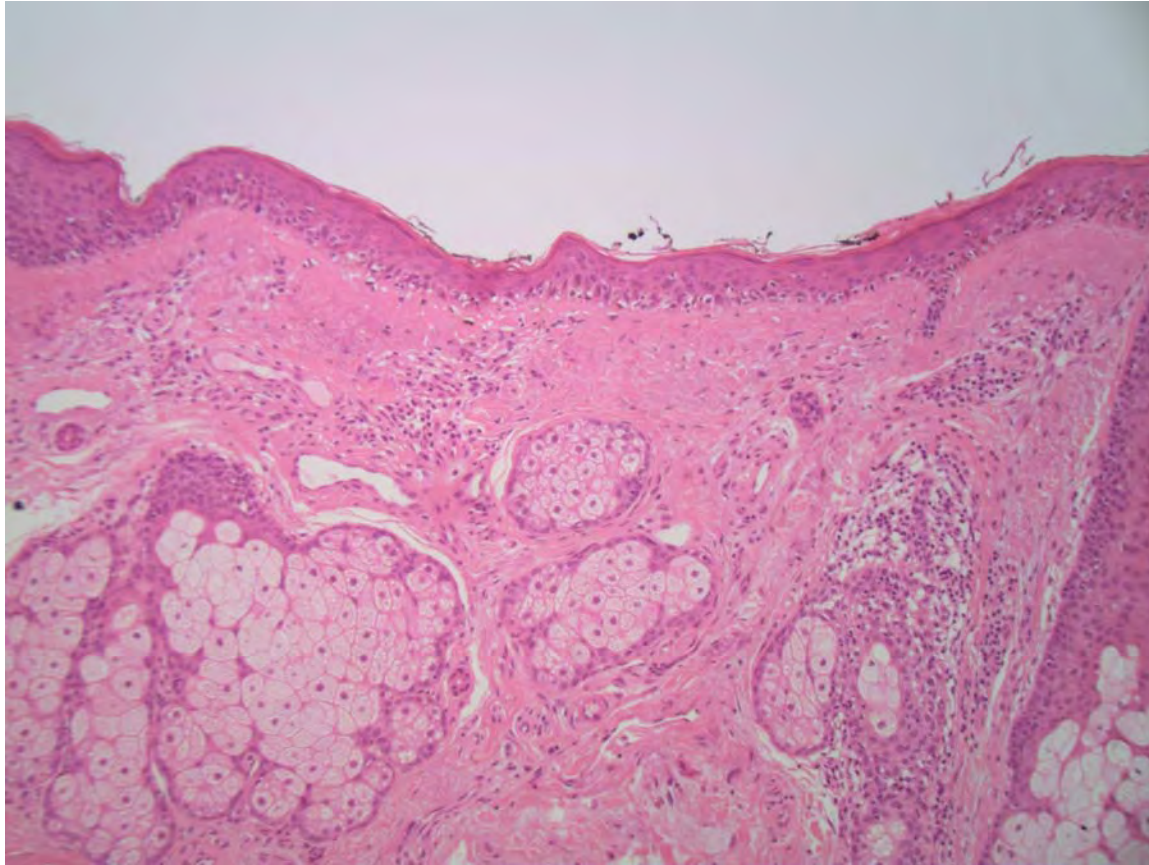
# Diagnosis?



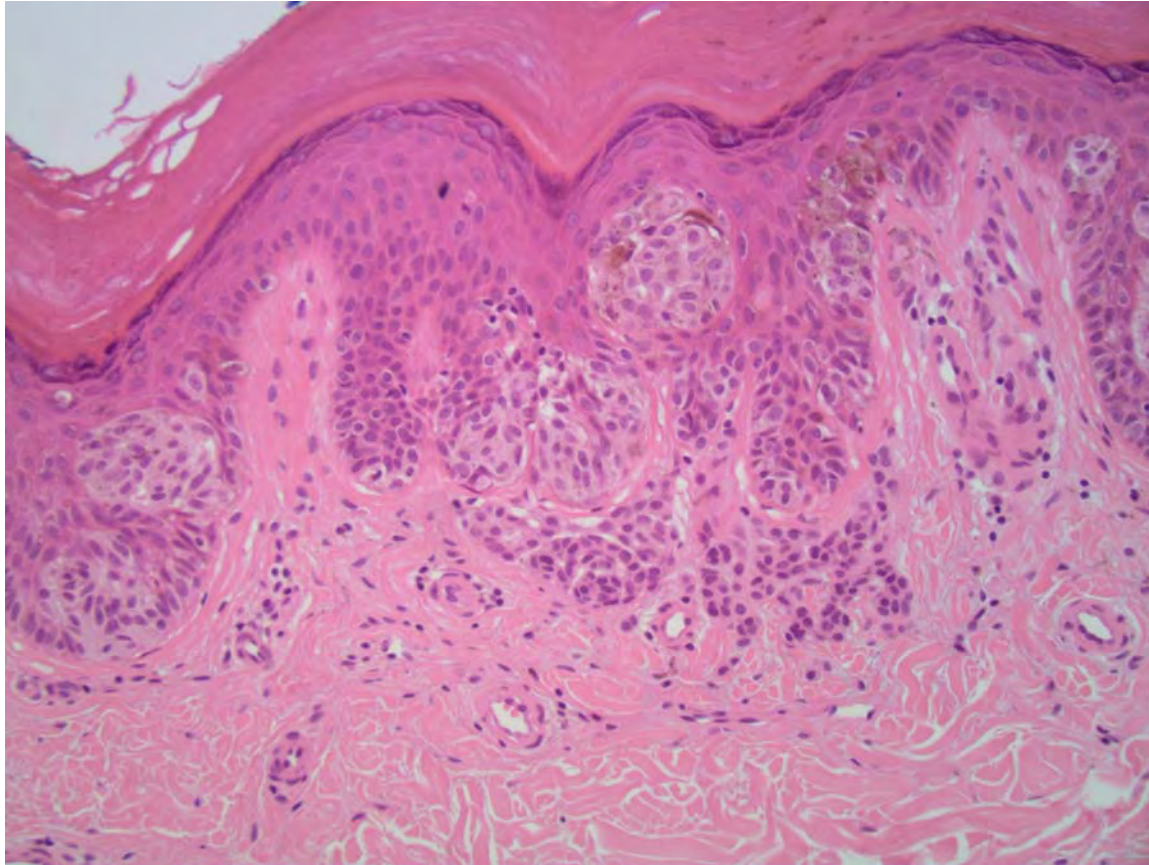


# Lentigo maligna (melanoma in situ)

---



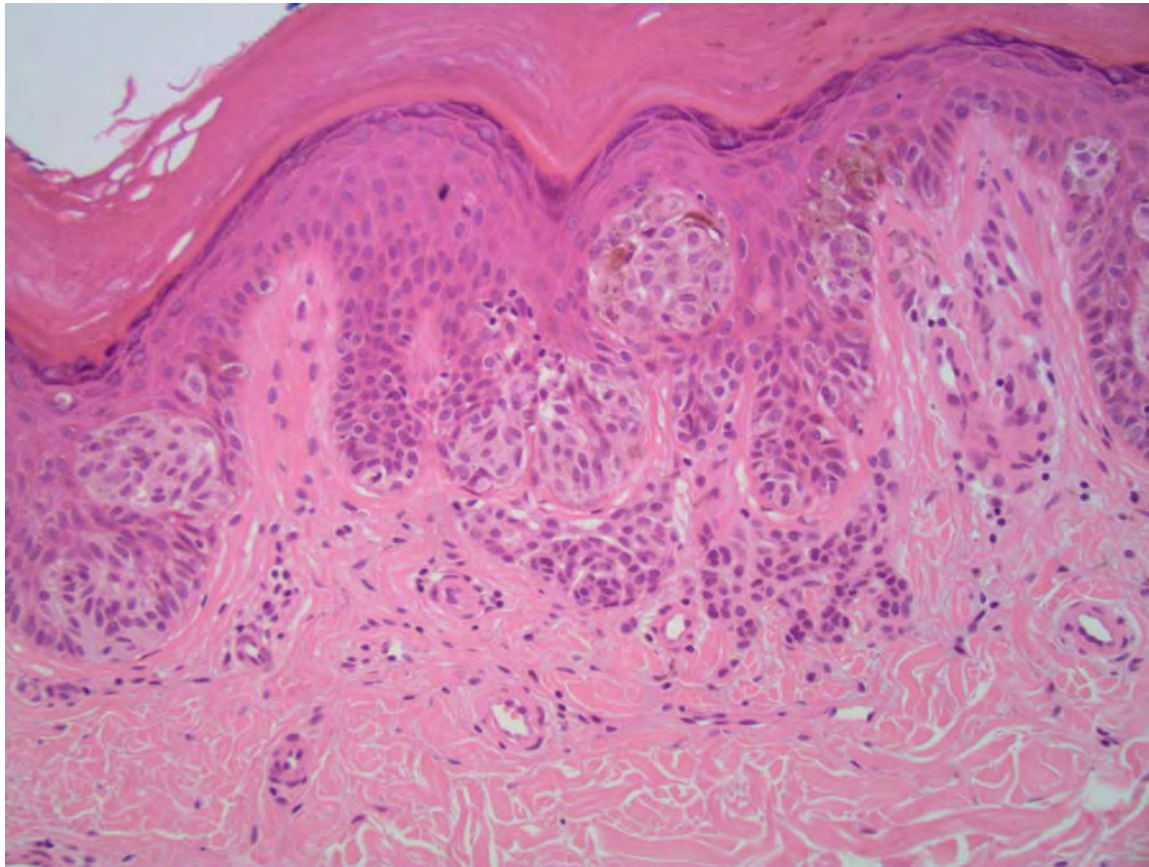
# Diagnosis?



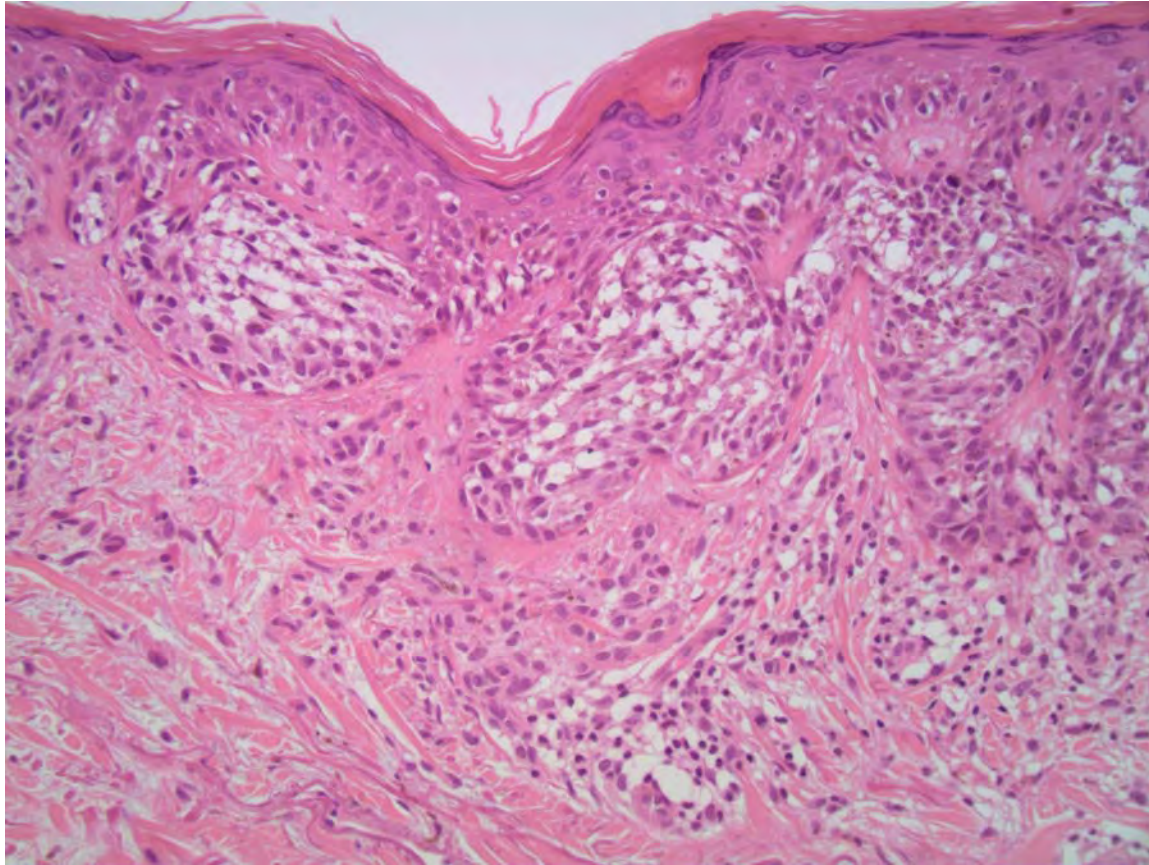


# Compound naevus

---



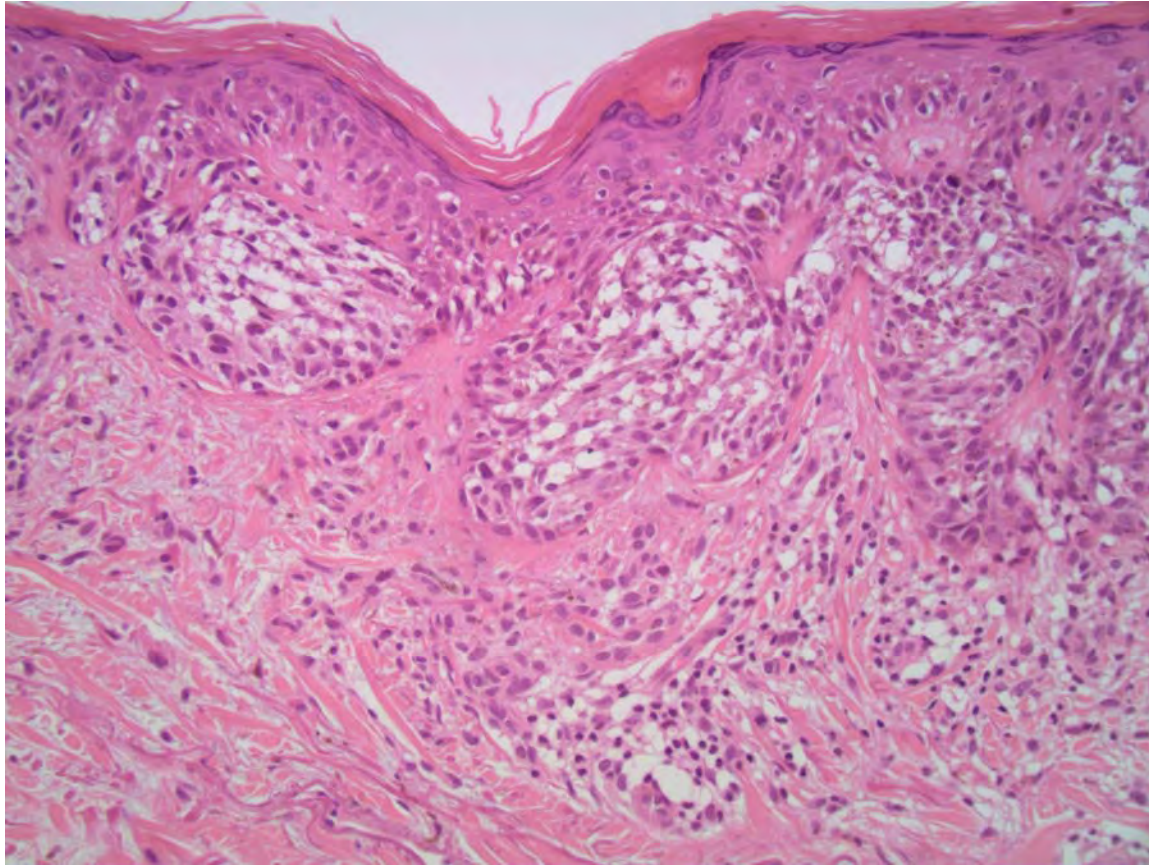
# Diagnosis?





# Level 2 superficial spreading melanoma

---





# Diagnosis?

---







# European mole

---



[www.naturfoto.cz](http://www.naturfoto.cz)

© Jiri Bohdal



MELBOURNE PATHOLOGY

*"We take it personally"*

# Thank you

